

# An improved method of supercharged transposed latissimus dorsi flap with the skin paddle for the management of a complicated lumbosacral defect

E. CIGNA<sup>1,2</sup>, S. MARDINI<sup>1</sup>, H.-C. CHEN<sup>1</sup>, Ö. ÖZKAN<sup>1</sup>, P. SASSU<sup>1</sup>, C.J. SALGADO<sup>1</sup>, Y.-T. LIEU<sup>1</sup>, I. PONZO<sup>2</sup>, D. RIBUFFO<sup>2</sup>, N. SCUDERI<sup>2</sup>

<sup>1</sup>Department of Plastic Surgery, and the E-Da Hospital/I-Shou University, Taiwan

<sup>2</sup>Department of Plastic and Reconstructive and Aesthetic Surgery, Polyclinic Umberto I, Sapienza University of Rome, Rome, Italy

**Abstract.** – **OBJECTIVE:** Treatment of non-healing wounds of lower back often poses a powerful challenge. We present one of the first report of treatment of a lumbosacral defect with a supercharged latissimus dorsi flap with the skin paddle.

**CASE REPORT:** We report a case of a 59 year-old man with myeloma of the sacral spine who underwent radiotherapy and chemotherapy and subsequently, laminectomies and placement of hardware for ongoing paresis and spine instability. Then, he developed an open wound and osteomyelitis of the spine with culture positive tuberculous granulomas. After multiple surgical debridement, he presented to our service and was treated with a single stage debridement followed by the performance of a latissimus dorsi musculocutaneous flap based on paraspinous perforators and supercharged.

**RESULTS:** This solution, allowed for augmentation of blood flow to the muscle with the inferior gluteal artery, provided coverage of the defect resistant to the pressure, and simplified post-operative management of the patient.

**CONCLUSIONS:** Alternative treatment options, including free tissue transfer, posed difficulties in finding suitable recipient vessels near the defect, in inserting the flap so as to restore its original length without compromising blood flow, and in postoperative care of the patient. Treatment of a lumbosacral defect with a supercharged latissimus dorsi flap with the skin paddle may represent a milestone procedure for complicated lower spine wounds.

*Key Words:*

Latissimus dorsi flap, Microsurgery, Supercharged flap, Lower back defect, Sacral defect, Pedicled flap, Musculocutaneous flap.

## Introduction

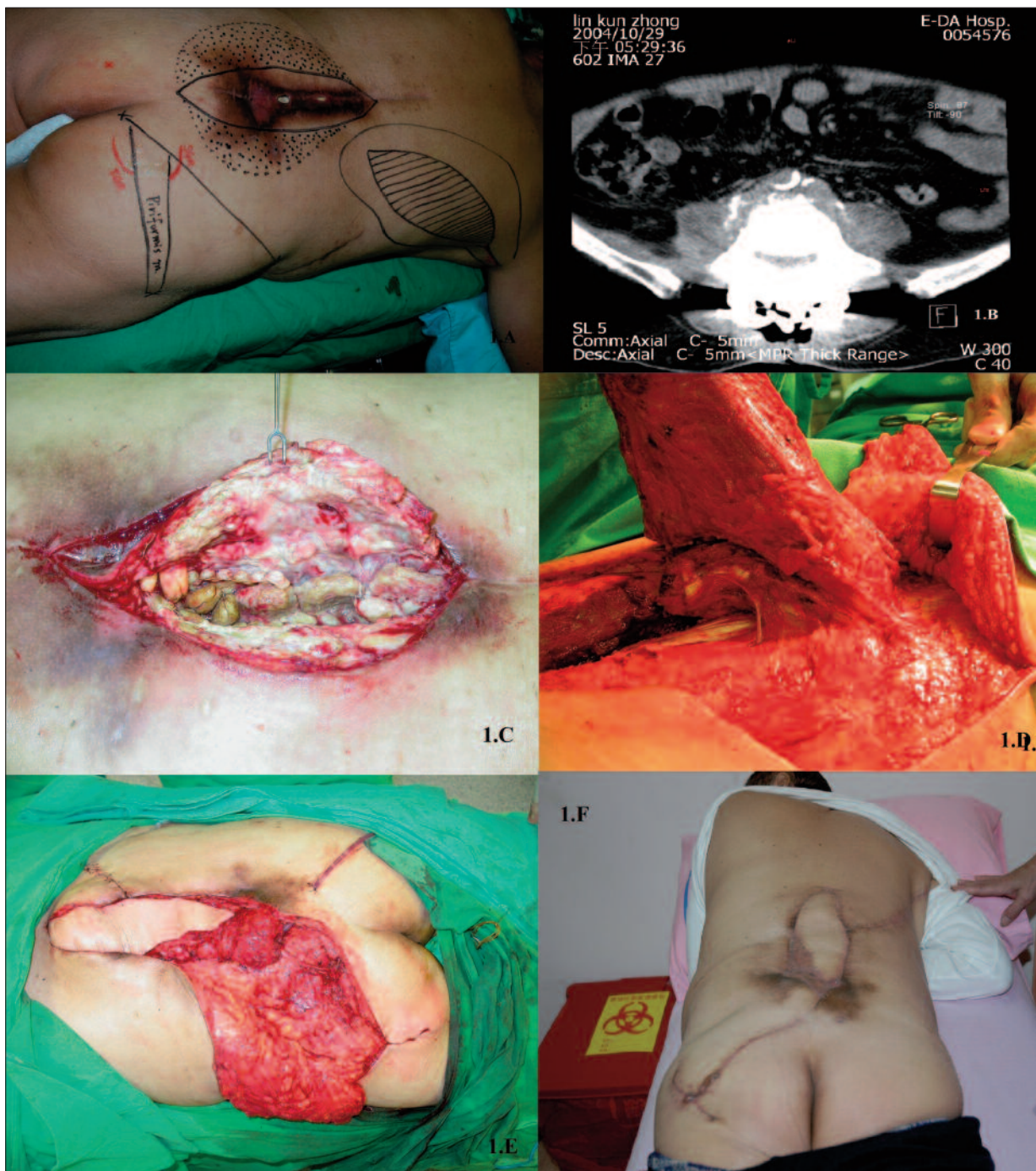
Chronic osteomyelitis of the spine with open wounds of lower back present a reconstructive challenge. A variety of flaps can be used to repair defects in this area, ranging from local cutaneous, muscle and musculocutaneous flaps or perforator flaps to free flaps<sup>1-6</sup>.

Nevertheless, surgical therapy often fails due to the lack of adequate debridement, provision of soft tissue coverage with inadequate blood supply, and to imperfect postoperative management of the patient. This is particularly true in patients with compromised conditions related to local or systemic factors such as radiation therapy, infection, and compromised immune system.

Following the failure of multiple surgical procedures to treat a lower back wound with chronic osteomyelitis, we successfully treated a patient using a latissimus dorsi flap with a large skin paddle that was supercharged in order to optimize blood flow.

## Case Report (Figure 1)

A 59-year-old man with a history of multiple myeloma of the sacral spine surgically treated, resulting in osteomyelitis of the spine and chronic wound, presented to our service after multiple failed attempts at wound debridement and closure. (Figure 1 A) For the initial treatment of the myeloma, the patient received radiotherapy. However, patient's symptoms of lower back pain and progressive lower extremity pareses persisted. A decompressive laminectomy of L2 through L5 was performed. The patient subsequently de-



**Figure 1.** A 59 year-old man with a lumbosacral defect. **1A**, Preoperative view of the wound and markings of the musculocutaneous latissimus dorsi flap. The skin fistulas are marked with arrows. The dotted area shows what is expected to be the extent of the wound under the skin. The parallel lines mark the skin island that was harvested with the flap. **1B**, Computerized Tomography demonstrating the extensiveness of the defect, its depth as well as a fistula connecting the spine to the skin (white arrow). **1C**, After incising an elliptical area of skin. Note the extent of the wound under the skin, the exposed spinous processes, and the antibiotic beads (cephalad: right side of figure). **1D**, The reverse latissimus dorsi musculocutaneous flap after harvest and before clockwise rotation into the defect. Arrows A, B, C, and D point to the thoracodorsal vessels following ligation, the exposed dura following resection of the infected spinous processes, the exposed hardware, and the inferior gluteal vessels respectively. **1E**, The flap after complete disinsertion. Two paraspinous perforators are visualized (arrows). Note that the tissue in between these vessels, which might include additional paraspinous perforators, was preserved. **1F**, The wound on postoperative day 26 demonstrating complete healing.

veloped instability of the spine and infection of the lower back with positive culture of *Mycobacterium tuberculosis* granulomas. The instability was surgically treated by transpedicle screw fixation from T12 to S1. At that time, antibiotic beads were placed in the wound bed.

The patient presented to our service with fever and continuous drainage of the wound. A preoperative CT scan (Figure 1B) showed a large paraspinal defect with apparent skin fistulas and involvement of lumbar and sacral spinous processes. Intravenous antibiotic therapy was administered and then an extensive debridement of the wound, removal of the spinous processes that were exposed (performed by neurosurgeons) and removal of the beads were performed. The defect was then filled with a latissimus dorsi flap (Figure 1C, 1D, 1E, and 1F).

### Operative Procedure

Marking of the skin island was performed medial to and along the axis of the latissimus dorsi muscle and it measured 23 × 11 cm (Figure 1A.) A two team approach was used: one team elevated the right latissimus myocutaneous flap, in the standard fashion, while the other team exposed the left inferior gluteal vessels (Figure 1D). After exposure and dissection of the pedicle of the flap, the thoracodorsal artery and the vein were ligated and the muscle was detached from its insertion on the humerus and its origins along the iliac bone and the spine. The flap was then latero-medial elevated. Care was taken to preserve paraspinal perforators, whenever possible. It was rotated clockwise into the defect and the dissection was stopped when adequate mobilization was achieved. We were able to visualize at least two large perforating vessels and we preserved all tissues in, between these vessels (Figures 1D, 1E). After rotating the flap approximately 100 degrees clockwise into the defect, the muscle insertion was placed into the most distal aspect of the wound and the rest of the muscle was used to fill the wound. The flap vessels were anastomized to the inferior gluteal artery and vein. In order to avoid any undue tension, a small area over the distal aspect of the muscle was skin grafted. Suction drainages were placed under the muscle, away from the pedicle; the wound was closed, and the patient was transported to the microsurgical intensive care unit (ICU) in a prone position. It is remarkable that during the dissection, the tissues appeared to be indurated in a way consistent with radiation injury.

### Postoperative Course

The patient was monitored in the microsurgical intensive care unit in a prone position for 5 days before being transferred to the ward. Monitoring of the skin island with doppler checks of the pedicle of the flap was performed. The patient was allowed to lay in a prone as well as right lateral decubitus position for the first 10 days, then he was allowed to lay on the left lateral decubitus position as well, for the following ten days. At postoperative day 20, he was allowed to lay in a supine position and begin ambulating. Intra-operative specimens did not show any evidence of *Mycobacterium tuberculosis* infection or malignancy. A whole body scan with Tc 99-m MDP was performed at post operative day 20 and was read as negative for osteomyelitis. The patient was discharged on postoperative day 26 ambulating but in unstable health conditions (Figures 1F). At month 4 follow-up, the patient demonstrated complete healing of the wound without any evidence of superficial or deep wound infections.

### Discussion

Small to medium size defects of the lumbosacral region can usually be closed using local cutaneous, muscle or musculocutaneous flaps<sup>5-8</sup>. Large defects however require special management due to the size of the defect and the lack of adequate amount of adjacent tissue to the wound that is particularly true when the patient has received preoperative radiation therapy or presents with an infected wound. Bone exposure and hardware represent an even greater challenge and require extensive debridement and provision of well vascularized tissue useful in filling the dead space, providing white blood cells and other immune factors to reach the wound, and in allowing antibiotics to reach critical areas of the wound in high enough concentrations. Regional and distant flaps such as the latissimus dorsi muscle flap in this case, are often used, as they fulfil criteria required for management of such wounds<sup>9</sup>. These flaps also have the advantage of not being immediately adjacent to the wound and are therefore not subjected to inflammatory processes and infectious organisms present in the wound<sup>10</sup>.

Ideally, a local or regional muscle flap such as the gluteus maximus flap<sup>2,11-13</sup> can be used for the reconstruction. Nevertheless, in our case, the location of the wound was slightly too cephalad

and too large in size and volume and these muscles had also been more directly exposed to the damaging effects of radiation, making them even less viable for transfer. In instances when local flaps are inadequate or have been already used, other regional and distant free flaps are the only available option for wound closure. When dealing with large defects of the lower back, reverse and “turnover” latissimus dorsi flaps based on the secondary segmental vessels have been reported<sup>14-15</sup>. These flaps have been performed with and without reperfusion of the main pedicle of the flap by the “supercharging” method<sup>16</sup>. Only a few reports have discussed microsurgical free flap methods for the reconstruction of lower back wound<sup>16-19</sup>; anyway, when free tissue transfer is opted for, the latissimus dorsi flap based on the thoracodorsal vessels, is the most commonly used flap. This method of reconstruction, although often successful, becomes a significant challenge when the coverage of a lumbosacral wound is required. Two are the main reasons of the increased difficulties: first of all, the paucity of suitable recipient vessels and second, the complexity of postoperative care. Although supercharging a flap does require the use of recipient vessels in the area of the affected region, they do not provide the sole blood supply to the flap. Therefore, the chance of complete flap failure is lessened. Additionally, if occlusion of the supercharged vessels is detected during the postoperative period, exploration and repair can be performed without undergoing any significant ischemia or venous congestion of the flap, by ensuring a dual blood supply. The absence of ideally positioned and sized recipient vessels for microsurgical free tissue transfer, often leads surgeons to use less commonly used vessels (i.e., perforator vessels of the deep femoral system<sup>20</sup>, the deep femoral artery<sup>17,21</sup>, the inferior<sup>22-24</sup> or superior<sup>16,19,22,25-27</sup> gluteal vessels, the superficial femoral trunk<sup>28</sup> and the intercostals vessels). Some authors performed staged transfers of the flap using carrier vessels<sup>22,30</sup>, and others used more distant vessels bridged with long vein grafts<sup>31-35</sup> in which an increased risk of thrombosis was observed. In our case, we used the left superior gluteal artery to allow a more comfortable two team approach. Although the vessels appeared to have suffered radiation damages (evident induration and lack of a good plane of dissection around the vessels), the presence of a strong spurt upon transecting the artery encouraged us to use this vessel.

Reconstruction of lower back wounds requires proper postoperative care, such as important as adequate preoperative planning and surgical execution. When free tissue transfer is performed, correct positioning of the patient must avoid any compression of the pedicle. Flap circulation has to be carefully monitored, especially during the early postoperative period. Despite all precautions, flap failure may occur and often results in further trouble in these complex kind of patients. Thus, many surgeons opt for conservative methods of wound closure, or attempt primary closure or local flap closure, which often ends up in reconstructive failures and persistent osteomyelitis. Our patient required immediate reconstruction with viable, well vascularized tissue in order to eradicate the osteomyelitis, protect the spinal contents (which were exposed following the debridement) and allow a relatively rapid return to ambulation. A free latissimus dorsi flap was our routine method to achieve this type of outcome<sup>17,21</sup>. However, in this case we opted for transposing the latissimus dorsi flap with the skin paddle based on the paraspinal perforators, then to perform microvascular anastomoses of the thoracodorsal vessels to the inferior gluteal vessels in order to enhance the blood flow and augment venous return of the flap. The usual bulge that occurs at the rotation/pivot point was minimized by complete disinsertion of the origin of the muscle along the spine. In order to obtain wound coverage with well vascularized tissue with adequate bulk without worrying about an all or none flap failure phenomenon, we attempted harvest of a latissimus dorsi musculocutaneous flap based on its secondary blood supply. The flap could be placed into the defect with adequate blood flow for flap survival from paraspinal perforators and additional blood flow could be obtained by supercharging the flap using the thoracodorsal vessels. Before performing the microsurgical anastomosis, the flap was inset into the defect and was placed under some tension in order to re-gain the same length of muscle as was present before dis-insertion. This is difficult to reach when the flap is performed as a free flap only, because tension could compress the pedicle and compromise flap perfusion. We often loose at least 20 or 30 percent of flap length when performing closure of back wounds with free flaps due to this phenomenon. By having a dual blood supply and a skin island, there is a higher chance of achieving a successful result, and postoperative monitoring becomes easier. The skin island

provides a good way for monitoring flap perfusion. Additionally, the skin provides coverage of this large defect that would otherwise require skin grafting. The skin island over the muscle may also shunt any interruption to venous outflow from certain parts of the muscle in case of temporary occlusion of one of the venous pedicles that could happen in the normal supine position. The presence of intramuscular valves could therefore be bypassed through the skin island whenever this temporary pressure occurs. In selected cases of lower back wounds where the area of rotation of the flap allows wound coverage along with preservation of the secondary blood supply to the latissimus dorsi musculocutaneous flap, this approach assure excellent flap perfusion, decrease in the likelihood of complete flap failure, simplified postoperative care and monitoring, the ability to regain the original flap length during the inset and provision of adequate skin for wound coverage without the need for large skin grafts.

### Conclusions

This case is the first report of a successfully supercharged musculocutaneous latissimus dorsi flap used for coverage of a lower back defect.

### Statement of Interest

Each Author certifies that he or she has no commercial associations that might pose a conflict of interest in connection with the submitted article.

### References

- 1) McCRAW JB, PENIX JO, BAKER JW. Repair of major defects of the chest wall and spine with the latissimus dorsi myocutaneous flap. *Plast Reconstr Surg* 1978; 62: 197-206.
- 2) HILL HL, BROWN RG, JURKIEWICZ MJ. The transverse lumbosacral back flap. *Plast Reconstr Surg* 1978; 62: 177-184.
- 3) HILL C, RIAZ M. A new twist to the myocutaneous turnover flap for closure of a spinal defect. *Plast Reconstr Surg* 1998; 102: 1167-1170.
- 4) KATO H, HASEGAWA M, TAKADA T, TORII S. The lumbar artery perforator based island flap: Anatomical study and case reports. *Br J Plast Surg* 1999; 52: 541-546.
- 5) KROLL SS, ROSENFELD L. Perforator-based flaps for low posterior midline defects. *Plast Reconstr Surg* 1988; 81: 561-566.
- 6) KOSHIMA I, MORIGUCHI T, SOEDA S, KAWATA S, OHTA S, IKEDA A. The gluteal perforator-based flap for repair of sacral pressure sores. *Plast. Reconstr Surg* 1993; 91: 678-683.
- 7) YANAI A, BANDOY Y, TSUZUKI K. Bilateral gluteal thigh flaps for closure of large defects in the lumbosacral region and perineal region. *Plast Reconstr Surg* 1991; 88: 703-706.
- 8) KOMURO Y, TAKATO T, UEDA K, HARRI K. Experience with U-shaped gluteal thigh flap for reconstruction of radionecrosis in the sacral region. *Ann Plast Surg* 1993; 31: 475-478.
- 9) VESELY J, HYZA P, RANNO R, CIGNA E, MONNI N, STUPKA I, JUSTAN I, DVORAK Z, NOVAK P, RANNO S. New technique of total phalloplasty with reinnervated latissimus dorsi myocutaneous free flap in female-to-male transsexuals. *Ann Plast Surg* 2007; 58: 544-550.
- 10) OZKAN O, CHEN HC, MARDINI S, CIGNA E, HAO SP, HUNG KF, CHEN HS. Microvascular free tissue transfer in patients with hematological disorders. *Plast Reconstr Surg* 2006; 118: 936-944.
- 11) PARKASH S, BANERJEE S-N. Gluteus maximus myocutaneous flap cover for sacral radiation ulcers. *Aust N Z J Surg* 1986; 56: 481-484.
- 12) STEVENSON TR, POLLOCK RA, ROHRICH RJ, VANDERKOLK CA. The gluteus maximus musculocutaneous island flap: refinements in design and application. *Plast Reconstr Surg* 1987; 79: 761-768.
- 13) AY A, AYTEKIN O, AYTEKIN A. Interdigitating fasciocutaneous gluteal V-Y advancement flaps for reconstruction of sacral defects. *Ann Plast Surg* 2003; 50: 636-638.
- 14) BOSTWICK J 3RD, SCHEFLAN M, NAHAI F, JURKIEWICZ MJ. The "reverse" latissimus dorsi muscle and musculocutaneous flap: anatomical and clinical considerations. *Plast Reconstr Surg* 1980; 65: 395-399.
- 15) STEVENSON TR, ROHRICH RJ, POLLOCK RA, DINGMAN RO, BOSTWICK J 3RD. More experience with the "reverse" latissimus dorsi musculocutaneous flap: precise location of blood supply. *Plast Reconstr Surg* 1984; 74: 237-243.
- 16) GIESSWEIN P, CONSTANCE CG, MACKAY DR, MANDERS EK. Supercharged latissimus dorsi muscle flap for coverage of the problem wound in the lower back. *Plast Reconstr Surg* 1994; 94: 1060-1063.
- 17) HUNG SJ, CHEN HC, WEI FC. Free flaps for reconstruction of the lower back and sacral area. *Microsurgery* 2000; 20: 72-76.
- 18) MILES WK, CHANG DW, KROLL SS, MILLER MJ, LANGSTEIN HN, REECE GP, EVANS GR, ROBB GL. Reconstruction of large sacral defects following total sacrectomy. *Plast Reconstr Surg* 2000; 105: 2387-2394.
- 19) DI BENEDETTO G, BERTANI A, PALLUA N. The free latissimus dorsi flap revisited: a primary option for coverage of wide recurrent lumbosacral defects. *Plast Reconstr Surg* 2002; 109: 1960-1965.
- 20) CHEN HC, WENG CJ, NOORDHOFF MS. Coverage of multiple extensive pressure sores with a single flapped lower leg myocutaneous free flap. *Plast Reconstr Surg* 1986; 78: 396-398.

- 21) CHEN HC, CHEN HH, CHEN WJ, TANG YB. Chronic osteomyelitis of the spine managed with a free flap of latissimus dorsi. A case report. *Spine* 1996; 21: 2016-2018.
- 22) HARRIS GD, LEWIS VL, NAGLE DJ, EDELSON RJ, KIM PS. Free flap reconstruction of the lower back and posterior pelvis: indications, principles, and techniques. *J Reconstr Microsurg* 1988; 4: 169-178.
- 23) ANTHONY JP, RITTER E, MOELLEKEN BR. Utility of the inferior gluteal vessels in free flap coverage of sacral wounds. *Ann Plast Surg* 1992; 29: 371-375.
- 24) DANIEL RK, KERRIGAN CL, GARD DA. The great potential of the intercostal flap for torso reconstruction. *Plast Reconstr Surg* 1978; 61: 653-665.
- 25) STARK D, TOFIELD JJ, TERRANOVA W, HURLEY D, KENNEY J. The latissimus dorsi free flap for coverage of sacral radiodermatitis in the ambulatory patient. *Ann Plast Surg* 1987; 19: 80-83.
- 26) PARK S, KOH KS. Superior gluteal vessel as recipient for free flap reconstruction of lumbosacral defect. *Plast Reconstr Surg* 1998; 101: 1842-1849.
- 27) GOLDBERG JA, BARWICK WJ, LEVIN LS. Restoration of sensation in paraplegia by a sensory innervated plantar fillet free flap. Case report. *Paraplegia* 1995; 33: 116-119.
- 28) YAMAMOTO Y, NOHIRA K, SHINTOMI Y, IGAWA H, OHURA T. Reconstruction of recurrent pressure sores using free flaps. *J Reconstr Microsurg* 1992; 8: 433-446.
- 29) TAVIN E, SERLETTI JM. Case Report: the intercostals vessels as recipients for a free latissimus dorsi flap to a lumbosacral wound. *Plastic Surgery Forum* 1996; 19: 335-336.
- 30) ZHU SX, CHANG BX, LU SB. Free transfer of latissimus dorsi myocutaneous flap using wrist vessels as carriers for the treatment of lumbosacral scar contracture deformity. *Eur J Plast Surg* 1987; 9: 167-175.
- 31) SALIBIAN AH, TESORO VR, WOOD DL. Staged transfer of a free microvascular latissimus dorsi myocutaneous flap using saphenous vein grafts. *Plast Reconstr Surg* 1983; 71: 543-547.
- 32) NAHAI F, HAGERTY R. One-stage microvascular transfer of a latissimus flap to the sacrum using vein grafts. *Plast Reconstr Surg* 1986; 77: 312-315.
- 33) FUDEM GM, MARBLE KR. Latissimus dorsi free flap for sacral wound closure: the world's longest vein grafts for free tissue transfer. *Microsurgery* 1996; 17: 449-451.
- 34) KHOURI RK. Avoiding free flap failure. *Clin Plast Surg* 1992; 19: 773-781.
- 35) SANTANELLI F, RUBINO C, INNOCENZI D, RIBUFFO D, SCUDERI N. Free flap failure in a patient with a long standing, infected, squamous cell carcinoma. *Scand J Plast Reconstr Surg Hand Surg* 1994; 28: 305-308.
- 36) CORMACK GC, LAMBERTY BGH. The arterial anatomy of skin flaps. 2<sup>nd</sup> ed. Churchill Livingstone, 1994.
- 37) MATHES SJ, NAHAI F. *Reconstructive Surgery: Principles, Anatomy, and Technique*. London: Churchill Livingstone, 1997.