

Comparison between ultrasound-guided pericapsular nerve group block and anterior quadratus lumborum block for total hip arthroplasty: a double-blind, randomized controlled trial

Q.-R. WANG¹, T. MA², J. HU³, J. YANG³, P.-D. KANG¹

¹Department of Orthopedic Surgery, West China Hospital, Sichuan University, Chengdu, China

²Operating Room, West China Hospital, Sichuan University/West China School of Nursing, Sichuan University, Chengdu, China

³Department of Anesthesiology, West China Hospital, Sichuan University, Chengdu, China

Q.-R. Wang and T. Ma contributed equally to this work and should be regarded as first co-authors

Abstract. – OBJECTIVE: Peripheral nerve block can provide effective postoperative analgesia to patients undergoing total hip arthroplasty (THA). This study aimed to compare ultrasound-guided pericapsular nerve group (PENG) block against anterior quadratus lumborum (AQL) block for pain management in primary THA.

PATIENTS AND METHODS: In this prospective, double-blind, randomized controlled trial, 90 patients undergoing primary THA under general anesthesia were randomly allocated to receive ultrasound-guided PENG block + sham AQL block (“PENG group”) or ultrasound-guided AQL block + sham PENG block (“AQL” group). The primary outcome was the highest pain score on a visual analogue scale while the patient was in the recovery room. Secondary outcomes included pain scores after transfer out of the recovery room, morphine consumption, quadriceps strength, duration of hospitalization, pain level one year after surgery, and incidence of complications.

RESULTS: Patients in the PENG group reported significantly lower maximum pain scores in the recovery room (31.3 ± 9.1 vs. 37.3 ± 7.4 , $p=0.001$), as well as significantly lower pain scores at rest at 3 h after surgery and during motion at 3 and 6 h after surgery. The two groups did not differ significantly in postoperative morphine consumption, length of hospitalization, pain level at one year after surgery, or incidence of complications. Neither block significantly weakened the quadriceps.

CONCLUSIONS: PENG block may provide slightly more effective postoperative analgesia than AQL block during the early recovery period after primary THA.

Key Words:

Total hip arthroplasty, Pain, Pericapsular nerve group block, Quadratus lumborum block, Regional analgesia.

Introduction

Effective perioperative analgesia during and after total hip arthroplasty (THA) can accelerate early postoperative mobilization and discharge¹⁻³. Such analgesia can be provided by peripheral nerve blocks, which can improve pain relief, reduce opioid requirement, and reduce the time until first mobilization and the time in hospital⁴⁻⁶. However, not all peripheral nerve blocks may be equally effective. For example, femoral nerve block and fascia iliaca block can weaken the quadriceps⁷⁻⁹.

An alternative to these blocks may be the quadratus lumborum block, which has proven effective in lower abdominal surgery¹⁰, and in particular anterior quadratus lumborum (AQL) block, which may provide the broadest block of all quadratus lumborum blocks¹¹. In several studies¹²⁻¹⁵ with patients undergoing THA, AQL block provided strong postoperative analgesia without causing motor block.

Another peripheral nerve block that may be effective for patients undergoing THA is pericapsular nerve group (PENG) block¹⁶. In patients undergoing hip surgery, PENG block provides analgesia comparable to that of femoral nerve block or suprainguinal fascia iliaca block, without weakening the quadriceps¹⁷⁻¹⁹. Despite these positive findings, the PENG block is not mentioned in recent postoperative pain management guidelines for patients undergoing THA²⁰.

Here we compared the PENG block against the AQL block for safety and efficacy in patients undergoing primary THA in a double-blind, randomized controlled trial.

Corresponding Authors: P.-D. Kang, Ph.D, MD; e-mail: kangpengd@163.com;
J. Yang, Ph.D, MD; e-mail: hxyangjing@qq.com

Patients and Methods

This study was approved by the Clinical Trials and Biomedical Ethics Committee of our institution, and written informed consent was obtained from all subjects participating in the trial. The trial was registered at the Chinese Clinical Trial Registry (Registration number: ChiCTR2100053921).

Patient Recruitment

This study recruited patients undergoing primary unilateral THA via a posterolateral approach at our institution between December 2021 and May 2022. We included patients who were diagnosed with osteoarthritis of the hip, osteonecrosis of the femoral head (Ficat IIIB or IV), or developmental dysplasia of the hip (Crowe I or II). To be enrolled, patients had to have normal quadriceps strength and an American Society of Anesthesiologists (ASA) functional status of I-III. We excluded patients with (1) hip ankylosis, (2) known allergies to the drugs used in this study, (3) opioid addiction or dependence, (4) alcohol addiction or dependence, (5) cognitive impairment, (6) psychiatric illness, (7) recognized neuromuscular disorders, (8) previous open hip surgery, (9) other neuropathic diseases of the hip on the target side, or (10) an inability to communicate verbally.

Randomization

All patients were classified into two groups using a computer-generated list of random numbers (Excel, Microsoft Corporation, Redmond, WA, USA). Based on this list, Investigator 1, who was blinded to group allocation and study design, prepared sealed opaque envelopes. On the morning of surgery, Investigator 1 handed out the envelopes to patients and Investigator 2 assigned them to the PENG or AQL group accordingly. Patients in the PENG group received PENG block + sham AQL block, while patients in the AQL group received AQL block + sham PENG block.

Before surgery, Investigator 2 ensured that the same anesthesiologist prepared the block syringes (containing saline or local anesthetics) in the central pharmacy and performed the appropriate nerve block in the operating room. The outcome assessor (Investigator 3) and surgeon were blinded to treatment group. Statistical analysis was performed by Investigator 4, who was also blinded to group allocation.

Baseline Characteristics of Patients

A total of 151 patients were assessed for eligibility, of whom 26 did not meet the eligibility criteria and another 35 were unwilling to give consent. The remaining 90 patients were randomized into two groups. During postoperative outcome assessments, no patients dropped out of the study (Figure 1). The two

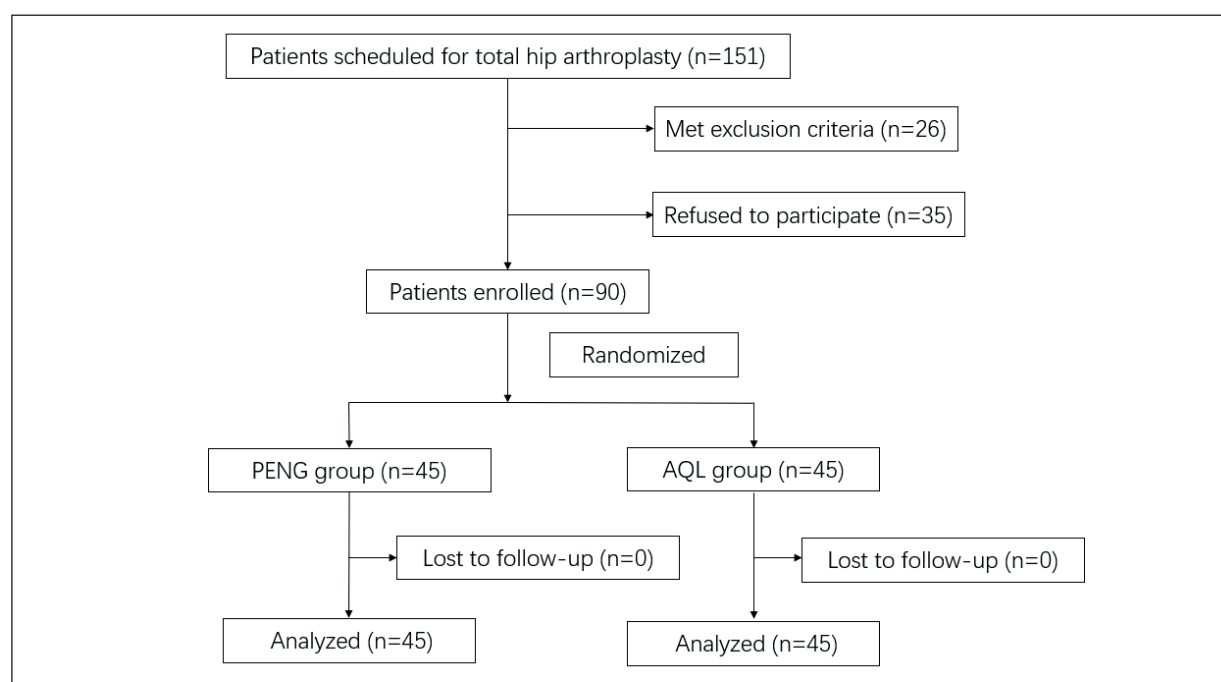


Figure 1. Flow diagram of patients' selection and exclusion.

groups showed no significant differences in characteristics before surgery (Table I).

Perioperative Analgesia and Management

On the day before surgery, oral Celecoxib (200 mg) was administered twice as preemptive analgesia. Nerve blocks were completed 30 min before general anesthesia using ropivacaine and epinephrine or, in the case of sham blocks, an equal volume of isotonic saline.

PENG Block

Patients were placed in the supine position. A low-frequency curvilinear ultrasound transducer (Mindray Anesus ME7; Mindray Bio-Medical Electronics, Shenzhen, China) was placed in a transverse orientation medial and caudal to the anterosuperior iliac spine in order to identify the anteroinferior iliac spine, the iliopubic eminence, and the psoas tendon¹⁶. Using an in-plane technique, the block needle was advanced in a lateral-to-medial direction until the tip was positioned between the periosteum and psoas tendon (Figure 2A-B). Local anesthetic (20 mL of 0.5% ropivacaine containing 1:200,000 epinephrine) was injected slowly in 5 mL increments with intermittent negative aspiration.

AQL Block

Patients were placed in the lateral decubitus position with both legs flexed. The same low-frequency curvilinear ultrasound transducer was placed above the iliac crest, near the L4 vertebral body plane. The block needle was used to slowly inject a local anesthetic (30 mL of 0.33% ropivacaine containing 1:200,000 epinephrine) between the quadratus lumborum and psoas muscles (Figure 2C-D).

Risks of Nerve Blocks and Preventive Actions

The risks of AQL block include toxicity from local anesthetic, infection, and abdominal organ puncture. Compared with AQL block, the puncture site of PENG block is close to the main nerves and blood vessels, thus, it is more likely to cause nerve punctures and vascular punctures in addition to local anesthetic intoxication and infection. Nerve puncture and vascular puncture may further cause nerve damage and bleeding, respectively.

In order to avoid these risks, some preventive actions were carried out: 1. Nerve block was performed by a highly trained and experienced anesthesiologist under ultrasound guidance; 2. Strict disinfection before operation; 3. Limit the dosage of local anesthetic.

THA

All surgical procedures in this study were performed by two senior surgeons. Prior to the trial, the two surgeons were trained to ensure consistent technique. All surgeries were performed through the posterolateral approach under general anesthesia. After pure oxygen inhalation, the following anesthetics were administered intravenously: Midazolam, 2 mg; Propofol, 2 mg/kg; Sufentanil, 0.3 µg/kg; and Cis-atracurium, 0.2 mg/kg. Patients were then intubated and given inhaled anesthetic (Sevoflurane, 1-1.5 MAC). During surgery, Corail or TRI-LOCK stems and Pinnacle cups (DePuy Synthes, New Brunswick, NJ, USA) were used. At 20 min before the end of surgery, flurbiprofen (50 mg) was administered to prevent postoperative pain, along with Tropisetron (5 mg) to prevent postoperative nausea and vomiting.

After surgery, the patients were transferred to the post-anesthesia care unit (PACU) for extubation and full recovery. After awakening from general anesthesia, patients were transferred to

Table I. Baseline characteristics of patients.

Characteristic	PENG group (n=45)	AQL group (n=45)	p
Age (years)	53.3±12.5	54.8±12.7	0.570 ^a
Sex (M/F)	24/21	23/22	0.833 ^b
Weight (kg)	63.6±8.6	65.3±8.3	0.359 ^a
Height (cm)	163.8±7.6	163.5±8.6	0.866 ^a
Body mass index (kg/m ²)	23.6±2.0	24.4±2.0	0.175 ^c
Surgery side (right/left)	25/20	20/25	0.292 ^b
Preoperative measures			
VAS pain score	48.4±8.8	50.2±10.1	0.388 ^a
ASA status (I/II/III)	4/30/11	6/28/11	0.746 ^c

Values are mean ± SD or n, unless otherwise noted. ASA, American Society of Anaesthesiologists; AQL, anterior quadratus lumborum; PENG, pericapsular nerve group; VAS, visual analogue scale. ^a Student's *t*-test; ^b Pearson's Chi-squared test; ^c Mann-Whitney U test.

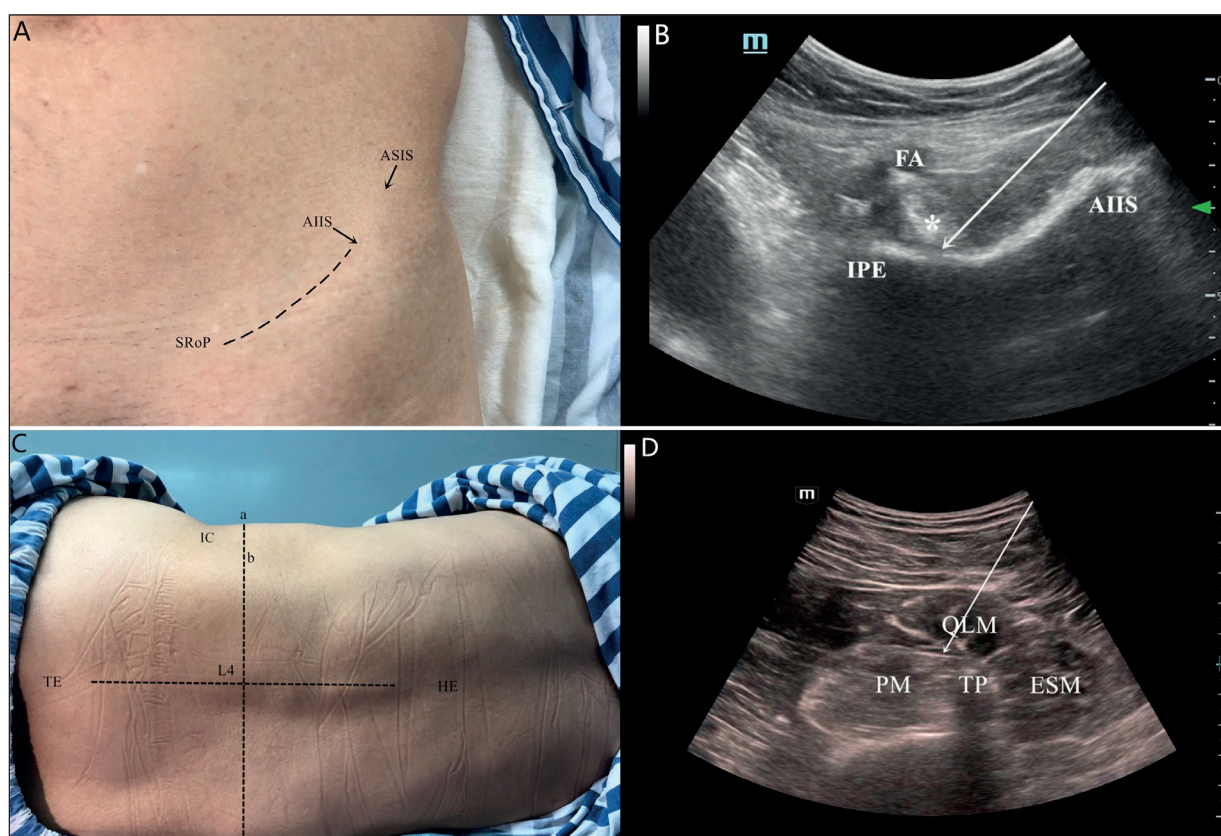


Figure 2. A-B, Ultrasound-guided pericapsular nerve group (PENG) block. **A**, Left hip in supine position. **B**, Ultrasonogram of the PENG block. The needle tip was positioned between the psoas tendon (arrow) and the pubic ramus using an in-plane approach. The arrow indicates the trajectory of the needle. AIIS, anterior inferior iliac spine; ASIS, anterior superior iliac spine; FA, femoral artery; IPE, iliopubic eminence; SRoP, superior ramus of pubis. **C-D**, Ultrasound-guided anterior quadratus lumborum (AQL) block. **C**, Location of administration of the AQL block, where (a) indicates the position of the ultrasound probe, and (b) indicates the position of the puncture. **D**, Ultrasonogram of the AQL block. The arrow indicates the trajectory of the needle. ESM, erector spinae muscle; HE, head end; IC, iliac crest; PM, psoas muscle; QLM, quadratus lumborum muscle; TE, tail end; TP, transverse process.

the bed ward, where an ice compress was applied around the incision. Oral Celecoxib (200 mg) was administered twice daily to control postoperative pain. If the patient was unable to tolerate the pain, rescue analgesia of 10 mg of morphine hydrochloride was injected subcutaneously.

Assessments

In the PACU, the outcome assessor assessed pain until the patient was transferred out of the PACU. A visual analogue scale²¹ was used that ranged from 0 (no pain) to 100 (extreme pain). After being transferred out of the PACU, pain at rest and during motion was measured at 3, 6, 12, 24, and 48 h after surgery. Pain during motion was assessed by asking the patient to flex the hip as much as possible.

Quadricep strength was assessed at 3, 6, 12, 24, and 48 h after surgery while the patient was supine

and flexed the hip at 45° and the knee at 90°. The patient was asked to extend the knee first against gravity and then against resistance. The outcome assessor resisted the knee extension and touched the contracted muscle in the thigh in order to grade the muscle strength at one of the following levels: level 0, no muscle contraction; level 1, muscle contraction but no joint movement; level 2, joint movement but no gravity resistance; level 3, gravity resistance; level 4, gravity resistance and partial counterforce resistance; and level 5, normal joint function. Normal strength was defined with reference to the quadriceps of the contralateral leg. If quadriceps strength was at levels 0-2, the patient was classified as showing quadriceps weakness.

The discharge criteria of patients included: adequate pain control on oral pain medication, independent transfer, and ambulation of at least 200 feet alone.

At one year after surgery, the patients were followed up on pain and the incidence of complications. There are three levels of pain at postoperative one year: 1. No pain; 2. Mild pain that does not affect daily life; 3. Severe pain that interferes with daily life. Postoperative chronic pain was defined as severe pain that interferes with daily life at one year after surgery.

Outcomes

The primary outcome in this study was the highest pain score at rest that the patient reported in the PACU. The secondary outcomes included pain scores after being transferred out of the PACU, postoperative morphine consumption, postoperative quadriceps strength, time until discharge from hospital, pain level at one year after surgery, and incidence of complications. Complications included nausea, vomiting, local anesthetic intoxication, wound complications, infection, abdominal organ puncture, nerve puncture, nerve damage, vascular puncture, bleeding, quadriceps weakness, falls, and postoperative chronic pain.

Statistical Analysis

Sample size was based on power analysis of data from a pilot study involving 26 patients not enrolled in the main study (data not shown), as well as on data reported in a systematic review²² of 570 randomized clinical trials of pain management after THA and total knee arthroplasties. The review reported that the median minimal clinically important difference in pain scores for patients undergoing such procedures was 30%. Based on our pilot study, being able to detect a 30% difference in the highest pain score in the PACU would require at least 44 individuals per group at a two-sided alpha level of 0.05 and power of 90%. Therefore, we decided to include 45 patients in each group.

Statistical analysis was performed using SPSS 26.0 (IBM Corp., Armonk, NY, USA). The normality of data was assessed using histograms and quantile-quantile plots. Continuous data were presented as mean and standard deviation. Categorical data were presented as numbers or percentages. Inter-group differences in normally distributed data were assessed for significance using Student's *t*-test; differences in skewed and ordinal data, using the Mann-Whitney U test; and differences in categorical data, using Pearson's Chi-squared test or Fisher's exact probabilities test. Differences in hospitalization time were analyzed using Kaplan-Meier survival

analysis and assessed for significance using the log-rank test. Differences were considered significant if $p < 0.05$.

Results

Primary Outcome

The highest pain score reported in the PACU was significantly lower in the PENG group (31.3 ± 9.1 vs. 37.3 ± 7.4 , $p = 0.001$).

Secondary Outcomes

Patients in the PENG group had significantly lower pain scores at rest at 3 h after surgery (35.0 ± 6.2 vs. 38.1 ± 7.5 , $p = 0.031$; Figure 3A), as well as significantly lower pain scores during motion at 3 h after surgery (47.5 ± 7.0 vs. 55.0 ± 8.8 , $p < 0.001$) and 6 h after surgery (52.1 ± 8.4 vs. 58.4 ± 8.3 , $p = 0.001$; Figure 3B).

There were no significant differences between the two groups in postoperative morphine consumption during hospitalization or the time to hospital discharge (Table II, Figure 4). The two groups showed similar quadriceps strength at all time points (Table III).

At one year after surgery, the number of patients with no pain, mild pain, and severe pain in PENG group was 38, 6, and 1 case, respectively, while 37, 5, and 3 cases in the AQL group, respectively. There was no significant difference in pain level at one year after surgery ($p = 0.718$).

During hospitalization, the PENG group and AQL group showed similar incidences of nausea ($p = 0.642$), vomiting ($p = 0.535$), and wound complications ($p = 1.000$) (Table IV). At one year after surgery, the two groups showed similar incidences of postoperative chronic pain ($p = 0.609$). After surgery, neither group experienced local anesthetic intoxication, infection, abdominal organ puncture, nerve puncture, nerve damage, vascular puncture, bleeding, quadriceps weakness, or falls.

Discussion

Patients without significant comorbidities typically undergo primary THA on an ambulatory basis or with stays in the hospital for less than 24 h^{6,23,24}. Since peripheral nerve blocks can reduce perioperative opioid consumption and enhance recovery⁶, we compared motor-sparing PENG and AQL blocks, which may be effective for this purpose. We found that both types of block are

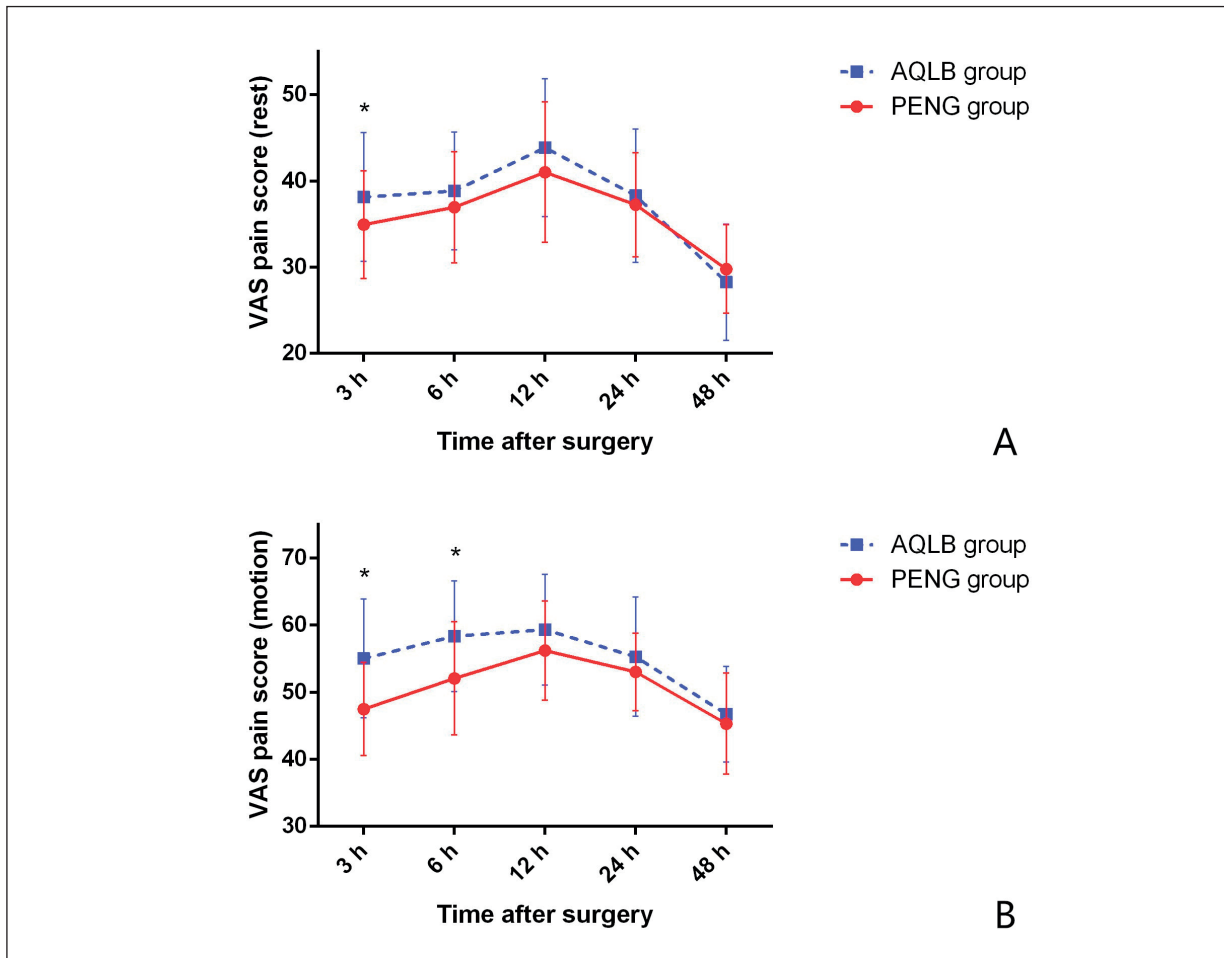


Figure 3. Average postoperative pain scores at rest (A) and during motion (B), based on a visual analogue scale. Error bars indicate standard deviation from the mean. * $p < 0.05$ vs. AQL group.

Table II. Postoperative morphine consumption and hospitalization duration.

Outcome	PENG group (n=45)	AQL group (n=45)	p
Morphine consumption during hospitalization (mg)	6.2±5.8	6.9±6.0	0.608 ^a
Duration of hospitalization (hours)	52.1±13.0	54.4±13.8	0.683 ^b

Values are mean ± SD, unless otherwise noted. AQL, anterior quadratus lumborum; PENG, pericapsular nerve group. ^aMann-Whitney U test; ^bLog-rank test.

Table III. Postoperative quadriceps strength based on 5-level manual assessment*.

Hours after surgery	PENG group (n=45)	AQL group (n=45)	p^a
3	0/0/0/13/26/6	0/0/0/14/25/6	0.859
6	0/0/0/4/34/7	0/0/0/7/30/8	0.711
12	0/0/0/2/32/11	0/0/0/4/32/9	0.433
24	0/0/0/0/22/23	0/0/0/2/25/18	0.214
48	0/0/0/0/5/40	0/0/0/0/8/37	0.371

Values are number of cases in levels 0/1/2/3/4/5, unless otherwise noted. AQL, anterior quadratus lumborum; PENG, pericapsular nerve group. *See Methods for descriptions of the levels. ^aMann-Whitney U test.

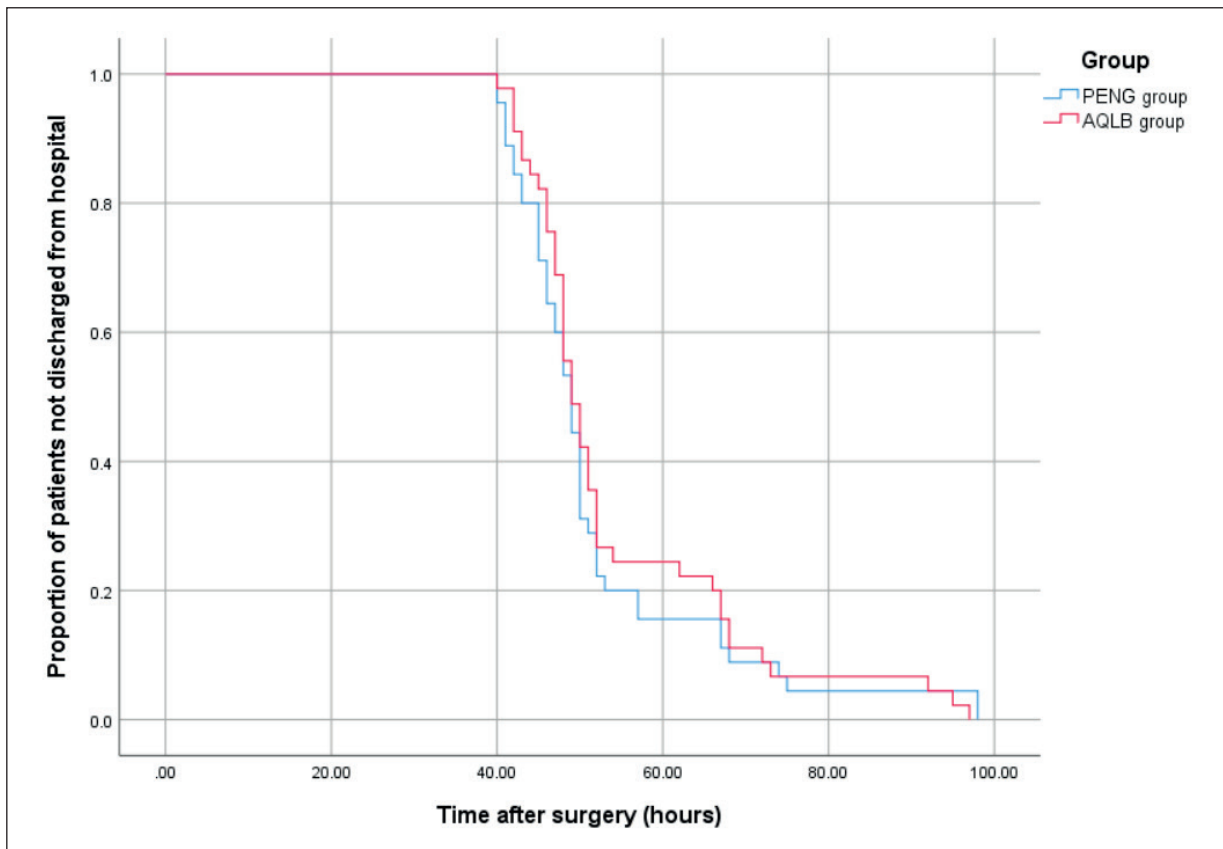


Figure 4. Survival analysis of the duration of hospitalization.

safe and effective, and that the PENG block may provide slightly better postoperative analgesia during the first 6 h after surgery.

The AQL block affects mainly the spinal nerve in the thoracolumbar fascia space²⁵, reducing

the risk of femoral nerve block¹⁵. In contrast, the PENG block affects the articular branches of the femoral, obturator, and accessory obturator nerves, which provide sensory innervation to the anterior hip capsule^{16,26}. Thus, both blocks have proven

Table IV. Postoperative complications.

Complication	PENG group (n=45)	AQL group (n=45)	<i>p</i> ^a
Nausea	12 (26.7)	14 (31.1)	0.642 ^a
Vomiting	7 (15.6)	5 (11.1)	0.535 ^a
Wound complications	3 (6.7)	2 (4.4)	1.000 ^a
Postoperative chronic pain	1 (2.2)	3 (6.7)	0.609 ^a
Local anesthetic intoxication	0 (0)	0 (0)	
Infection	0 (0)	0 (0)	
Abdominal organ puncture	0 (0)	0 (0)	
Nerve puncture	0 (0)	0 (0)	
Nerve damage	0 (0)	0 (0)	
Vascular puncture	0 (0)	0 (0)	
Bleeding	0 (0)	0 (0)	
Quadriceps weakness	0 (0)	0 (0)	
Fall after surgery	0 (0)	0 (0)	

Values are n (%), unless otherwise noted. AQL, anterior quadratus lumborum; PENG, pericapsular nerve group. ^aPearson's Chi-squared test.

to be motor-sparing and effective after THA in many trials^{12-15,18,19}, as well as in the present work. In addition, we provide the first evidence that the PENG block may provide slightly stronger analgesia during the first hours after surgery.

Despite its efficacy in numerous trials, the PENG block provides analgesia to the anterior hip capsule but not to the posterior capsule, which is innervated by nerves from the sacral plexus to the quadratus femoris²⁷. In addition, the PENG block does not provide analgesia for the skin incision, which is innervated by the lateral femoral cutaneous nerve and by lateral cutaneous branches of the iliohypogastric and subcostal nerves^{19,28}. Therefore, postoperative analgesia after THA may be better if the PENG block is combined with local anesthetic infiltration in the posterior capsule and around the incision.

None of the subjects in our trial fell after surgery. Similar results after PENG block or quadratus lumborum block have been reported in several trials^{12-17,29}. This can be attributed, in part, to the ability of both blocks to maintain quadriceps strength. Quadricep weakness hinders early ambulation and increases the risk of postoperative falls^{30,31}. However, in our trial, neither the PENG nor AQL block was completely motor-sparing: at 3 h after surgery, for instance, about 30% of patients in each group experienced some paresis or paralysis during knee extension (level 3). Nevertheless, this proportion dropped to 10-15% by 6 h after surgery. We attribute this motor block to the spread of local anesthetic to the femoral nerve during the PENG block, or to the influence of local anesthetic on the femoral nerve during the AQL block. To spare motor function even more, the dose of local anesthetic in both types of peripheral nerve block should be optimized. Indeed, future studies should optimize the local anesthetic agent and total local anesthetic dose/volume in PENG and AQL blocks, since these parameters have varied widely in published trials^{13-15,17-19,29,32-34}. Periarticular local anesthetic infiltration should also be explored in combination with these blocks.

Prior to the study, we evaluated the potential risks of AQL block and PENG block. In order to avoid related risks, a series of preventive actions were carried out. As reported in previous studies^{35,36}, with precise operation and limited local anesthetic dosage, there are almost no related complications. Current clinical evidence indicates that both nerve blocks are safe techniques.

Limitations

While the present work is the first randomized controlled trial that compares PENG and AQL blocks for postoperative analgesia following THA, the results should be interpreted with caution in light of several limitations. First, manual testing may not detect subtle changes in muscle strength, so future work could use instruments such as an isokinetic dynamometer^{29,37}. Second, our study included only THA conducted via the posterolateral approach, which is nevertheless the most common surgical approach worldwide³⁸. Third, all surgeries in this study were performed by two surgeons so that the results may have been confounded by differences in surgical technique. Fourth, all nerve blocks were performed by one senior anesthesiologist, masking the fact that nerve blocks can strongly depend on the clinician. Our findings should be verified in studies involving multiple surgeons and anesthesiologists. Because of these limitations, further studies are still needed to determine whether PENG block is superior to AQL block.

Conclusions

The PENG block can show similar safety and efficacy as the well-established AQL block for patients undergoing THA. In fact, the PENG block may even show greater analgesic efficacy, at least in the first several hours after the procedure.

Conflict of Interest

The Authors declare that they have no conflict of interests.

Ethics Approval

This study was approved by the Clinical Trials and Biomedical Ethics Committee of Sichuan University West China Hospital. The trial was registered at the Chinese Clinical Trial Registry (Registration number: ChiCTR2100053921).

Funding

This study was funded by 1.3.5 Project of Sichuan University West China Hospital, grant no. ZYJC18040.

Informed Consent

Written informed consent was obtained from all participants.

ORCID ID

J.Y.: 0000-0002-6833-8863

P.K.: 0000-0002-7042-6731.

References

- 1) Tasso F, Simili V, Di Matteo B, Monteleone G, Martorelli F, De Angelis A, D'Amato T, Bovio M, Altomare D, Campofreda G, Marcacci M, Scardino M. A rapid recovery protocol for hip and knee replacement surgery: a report of the outcomes in a referral center. *Eur Rev Med Pharmacol Sci* 2022; 26: 3648-3655.
- 2) Zhou SC, Liu BG, Wang ZH. Efficacy of liposomal bupivacaine vs. traditional anaesthetic infiltration for pain management in total hip arthroplasty: a systematic review and meta-analysis. *Eur Rev Med Pharmacol Sci* 2020; 24: 11305-11314.
- 3) Li FL, Li BC, Huang X, Liu WH, Huang WW, Yin D. Different dexamethasone doses in the perioperative period improve short-term outcomes of total hip arthroplasty: a randomized controlled trial. *Eur Rev Med Pharmacol Sci* 2023; 27: 3438-3447.
- 4) Joshi GP, Schug SA, Kehlet H. Procedure-specific pain management and outcome strategies. *Best Pract Res Clin Anaesthesiol* 2014; 28: 191-201.
- 5) Chou R, Gordon DB, de Leon-Casasola OA, Rosenberg JM, Bickler S, Brennan T, Carter T, Cassidy CL, Chittenden EH, Degenhardt E, Griffith S, Manworren R, McCarberg B, Montgomery R, Murphy J, Perkal MF, Suresh S, Sluka K, Strassels S, Thirlby R, Viscusi E, Walco GA, Warner L, Weisman SJ, Wu CL. Management of postoperative pain: a clinical practice guideline from the american pain society, the american society of regional anesthesia and pain medicine, and the american society of anesthesiologists' committee on regional anesthesia, executive committee, and administrative council. *J Pain* 2016; 17: 131-157.
- 6) Guay J, Rosenblatt MA. Peripheral nerve blocks for elective primary total hip arthroplasty: Have we yet found the optimal solution? *J Clin Anesth* 2020; 67: 109964.
- 7) Kolaczko JG, Knapik DM, Salata MJ. Peri-operative pain management in hip arthroscopy: a systematic review of the literature. *J Hip Preserv Surg* 2019;6:353-363.
- 8) Gasanova I, Alexander JC, Estrera K, Wells J, Sunna M, Minhajuddin A, Joshi GP. Ultrasound-Guided suprainguinal fascia iliaca compartment block versus periarticular infiltration for pain management after total hip arthroplasty: a randomized controlled trial. *Reg Anesth Pain Med* 2019; 44: 206-211.
- 9) Behrends M, Yap EN, Zhang AL, Kolodzie K, Kinjo S, Harbell MW, Aleshi P. Preoperative fascia iliaca block does not improve analgesia after arthroscopic hip surgery, but causes quadriceps muscles weakness: a randomized, double-blind trial. *Anesthesiology* 2018; 129: 536-543.
- 10) Albrecht E, Chin KJ. Advances in regional anaesthesia and acute pain management: a narrative review. *Anaesthesia* 2020; 75: e101-110.
- 11) Ueshima H, Otake H, Lin JA. Ultrasound-Guided Quadratus Lumborum Block: An Updated Review of Anatomy and Techniques. *Biomed Res Int* 2017; 2017: 1-7.
- 12) Ueshima H, Otake H. Ultrasound-guided supra-iliac anterior quadratus lumborum block provides effective perioperative analgesia for total hip arthroplasty. *J Clin Anesth* 2020; 59: 2.
- 13) He J, Zhang L, He WY, Li DL, Zheng XQ, Liu QX, Wang HB. Ultrasound-Guided Transmuscular Quadratus Lumborum Block Reduces Postoperative Pain Intensity in Patients Undergoing Total Hip Arthroplasty: A Randomized, Double-Blind, Placebo-Controlled Trial. *Pain Res Manag* 2020; 2020: 1-8.
- 14) Abdullaha MA, Ahmed SA, Abdelghany MS. The effect of post-operative ultrasound-guided transmuscular quadratus lumborum block on postoperative analgesia after hip arthroplasty in elderly patients: A randomised controlled double-blind study. *Indian J Anaesth* 2020; 64: 887-893.
- 15) Hu J, Wang Q, Zeng Y, Xu M, Gong J, Yang J. The impact of ultrasound-guided transmuscular quadratus lumborum block combined with local infiltration analgesia for arthroplasty on postoperative pain relief. *J Clin Anesth* 2021; 73: 110372.
- 16) Girón-Arango L, Peng PWH, Chin KJ, Brull R, Perlas A. Pericapsular nerve group (PENG) block for hip fracture. *Reg Anesth Pain Med* 2018; 43: 1-63.
- 17) Lin DY, Morrison C, Brown B, Saies AA, Pawar R, Vermeulen M, Anderson SR, Lee TS, Doornberg J, Kroon HM, Jaarsma RL. Pericapsular nerve group (PENG) block provides improved short-term analgesia compared with the femoral nerve block in hip fracture surgery: a single-center double-blinded randomized comparative trial. *Reg Anesth Pain Med* 2021; 46: 398-403.
- 18) Aliste J, Layera S, Bravo D, Jara Á, Muñoz G, Barrientos C, Wulf R, Brañez J, Finlayson RJ, Tran Q. Randomized comparison between pericapsular nerve group (PENG) block and suprainguinal fascia iliaca block for total hip arthroplasty. *Reg Anesth Pain Med* 2021; 46: 874-878.
- 19) Pascarella G, Costa F, Del Buono R, Pulitanò R, Strumia A, Piliego C, De Quattro E, Cataldo R, Agrò FE, Carassiti M. Impact of the pericapsular nerve group (PENG) block on postoperative analgesia and functional recovery following total hip arthroplasty: a randomised, observer-masked, controlled trial. *Anaesthesia* 2021; 76: 1492-1498.
- 20) Anger M, Valovska T, Beloeil H, Lirk P, Joshi GP, Van de Velde M, Raeder J. PROSPECT guideline for total hip arthroplasty: a systematic review and procedure-specific postoperative pain management recommendations. *Anaesthesia* 2021; 76: 1082-1097.
- 21) Hawker GA, Mian S, Kendzerska T, French M. Measures of adult pain: Visual Analog Scale for Pain (VAS Pain), Numeric Rating Scale for Pain (NRS Pain), McGill Pain Questionnaire (MPQ), Short-Form McGill Pain Questionnaire (SF-MPQ), Chronic Pain Grade Scale (CPGS), Short Form-36 Bodily Pain Scale (SF-36 BPS), and

- Measure of Intermittent and Constant Osteoarthritis Pain (ICOAP). *Arthritis Care Res (Hoboken)* 2011; 63: S240-252.
- 22) Laigaard J, Pedersen C, Rønsbo TN, Mathiesen O, Karlsen APH. Minimal clinically important differences in randomised clinical trials on pain management after total hip and knee arthroplasty: a systematic review. *Br J Anaesth* 2021; 126: 1029-1037.
- 23) Ilfeld BM, Gearen PF, Enneking FK, Berry LF, Spadoni EH, George SZ, Vandenborne K. Total hip arthroplasty as an overnight-stay procedure using an ambulatory continuous psoas compartment nerve block: a prospective feasibility study. *Reg Anesth Pain Med* 2006; 31: 113-118.
- 24) Nelson SJ, Webb ML, Lukasiewicz AM, Varthi AG, Samuel AM, Grauer JN. Is Outpatient Total Hip Arthroplasty Safe? *J Arthroplasty* 2017; 32: 1439-1442.
- 25) Sá M, Cardoso JM, Reis H, Esteves M, Sampaio J, Gouveia I, Carballada P, Pinheiro C, Machado D. Quadratus lumborum block :are we aware of its side effects? A report of 2 cases. *Braz J Anesthesiol* 2018; 68: 396-399.
- 26) Del Buono R, Padua E, Pascarella G, Costa F, Tognù A, Terranova G, Greco F, Fajardo Perez M, Barbara E. Pericapsular Nerve Group (PENG) block: an overview. *Minerva Anesthesiol* 2021; 87: 458-466.
- 27) Birnbaum K, Prescher A, Hessler S, Heller KD. The sensory innervation of the hip joint—an anatomical study. *Surg Radiol Anat* 1997; 19: 371-375.
- 28) Nielsen MV, Nielsen TD, Bendtsen TF, Børglum J. The Shamrock sign: comprehending the trefoil may refine block execution. *Minerva Anesthesiol* 2018; 84: 1423-1425.
- 29) Zheng J, Pan D, Zheng B, Ruan X. Preoperative pericapsular nerve group (PENG) block for total hip arthroplasty: a randomized, placebo-controlled trial. *Reg Anesth Pain Med* 2022; 47: 155-160.
- 30) Johnson RL, Kopp SL, Hebl JR, Erwin PJ, Mantilla CB. Falls and major orthopaedic surgery with peripheral nerve blockade: a systematic review and meta-analysis. *Br J Anaesth* 2013; 110: 518-528.
- 31) Kronzer VL, Wildes TM, Stark SL, Avidan MS. Review of perioperative falls. *Br J Anaesth* 2016; 117: 720-732.
- 32) Kukreja P, MacBeth L, Sturdivant A, Morgan CJ, Ghanem E, Kalagara H, Chan VWS. Anterior quadratus lumborum block analgesia for total hip arthroplasty: a randomized, controlled study. *Reg Anesth Pain Med* 2019; 25: rapm-2019-100804.
- 33) Stuart Green M, Ryan Hoffman C, Iqbal U, Olabisi Ives O, Hurd B. Transmuscular Quadratus Lumborum Block Reduces Length of Stay in Patients Receiving Total Hip Arthroplasty. *Anesth Pain Med* 2018; 8: e80233.
- 34) Nassar H, Hasanin A, Sewilam M, Ahmed H, Abo-Elsoud M, Taalab O, Rady A, Zoheir HA. Transmuscular Quadratus Lumborum Block versus Suprainguinal Fascia Iliaca Block for Hip Arthroplasty: A Randomized, Controlled Pilot Study. *Local Reg Anesth* 2021; 14: 67-74.
- 35) Wang Q, Hu J, Zhang W, Zeng Y, Yang J, Kang P. Comparison Between Ultrasound-Guided Suprainguinal Fascia Iliaca Block and Anterior Quadratus Lumborum Block for Total Hip Arthroplasty: A Prospective, Double-Blind, Randomized Controlled Trial. *J Arthroplasty* 2022; 37: 763-769.
- 36) Hu J, Wang Q, Hu J, Kang P, Yang J. Efficacy of Ultrasound-Guided Pericapsular Nerve Group (PENG) Block Combined With Local Infiltration Analgesia on Postoperative Pain After Total Hip Arthroplasty: A Prospective, Double-Blind, Randomized Controlled Trial. *J Arthroplasty* 2023; 38: 1096-1103.
- 37) Berner C, Erlacher L, Quittan M, Fenzl KH, Dorner TE. Workability and Muscle Strength in Patients With Seropositive Rheumatoid Arthritis: Survey Study Protocol. *JMIR Res Protoc* 2017; 6: e36.
- 38) Moretti VM, Post ZD. Surgical approaches for total hip arthroplasty. *Indian J Orthop* 2017; 51: 368-376.