

# Diagnostic efficacy of lung ultrasound in cardiogenic pulmonary edema: a systematic review and meta-analysis

L.-J. DONG<sup>1</sup>, J. LI<sup>1</sup>, W. LIU<sup>1</sup>, A.-W. ANKAERJIANG<sup>2</sup>, B. LI<sup>2</sup>, Y.-T. CHEN<sup>2</sup>, Z.-X. YU<sup>1</sup>

<sup>1</sup>Department of Critical Care Medicine, The First Affiliated Hospital of Xinjiang Medical University, Urumqi, China

<sup>2</sup>The First Affiliated Hospital, Xinjiang Medical University, Urumqi, China

**Abstract. – OBJECTIVE:** This meta-analysis was performed to evaluate the diagnostic efficacy of lung ultrasound (LUS) in cardiogenic pulmonary edema.

**MATERIALS AND METHODS:** An electronic search of databases, including MEDLINE, Embase, PubMed, and Web of Science, was performed to collect clinical studies on ultrasound diagnosis of cardiogenic pulmonary edema from inception to 23 March 2023. The number of patients with true-positive, true-negative, false-positive, and false-negative cardiogenic pulmonary edema diagnosed by LUS was collected, and the R package was used to analyze the diagnostic efficacy of LUS.

**RESULTS:** Nine pieces of literature were finally included with 2,097 participants, including 1,047 patients with cardiogenic heart failure. Across the nine included papers, the pooled sensitivity of LUS in the included studies was 0.92 (95% CI: 0.84, 0.97) with a maximum sensitivity of 0.99 (95% CI: 0.96 to 1.00) and a minimum of 0.59 (95% CI: 0.50, 0.68). The pooled specificity of the included studies was 0.87 (95% CI: 0.82, 0.91) with a maximum specificity of 0.93 (95% CI: 0.90-0.95) and a minimum of 0.80 (95% CI: 0.67, 0.89). The pooled AUC was 0.93 (95% CI: 0.84 to 0.97), suggesting a high diagnostic value of LUS in cardiogenic pulmonary edema.

**CONCLUSIONS:** Lung ultrasound offers a good diagnostic efficacy for cardiogenic pulmonary edema. Further standardization of the examination method is required to provide a reference for the clinical use of LUS.

*Key Words:*

Lung ultrasound, Heart failure, Cardiogenic pulmonary edema, Diagnostic efficacy.

## Introduction

Heart failure (HF) is a group of syndromes caused by various structural or functional heart

diseases that lead to impaired ventricular filling and/or ejection capacity, with a global prevalence of 1-2% in adults. Its common symptoms include dyspnea, cough, or exercise intolerance<sup>1</sup>. Acute decompensated heart failure (ADHF) is one of the leading causes of respiratory distress in adults and the most common cause of death in patients with acute respiratory distress<sup>2</sup>. Acute heart failure is clinically manifested by pulmonary stasis/pulmonary edema, stasis of body circulation, low cardiac output, and hypoperfusion of tissues and organs, which can be complicated by acute respiratory failure and cardiogenic shock in severe cases<sup>3</sup>. Pulmonary edema is a common sign of heart failure and is characterized by severe dyspnea resulting from a rapid accumulation of fluid in the interstitial and/or alveolar spaces of the lungs due to a dramatic increase in cardiac filling pressures<sup>4</sup>. Signs and symptoms of non-cardiogenic diseases, such as infections and acute respiratory distress syndrome, are similar to those of HF and may lead to misdiagnosis and inappropriate treatment<sup>5</sup>.

Chest radiography, physical examination, and brain-type natriuretic peptide are available diagnostic modalities for acute decompensated heart failure, but their low sensitivity may lead to delayed diagnosis and increased morbidity and mortality. Lung ultrasound (LUS) is a noninvasive and reproducible technique suitable for use in emergency and intensive care units (ICU) settings<sup>6</sup>. In recent years, LUS has been extensively adopted as a secondary diagnostic method for the diagnosis of lung diseases<sup>5</sup>. LUS is a noninvasive instrument used to differentially diagnose a variety of lung pathologies with comparable or even higher diagnostic efficacy than other diagnostic methods, such as chest radiography<sup>5</sup>. In general, ultrasound B lines visible on LUS correlate with

extravascular lung water content, which is potentially valuable in the diagnosis of ADHF. However, clinical outcomes vary among studies. To this end, this meta-analysis was performed to evaluate the diagnostic efficacy of lung ultrasound in cardiogenic pulmonary edema.

## Materials and Methods

### Search Strategy

Based on the PRISMA guidelines, an electronic search of databases, including MEDLINE, Embase, PubMed, and Web of Science, was performed to collect clinical studies on ultrasound diagnosis of cardiogenic pulmonary edema from inception to 23 March 2023, with the language restriction to English. The search was conducted using the following words, “pulmonary edema” or “wet lungs”, and “ultrasound”, “sonography”, or “sonogram”.

### Inclusion and Exclusion Criteria

Inclusion criteria: (1) diagnostic studies, cohort and case-control studies; (2) studies that assess the diagnostic accuracy of LUS for cardiogenic pulmonary edema; (3) studies in adults with a clear diagnosis of heart failure; (4) extracted data could be used to calculate the proportion of true positives (TP), false positives (FP), true negatives (TN) and false negatives (FN).

Exclusion criteria: (1) basic experiments, case reports, reviews, and conference abstracts; (2) studies published in non-English languages; and (3) insufficient data to create 2\*2 tables.

### Data Extraction

Data extraction included baseline information from the literature, outcome indicators, and study design. Baseline information of the literature included first author, time of publication, disease type, sample size, gender, and age. Outcome indicators include the number of patients with true positives, true negatives, false positives, and false negatives. The study design includes the use of a blinded method, diagnostic criteria, and instruments.

### Literature Quality Assessment

The Quality Assessment of Diagnostic Accuracy Studies-2 (QUADAS-2)<sup>7</sup> was used to evaluate the quality of the included literature. Fourteen questions in four main domains of QUADAS were used to evaluate the quality of diagnostic

studies, including case selection (sample source, sample selection, study design), trials to be evaluated (test criteria, test methods), gold standard (reference standard, patient epidemiological characteristics), cash flow and progression (bias, application and interpretation, statistical methods). When evaluating the quality of the literature using the QUADAS tool, the answers are categorized as “yes”, “no”, and “not available/not applicable”. The scores of each study were then counted, and the quality levels were classified according to the scores.

### Statistical Analysis

Statistical analysis was performed using R language (R Foundation for Statistical Computing, Vienna, Austria), and the main indicators were the pooled sensitivity, specificity, and 95% confidence interval (CI). Heterogeneity was assessed using the  $p$ -value and  $I^2$  of the Cochran-Q statistic. A  $p>0.05$  or  $I^2\leq 50\%$  indicated the absence of significant heterogeneity between studies, and a fixed-effects model was used for analysis. A  $p<0.05$  or  $I^2>50\%$  indicated significant heterogeneity between studies, and a random effects model was performed for analysis. The value of the diagnostic test was assessed by constructing a Summary Receiver Operator Characteristic (SROC) and calculating the Area Under The Curve (AUC).

## Results

### Baseline Information of the Included Literature

A total of 516 pieces of literature were searched by computer, and 53 pieces were coarsely included after excluding 88 pieces of duplicate literature and 375 pieces of irrelevant studies, reviews, case reports, and nonclinical studies. After reading the abstract, 25 papers without specified diagnostic methods, 7 papers without access to diagnostic data, and 12 papers without specified types of patients were excluded, and 9 papers were finally included, with 2,097 study participants in total, including 1,047 patients with cardiogenic heart failure. The basic characteristics of the included literature are shown in Table I.

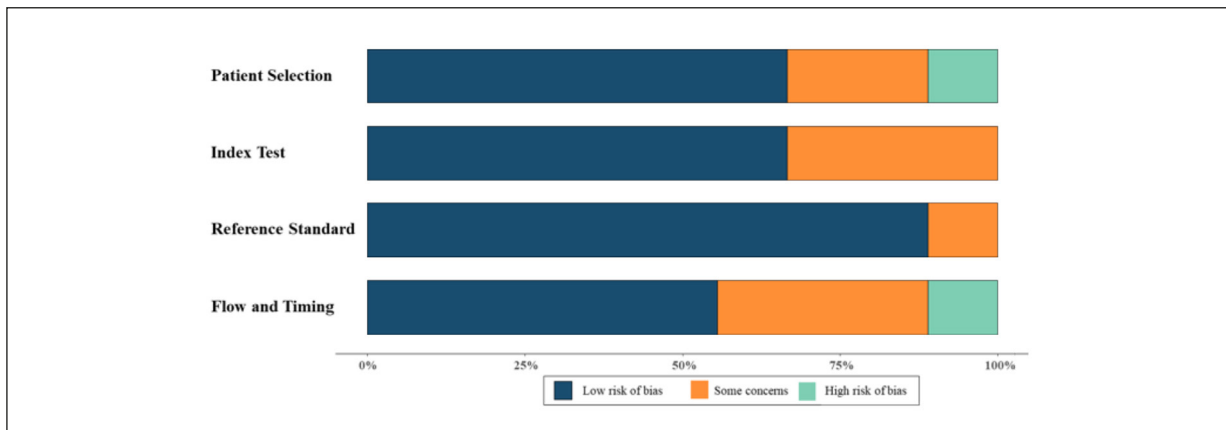
### Quality Evaluation of the Literature

The quality of diagnostic studies was evaluated using QUADAS-2, and all included studies were of moderate to high quality. In all studies,

## Diagnostic efficacy of lung ultrasound in cardiogenic pulmonary edema

**Table I.** Basic characteristics of the included literature.

First author	Year	No. of participants	No. of ADHF	Gold standard	LUS standard	Partitioning method	Sensitivity	Specificity
Perrone T <sup>8</sup>	2017	130	94	Discharge diagnosis made by the ward attending physician	Interstitial syndrome, at least two areas in each hemithorax presenting > 2 B-lines	8 windows	0.91	0.75
Vitturi N <sup>9</sup>	2011	152	68	Identified in accordance with the guidelines of the AHA after review of the participants' clinical, radiological, and biochemical data	Comet-tail artifacts, the number of B lines was greater than 8	12 windows	0.971	0.786
Sartini S <sup>10</sup>	2016	236	114	An independent panel of experts judged all collected data to determine the final diagnosis	Presence of two or more positive regions (three or more B-lines) in each hemithorax	12 windows	0.569	0.888
Zhou S <sup>11</sup>	2014	89	31	Clinical diagnosis	Comet tail sign, multiple flat strong echo lines, also known as 'B' lines, that begin at the interface of the lung wall and gradually converge and weaken from the lung wall interface and spread to the edge of the screen	12 windows	0.806	0.776
Prosen G <sup>12</sup>	2011	218	129	Final hospital diagnosis	A positive ultrasound examination requires two or more positive zones (three or more B-lines) bilaterally of eight zones measured.	8 windows	100	0.944
Gallard E <sup>13</sup>	2014	130	81	Clinical diagnosis	Bilateral presence of at least 3 B lines by lung filed in the anterior or lateral thoracic regions or both	8 windows	88.8	87.8
Dexheimer Neto FL <sup>14</sup>	2015	37	15	Clinical diagnosis	B profile characterized by symmetric bilateral B-lines suggested hemodynamic lung edema	12 windows	0.867	0.864
Öhman J <sup>15</sup>	2019	100	52	Clinical diagnosis	At least three B-lines within one intercostal space	4 windows	0.962	0.813
Pivetta E <sup>16</sup>	2015	1005	463	Diagnosed by past medical history, history of the present illness, physical examination, ECG, and arterial blood gas analysis	Bilateral presence of two or more zones showing the presence of at least three "B-lines"	6 windows	0.905	0.935



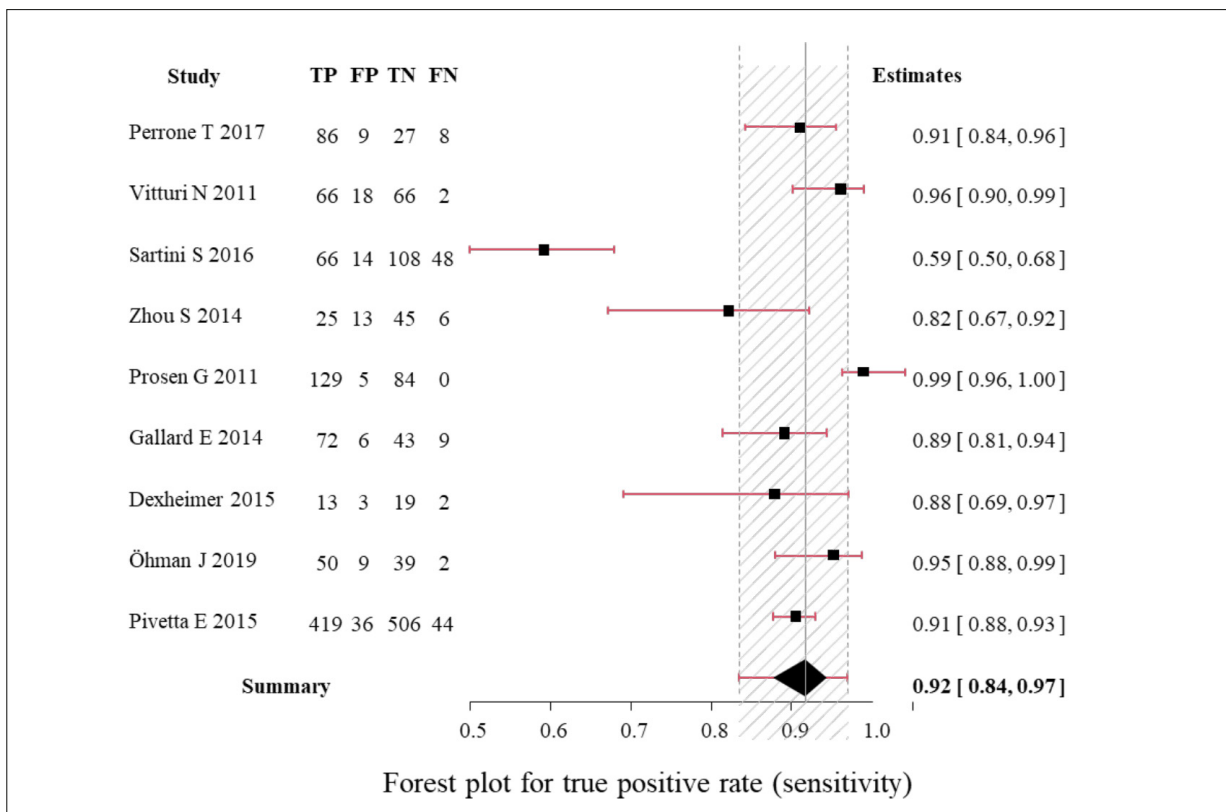
**Figure 1.** Literature quality evaluation.

all sonographers were masked to the diagnostic findings. The results of the literature quality evaluation are shown in Figure 1.

**Results of Meta-Analysis**

Nine pieces of literature were finally included with 2097 participants, including 1047 patients with cardiogenic heart failure. Across the nine

included papers, the pooled sensitivity of LUS in the included studies was 0.92 (95% CI: 0.84, 0.97) with a maximum sensitivity of 0.99 (95% CI: 0.96 to 1.00) and a minimum of 0.59 (95% CI: 0.50, 0.68). The sensitivity forest plot of LUS for the diagnosis of cardiogenic pulmonary edema is shown in Figure 2. The pooled specificity of the included studies was 0.87 (95% CI: 0.82, 0.



**Figure 2.** Sensitivity forest plot for LUS diagnosis of cardiogenic pulmonary edema.

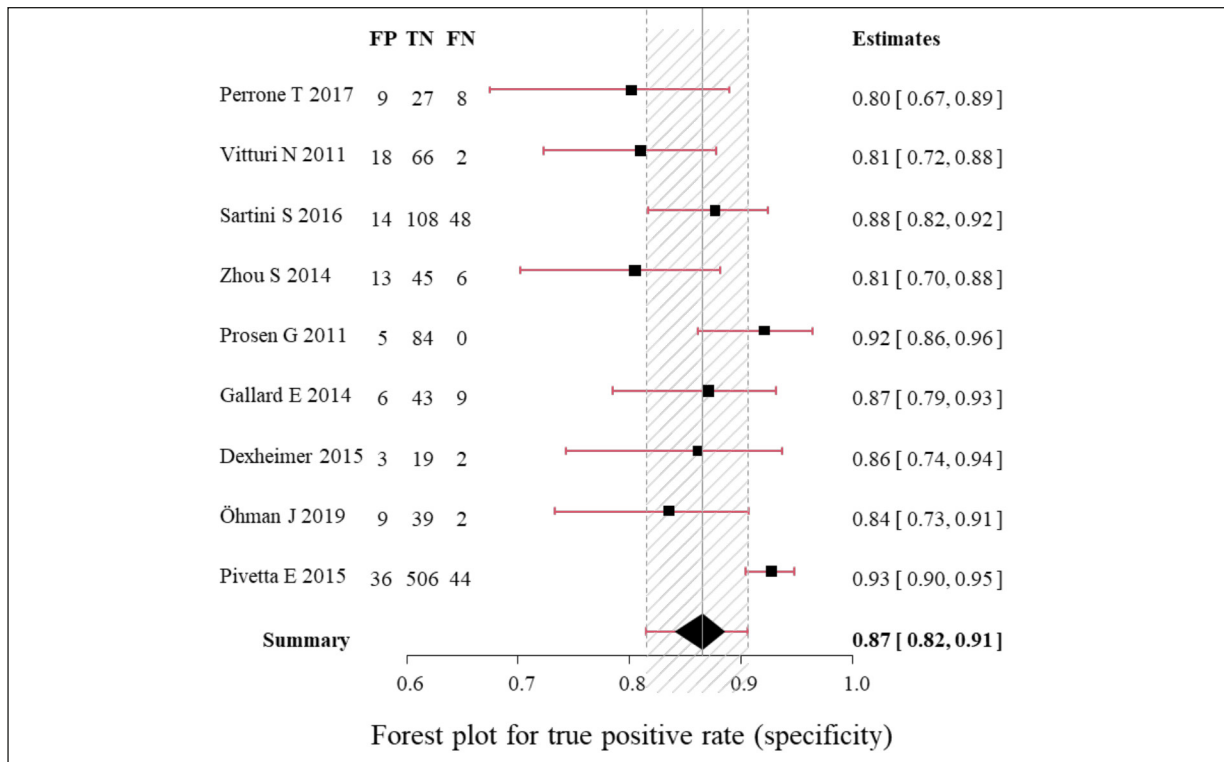


Figure 3. Specificity forest plot for LUS diagnosis of cardiogenic pulmonary edema.

91) with a maximum specificity of 0.93 (95% CI: 0.90-0.95) and a minimum of 0.80 (95% CI: 0.67, 0.89). The pooled AUC was 0.93 (95% CI: 0.84 to 0.97), suggesting a high diagnostic value of LUS in cardiogenic pulmonary edema. The specificity forest plot of LUS for the diagnosis of cardiogenic pulmonary edema is shown in Figure 3.

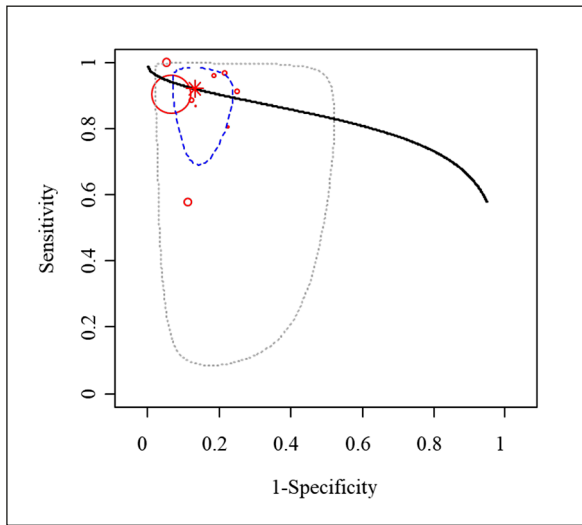
Subgroup analysis was performed based on different partitioning methods, and the partitioning methods included in this study included the four-zone method, six-zone method, eight-zone method, and twelve-zone method. The sensitivity and specificity of the different methods are shown in Table II. The sensitivity was 0.97 (95% CI: 0.78, 0.99) and the specificity was 0.82 (95% CI: 0.46, 0.96) using the four-zone method. The

sensitivity was 0.91 (95% CI: 0.55, 0.99) and the specificity was 0.93 (95% CI: 0.65, 0.99) using the six-zone method. The sensitivity was 1, and the specificity was 0.87 (95% CI: 0.75, 0.95) for the eight-zone method. The twelve-zone method had a sensitivity of 0.85 (95% CI: 0.63, 0.96) and a specificity of 0.83 (95% CI: 0.76, 0.88). The highest sensitivity was found using the eight-zone method, and the highest specificity was observed using the six-zone method.

The SROC curve is a graph that evaluates the diagnostic value of the included studies, and the closer the results are to the upper left corner of the graph, the higher the diagnostic value of the experiment. As shown in Figure 4, the black solid line in the graph is the SROC curve, the blue

Table II. Sensitivity and specificity analysis of different Partitioning methods.

Partitioning method	Sensitivity (95%CI)	Specificity
4 windows	0.97 (0.78, 0.99)	0.82 (0.46, 0.96)
6 windows	0.91 (0.55, 0.99)	0.93 (0.65, 0.99)
8 windows	1	0.87 (0.75, 0.95)
12 windows	0.85 (0.63, 0.96)	0.83 (0.76, 0.88)
Overall	0.92 (0.84, 0.97)	0.87 (0.82, 0.91)

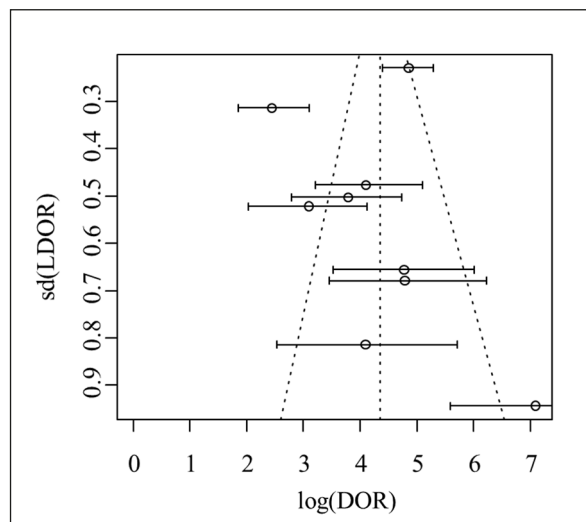


**Figure 4.** SROC curve for LUS diagnosis of cardiogenic pulmonary edema.

dashed line is the 95% CI, and the gray dashed line is the prediction interval. The pooled AUC was 0.93 (95% CI: 0.84-0.97), suggesting that lung ultrasound provides a high diagnostic value for cardiogenic pulmonary edema.

#### Publication Bias

A funnel plot was used to assess the literature's publication bias, and the literature's inclusion was largely symmetrical, suggesting no significant publication bias. The funnel plot of publication bias is shown in Figure 5.



**Figure 5.** Funnel plot of publication bias.

## Discussion

In the present study, the results indicate that lung ultrasound offers a good diagnostic efficacy for cardiogenic pulmonary edema. Nine pieces of literature were finally included with 2,097 participants, including 1,047 patients with cardiogenic heart failure. The results found that the sensitivity of LUS in diagnosing cardiogenic pulmonary edema was 0.92 (95% CI: 0.84, 0.97), the specificity was 0.87 (95% CI: 0.82, 0.91), and the AUC was 0.93 (95% CI: 0.84-0.97), indicating that LUS has high diagnostic value for cardiogenic pulmonary edema. The distribution of B lines is currently the main basis for LUS to differentiate between cardiogenic and cardiac pulmonary edema. Normal and regular pleural lines, diffuse B-line distribution in both lungs with homogeneous and symmetrical distribution, and an interval of about 7 mm between B-lines suggest cardiogenic pulmonary edema. Abnormal and irregular pleural lines, asymmetric B-line distribution, and solid changes in the lower lung lobes and dorsal region are mostly suggestive of non-cardiogenic pulmonary edema<sup>17</sup>.

The rapid differentiation of cardiogenic dyspnea from pulmonary dyspnea is crucial for the following management of the disease. Moreover, dyspnea is a common symptom of multiple diseases without specific differences, thereby posing a serious diagnostic challenge<sup>18</sup>. Ultrasound is an extensively used diagnostic method with convenience, rapidity, and non-invasiveness advantages. In recent years, lung ultrasound has become increasingly appreciated due to its good diagnostic performance and wide application in diseases such as pneumonia, pneumothorax, pulmonary edema, and acute respiratory distress syndrome (ARDS)<sup>19,20</sup>. LUS offers good diagnostic value in pulmonary diseases, such as pulmonary edema, pulmonary solids, pulmonary embolism, and pneumothorax. LUS has been first applied to diagnose bacterial pneumonia in children and adults, showing a specificity close to that of chest radiography and a much higher sensitivity in critically ill patients at the bedside and in the emergency department<sup>21,22</sup>. Alternatively, LUS is available for diagnostic workup of pulmonary embolism. Point-of-care multi-organ ultrasound of pulmonary veins, cardiac veins, and deep veins may improve the diagnostic screening of conditions suspected of pulmonary embolism by improving the efficiency of pretest probability scores, and LUS may be used for diagnosis when vascular CT scanning is unavailable or infeasible<sup>23</sup>.

At present, LUS is a valid alternative to detect interstitial pulmonary edema<sup>24</sup>, but no standard test has been developed. The number of B-lines was found to be positively correlated with N-terminal brain natriuretic peptide precursor (NT-proBNP) levels and negatively correlated with ejection fraction<sup>25</sup>. B-lines of LUS may be promising markers for predicting heart failure, such as secreted frizzled-related protein and extracellular volume fraction by cardiovascular magnetic resonance<sup>26</sup>. Currently, several partitioning methods are used to diagnose cardiogenic pulmonary edema, including the four-zone method, six-zone method, eight-zone method, and 12-zone method, and positive diagnosis is determined based on different partitioning and B-line numbers. In the literature included in this study, the sensitivity of the eight-zone method was significantly higher than the other methods, while the specificity of the other methods saw no significant differences, which may be related to differences between operators<sup>27</sup>.

The recent advances in lung ultrasound for the diagnosis of cardiogenic pulmonary edema are outstanding; however, the specific diagnostic value has not yet been fully elucidated. The present study confirmed the diagnostic efficacy of LUS in cardiogenic pulmonary edema, but the following limitations exist. This study did not compare the differences in diagnostic efficacy between lung ultrasound and other methods, and the diagnostic criteria for cardiogenic pulmonary edema were inconsistent among the included patients. Furthermore, LUS results are closely dependent on operator proficiency, and significant differences exist in the LUS examination methods used in this study. No large sample research is available in exploring differences in LUS.

## Conclusions

Lung ultrasound offers a good diagnostic efficacy for cardiogenic pulmonary edema. Further standardization of the examination method is required to provide a reference for the clinical use of LUS.

---

### Conflict of Interest

The Authors declare that they have no conflict of interests.

---

### Ethical Approval

Not applicable.

---

### Informed Consent

Not applicable.

---

### Funding

The study was funded by the Appropriate Technology Extension Project of the Health and Health of the Autonomous Region in 2021 (Clinician-led application and promotion of bedside intensive ultrasound technology, SYTG-202172).

---

### Authors' Contribution

The Authors declare that they have no conflict of interests.

---

### Authors' Contribution

Yu Zhaoxia is responsible for the guarantor of integrity of the entire study, study design, definition of intellectual content, manuscript editing and manuscript review, Liu Wei is responsible for the study concepts, Ankaerjiang Anniwaer is responsible for the literature research, data acquisition and manuscript preparation. Li Bo is responsible for the clinical studies. Chen Yutang is responsible for the experimental studies. Dong Liangjie is responsible for the data analysis and statistical analysis All authors read and approved the final manuscript.

---

### Availability of Data and Materials

The data used to support the findings of this study are available from the corresponding author upon request.

---

### ORCID ID

Liangjie Dong: 0009-0002-3845-2048.

Jian Li: 0000-0003-4035-9643.

Anniwaer Ankaerjiang: 0000-0002-9346-8520.

Bo Li: 0000-0003-3897-8605.

Yutang Chen: 0000-0002-7603-2565.

Zhaoxia Yu: 0000-0002-2100-7901.

## References

- 1) Sepehrvand N, Dover DC, Islam S, Kaul P, McAlister FA, Miller R, Fine NM, Howlett JG, Armstrong PW, Ezekowitz JA. Predicting Heart Failure With Reduced or Preserved Ejection Fraction From Health Records: External Validation Study. *JACC Heart Fail* 2023; S2213-1779.
- 2) Iwanek G, Ponikowska B, Zdanowicz A, Fudim M, Hurkacz M, Zymlinski R, Ponikowski P, Biegus J. Relationship of Vascular Endothelial Growth Factor C, a Lymphangiogenesis Modulator, With Edema Formation, Congestion and Outcomes in Acute Heart Failure. *J Card Fail* 2023; S1071-9164.
- 3) Gupta AK, Tomasoni D, Sidhu K, Metra M, Ezekowitz JA. Evidence-Based Management of

- Acute Heart Failure. *Can J Cardiol* 2021; 37: 621-631.
- 4) Saito Y, Omae Y, Mizobuchi S, Fujito H, Miyagawa M, Kitano D, Toyama K, Fukamachi D, Toyotani J, Okumura Y. Prognostic significance of pulmonary arterial wedge pressure estimated by deep learning in acute heart failure. *ESC Heart Fail* 2023; 10: 1103-1113.
  - 5) Imanishi J, Maeda T, Ujiro S, Masuda M, Kusakabe Y, Takemoto M, Fujimoto W, Kuroda K, Yamashita S, Iwasaki M, Todoroki T, Okuda M. Association between B-lines on lung ultrasound, invasive haemodynamics, and prognosis in acute heart failure patients. *Eur Heart J Acute Cardiovasc Care* 2023; 12: 115-123.
  - 6) Fountoulaki K, Ventoulis I, Drokou A, Georgarakou K, Parissis J, Polyzogopoulou E. Emergency department risk assessment and disposition of acute heart failure patients: existing evidence and ongoing challenges. *Heart Fail Rev* 2023; 28: 781-793.
  - 7) Lee J, Mulder F, Leeflang M, Wolff R, Whiting P, Bossuyt PM. QUAPAS: An Adaptation of the QUADAS-2 Tool to Assess Prognostic Accuracy Studies. *Ann Intern Med* 2022; 175: 1010-1018.
  - 8) Perrone T, Maggi A, Sgarlata C, Palumbo I, Moscolani E, Ferrari S, Melloul A, Mussinelli R, Boldrini M, Raimondi A, Cabassi A, Salinaro F, Perlini S. Lung ultrasound in internal medicine: A bedside help to increase accuracy in the diagnosis of dyspnea. *Eur J Intern Med* 2017; 46: 61-65.
  - 9) Vitturi N, Soattin M, Allemand E, Simoni F, Realdi G. Thoracic ultrasonography: A new method for the work-up of patients with dyspnea(). *J Ultrasound* 2011; 14: 147-151.
  - 10) Sartini S, Frizzi J, Borselli M, Sarcoli E, Granai C, Gialli V, Cevenini G, Guazzi G, Bruni F, Gonnelli S, Pastorelli M. Which method is best for an early accurate diagnosis of acute heart failure? Comparison between lung ultrasound, chest X-ray and NT pro-BNP performance: a prospective study. *Intern Emerg Med* 2017; 12: 861-869.
  - 11) Zhou S, Zha Y, Wang C, Wu J, Liu W, Liu B. [The clinical value of bedside lung ultrasound in the diagnosis of chronic obstructive pulmonary disease and cardiac pulmonary edema]. *Zhonghua Wei Zhong Bing Ji Jiu Yi Xue* 2014; 26: 558-562.
  - 12) Prosen G, Klemen P, Štrnad M, Grmec S. Combination of lung ultrasound (a comet-tail sign) and N-terminal pro-brain natriuretic peptide in differentiating acute heart failure from chronic obstructive pulmonary disease and asthma as cause of acute dyspnea in prehospital emergency setting. *Crit Care* 2011; 15: R114.
  - 13) Gallard E, Redonnet JP, Bourcier JE, Deshaies D, Largeteau N, Amalric JM, Chedaddi F, Bourgeois JM, Garnier D, Geeraerts T. Diagnostic performance of cardiopulmonary ultrasound performed by the emergency physician in the management of acute dyspnea. *Am J Emerg Med* 2015; 33: 352-358.
  - 14) Dexheimer Neto FL, Andrade JM, Raupp AC, Townsend Rda S, Beltrami FG, Brisson H, Lu Q, Dalcin Pde T. Diagnostic accuracy of the Bedside Lung Ultrasound in Emergency protocol for the diagnosis of acute respiratory failure in spontaneously breathing patients. *J Bras Pneumol* 2015; 41: 58-64.
  - 15) Öhman J, Harjola VP, Karjalainen P, Lassus J. Rapid cardiothoracic ultrasound protocol for diagnosis of acute heart failure in the emergency department. *Eur J Emerg Med* 2019; 26: 112-117.
  - 16) Pivetta E, Goffi A, Lupia E, Tizzani M, Porrino G, Ferreri E, Volpicelli G, Balzaretto P, Banderali A, Iacobucci A, Locatelli S, Casoli G, Stone MB, Maule MM, Baldi I, Merletti F, Cibinel GA, Baron P, Battista S, Buonafede G, Busso V, Conterno A, Del Rizzo P, Ferrera P, Pecetto PF, Moiraghi C, Morello F, Steri F, Ciccone G, Calasso C, Caserta MA, Civita M, Condo' C, D'Alessandro V, Del Colle S, Ferrero S, Griot G, Laurita E, Lazzerro A, Lo Curto F, Michelazzo M, Nicosia V, Palmari N, Ricchiardi A, Rolfo A, Rostagno R, Bar F, Boero E, Frascisco M, Micossi I, Mussa A, Stefanone V, Agricola R, Cordero G, Corradi F, Runzo C, Soragna A, Sciallo D, Vercillo D, Allione A, Artana N, Corsini F, Dutto L, Lauria G, Morgillo T, Tartaglino B, Bergandi D, Cassetta I, Maserà C, Garrone M, Ghiselli G, Ausiello L, Barutta L, Bernardi E, Bono A, Forno D, Lamorte A, Lison D, Lorenzatti B, Maggio E, Masi I, Maggiorotto M, Novelli G, Panero F, Perotto M, Ravazzoli M, Saglio E, Soardo F, Tizzani A, Tizzani P, Tullio M, Ulla M, Romagnoli E. Lung Ultrasound-Implemented Diagnosis of Acute Decompensated Heart Failure in the ED: A SIMEU Multicenter Study. *Chest* 2015; 148: 202-210.
  - 17) Bedetti G, Gargani L, Sicari R, Gianfaldoni ML, Molinaro S, Picano E. Comparison of prognostic value of echographic [corrected] risk score with the Thrombolysis in Myocardial Infarction (TIMI) and Global Registry in Acute Coronary Events (GRACE) risk scores in acute coronary syndrome. *Am J Cardiol* 2010; 106: 1709-1716.
  - 18) Banzett R, Georgopoulos D. Dyspnea in the ICU: It Is Difficult to See What Patients Feel. *Am J Respir Crit Care Med* 2023; 208: 6-7.
  - 19) Sforza A, Mancusi C, Carlino MV, Buonauro A, Barozzi M, Romano G, Serra S, de Simone G. Diagnostic performance of multi-organ ultrasound with pocket-sized device in the management of acute dyspnea. *Cardiovasc Ultrasound* 2017; 15: 16.
  - 20) Meli M, Spicuzza L, Comella M, La Spina M, Trobia GL, Parisi GF, Di Cataldo A, Russo G. The Role of Ultrasound in the Diagnosis of Pulmonary Infection Caused by Intracellular, Fungal Pathogens and Mycobacteria: A Systematic Review. *Diagnostics (Basel)* 2023; 13: 1612.
  - 21) Johannessen Ø, Uthaug Reite F, Bhatnagar R, Øvrebotten T, Einvik G, Myhre PL. Lung Ultrasound to Assess Pulmonary Congestion in Patients with Acute Exacerbation of COPD. *Int J Chron Obstruct Pulmon Dis* 2023; 18: 693-703.



- 22) Biagi C, Pierantoni L, Baldazzi M, Greco L, Dormi A, Dondi A, Faldella G, Lanari M. Lung ultrasound for the diagnosis of pneumonia in children with acute bronchiolitis. *BMC Pulm Med* 2018; 18: 191.
- 23) Wang X, Zhao H, Liu D, Zhang H, Du W, Chai W, Zhang Q, Chao Y, Yin W, Zhang L, Wang C. [The effects of Peking Union Medical College Hospital Critical Ultrasonic Management scheme on the etiological diagnosis of dyspnea and/or hemodynamic instability in ICU patients]. *Zhonghua Nei Ke Za Zhi* 2014; 53: 793-798.
- 24) Mongodi S, De Luca D, Colombo A, Stella A, Santangelo E, Corradi F, Gargani L, Rovida S, Volpicelli G, Bouhemad B, Mojoli F. Quantitative Lung Ultrasound: Technical Aspects and Clinical Applications. *Anesthesiology* 2021; 134: 949-965.
- 25) He J, Yi S, Zhou Y, Hu X, Lun Z, Dong H, Zhang Y. B-Lines by Lung Ultrasound Can Predict Worsening Heart Failure in Acute Myocardial Infarction During Hospitalization and Short-Term Follow-Up. *Front Cardiovasc Med* 2022; 9: 895133.
- 26) Wu J, Zheng H, Liu X, Chen P, Zhang Y, Luo J, Kuang J, Li J, Yang Y, Ma T, Yang Y, Huang X, Liang G, Liang D, Hu Y, Wu J, Arnott C, Mai W, Huang Y. Prognostic Value of Secreted Frizzled-Related Protein 5 in Heart Failure Patients With and Without Type 2 Diabetes Mellitus. *Circ Heart Fail* 2020; 13: e007054.
- 27) Rinaldi L, Milione S, Fascione MC, Pafundi PC, Altruda C, Di Caterino M, Monaco L, Reginelli A, Perrotta F, Porta G, Venafo M, Acierno C, Mastrocinque D, Giordano M, Bianco A, Sasso FC, Adinolfi LE. Relevance of lung ultrasound in the diagnostic algorithm of respiratory diseases in a real-life setting: A multicentre prospective study. *Respirology* 2020; 25: 535-542.