

Is subareolar intraoperative biopsy still necessary to predict nipple involvement?

E. BUFI¹, M. PIACENTINI², P. BELLI^{1,2}, M. CONTI¹, G. CIRIELLO², G. FRANCESCHINI^{2,3}, M. GIULIANI⁴, D. TERRIBILE^{2,3}, I. VALENTE⁵, R. MANFREDI^{1,2}

¹UOC Radiologia Diagnostica ed Interventistica Generale, Fondazione Policlinico Universitario A. Gemelli IRCCS, Rome, Italy

²Università Cattolica del Sacro Cuore, Rome, Italy

³UOC Chirurgia Senologica, Fondazione Policlinico Universitario A. Gemelli IRCCS, Rome, Italy

⁴UOC Radiologia Frosinone-Alatri, Ospedale F. Spaziani, Frosinone, Italy

⁵UOC Radiologia e Neuroradiologia, Fondazione Policlinico Universitario A. Gemelli IRCCS, Rome, Italy

Abstract. – **OBJECTIVE:** To predict the occult tumor involvement of nipple-areola complex (NAC) using preoperative MR imaging and to investigate whether the intraoperative histopathological examination of the subareolar tissue is still necessary.

PATIENTS AND METHODS: Out of 712 patients submitted to nipple-sparing mastectomy (NSM) between 2014 and 2019, we selected 188 patients who underwent preoperative breast MRI. Breast MRI and intraoperative histopathological examination of the subareolar tissue were performed to predict NAC involvement at permanent pathology. All parameters were correlated with final pathological NAC assessment by univariate and multivariate analysis.

RESULTS: Forty-three patients (22.9%) had tumor involvement of the NAC. At univariate analysis, non-mass enhancement type ($p = 0.009$), multifocality/multicentricity ($p = 0.002$), median tumor size ($p < 0.001$), median tumor-NAC distance measured by MRI ($p < 0.001$), tumor-NAC distance ≤ 10 mm ($p < 0.001$) and tumor-NAC distance ≤ 20 mm ($p < 0.001$), and lymphovascular invasion ($p = 0.001$) were significantly correlated with NAC involvement. At multivariate analysis, only tumor-NAC distance ≤ 10 mm retained statistical significance. The sensitivity and specificity of MRI tumor-NAC distance ≤ 10 mm were 79.1% and 97.2% and those of intraoperative pathologic assessment were 74.4% and 100%, respectively.

CONCLUSIONS: Tumor-NAC distance is the only reliable MRI characteristic that can predict NAC involvement in breast cancer patients. Although several cut-offs showed promising performances, intraoperative pathologic assessment is still mandatory.

Key Words:

Breast cancer, Magnetic resonance imaging, Mastectomy, Subareolar, Intraoperative pathology, Nipple-sparing.

Introduction

Over the last 20 years, advances in breast surgery and reconstruction techniques have led to significant improvements in terms of both oncological outcomes and aesthetics results among patients with breast cancer^{1,2} a high level of complications has been registered. From 2015 onward, in our centers, a pre-pectoral approach has been adopted. The authors sought to describe the Italian trend to gradually discard the sub-pectoral technique with lower lateral pole coverage of the prosthesis using ADMs comparing it with the pre-pectoral approach with ADMs, without any muscle dissection, in terms of complication rates. Materials and Methods: A multicenter retrospective clinical study was performed from January 2010 to June 2018. The enrolled patients were divided into two groups: Cases with an ADM-only coverage pre-pectoral reconstruction made up the first group (Group 1. In this setting, recently, a new type of mastectomy with the preservation of the nipple-areola complex (NAC), named “NAC sparing mastectomy” (NSM), has been proposed. It has acquired a progressively increasing role in breast reconstruction approaches as a possible alternative in selected breast cancer patients³⁻⁶. The shift toward NSM is associated with recent data suggesting that occult NAC involvement occurs in a minority of breast cancer patients undergoing mastectomy. The associated rate of local recurrence (from 0% to 24%)⁷, is not statistically different from conventional mastectomy⁸. The likelihood of NAC involvement has been associated with several tumor characteristics, such as retroareolar location, distance from the NAC,

size, multifocality/multicentricity, grade, lymphovascular invasion and extensive intraductal component⁸⁻¹². More recently, tumor-NAC distance evaluated using magnetic resonance images (MRI) has been demonstrated to outperform the results of mammography (MX) in predicting NAC involvement^{4,13,14}. Numerous studies^{4,9,15-18} have demonstrated that the risk of NAC involvement increases with decreasing tumor-to-nipple distance. However, the optimal cut-off distance for considering a patient an appropriate NSM candidate remains controversial. Different authors recommend a minimum tumor-to-nipple distance from 5 to 10 mm¹³, rather than the previously suggested 20 mm cutoff^{1,8,15,19}. For these reasons, during NSM, intraoperative histopathological examination of the subareolar tissue is mandatory to exclude the presence of malignancy at this site, and consequently, to avoid a conversion to conventional skin-sparing mastectomy (SSM)^{7,8}; this procedure is not free from vascular complications at the NAC²⁰⁻²⁶.

In this investigation, we evaluated the predictive value of patients' clinicopathologic factors and MRI features in assessing NAC involvement; moreover, we identified an MRI tumor-NAC distance cut-off with potential to reduce the need of intraoperative histopathological examination.

Patients and Methods

Study Population

The records of breast cancer patients treated at our Breast Imaging Unit of the Fondazione Policlinico Universitario A. Gemelli of Rome (Italy) were reviewed retrospectively to identify all consecutive patients with newly diagnosed breast cancer who underwent preoperative breast MRI between January 2014 and December 2019, and who were subsequently treated with mastectomy, either NSM or SSM.

Exclusion criteria were as follows: a) patients with locally advanced tumors who underwent to preoperative chemotherapy; b) patients with inflammatory breast cancer and Paget's disease of the nipple; c) patients with evident clinical tumor involvement of the NAC and/or the skin; d) patients who underwent to previous surgery and/or radiation therapy; and e) patients with inadequate quality of the images (i.e., motion artifacts, improper positioning). All patients signed a written informed consent.

MRI Examination and Interpretation

MR examinations were acquired with 1.5 T equipment and dedicated phased-array 8-channel coil (HDx Signa Excite, GE HealthCare Milwaukee, WI), following the recommended technical requirements for breast imaging²⁷, within 2 weeks before surgery. In particular, the dynamic study was performed by a 3D VIBRANT sequence (slice thickness 2.6 mm; acquisition matrix 416x416; temporal resolution 90 s) acquired before and five times after intravenous contrast agent administration (0.1 mmol/kg of Gadoteridolo, ProHance, Bracco Imaging, Milan, Italy) at a flow rate of 2 mL/s, followed by 20 ml saline flush. Before contrasting medium injection, T1-weighted and T2-weighted time inversion recovery sequences were also acquired, as well as diffusion-weighted imaging (DWI), according to current recommendations. Subtracted images and multiplanar reconstructions (MPR) were derived from the dynamic study dataset.

Two radiologists dedicated to breast imaging (with at least 5 years of experience in breast MRI) reviewed the images for every patient and were blinded to clinical and pathological information. According to the BI-RADS MRI lexicon²⁸, each breast lesion was classified as focus, mass, or non-mass enhancement. Lesions were also categorized as unifocal, multifocal, and/or multicentric according to lesion number and location. The minimum distance between the base of the NAC and the nearest margin of the lesion was measured by electronic calipers, using MPR images. The minimum distance between the axial and sagittal measurements was also recorded. In the case of bifocal, multifocal, and multicentric tumors, the distances were computed between the NAC and the nearest lesion⁴.

Pathologic Examination of the NAC

All NSM candidates underwent intraoperative subareolar tissue examination. The NAC was considered involved in the case of the presence of invasive ductal or lobular carcinoma cells and/or ductal carcinoma in situ/ductal intraepithelial neoplasia (DIN1c-DIN3), but not of lobular carcinoma in situ/lobular intraepithelial neoplasia (LIN1-LIN3). The NAC was removed at the time of mastectomy or as a second surgery only if either of the samples revealed malignancy at intraoperative or final histology, respectively. The subareolar tissue was subsequently reviewed at definitive histology to confirm the intraoperative diagnosis.

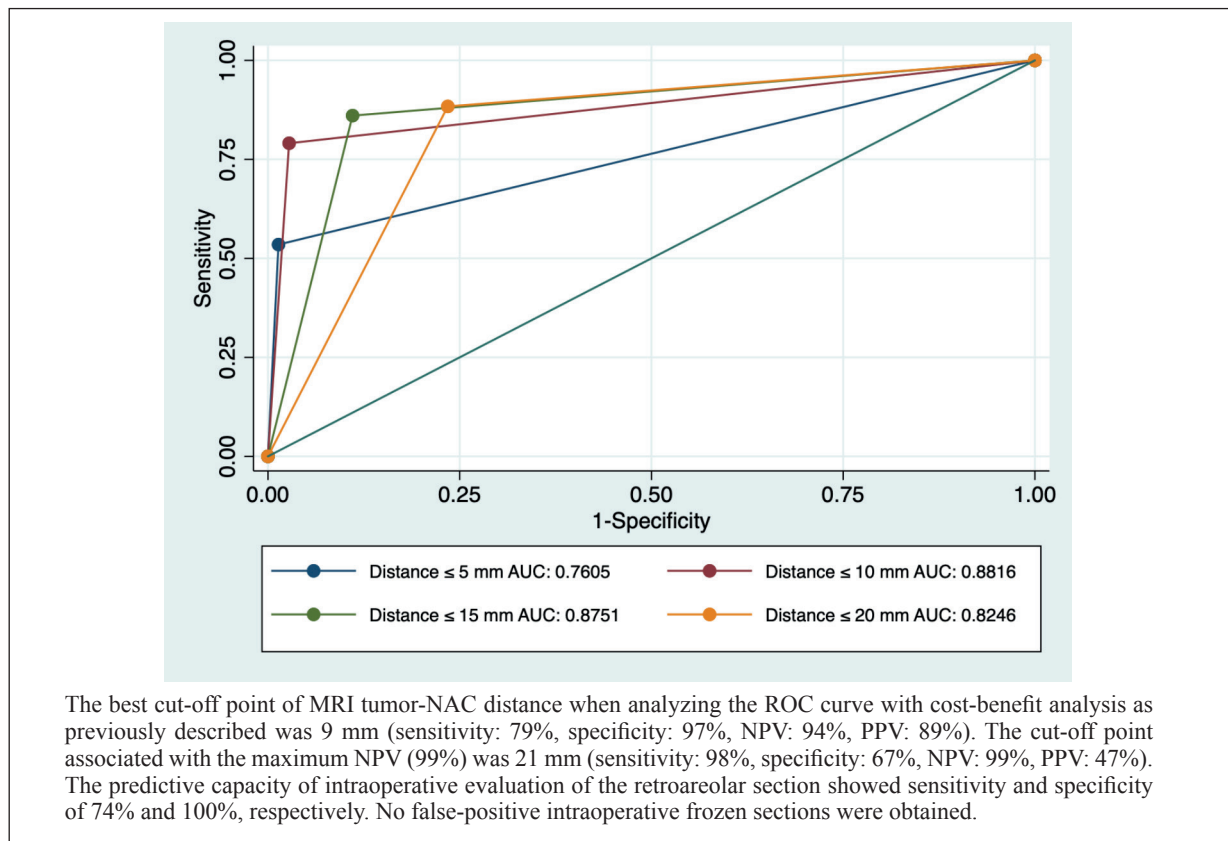


Figure 1. Receiver Operating Characteristic (ROC). Curve for the performance of different cut-off values of tumor-NAC distance at MRI to discriminate involvement at permanent pathology. AUC: area under the curve.

Statistical Analysis

The population was divided into two subgroups (NAC involved vs. NAC not-involved). At univariate analysis, differences in MRI findings between the two groups were analyzed using the *t*-test (for Gaussian continuous variables) or Mann-Whitney U Test (for Non-Gaussian continuous variables) and the Chi-squared test (for dichotomous variables) or the Fisher exact test (for dichotomous variable with less than 5 observations). Factors that showed a significant ($p < 0.05$) association with outcome in the univariate analysis were inserted into the multivariate analysis using a logistic regression model [adjusted for pre-specified confounding factors, such as age and background parenchymal enhancement (BPE)]. Sensitivity, specificity, positive predicting value (PPV), negative predicting value (NPV) and accuracy were evaluated for the three cut-offs points already used in literature (5 mm, 10 mm, 20 mm)¹⁶. Receiver operating characteristic (ROC) curves were calculated for the tumor-nipple distance at MRI. The optimal cut-off values were determined to

maximize (99%) the NPV and using a cost-benefit analysis²⁹ These measures and the related indices, “true positive fraction” and “false positive fraction,” are more meaningful than “accuracy,” yet do not provide a unique description of diagnostic performance because they depend on the arbitrary selection of a decision threshold. The receiver operating characteristic (ROC. This represents the evaluation of expected “cost” of the consequences of performing a diagnostic test, subject to the true positive fraction and false-positive fraction being constrained to lie on the ROC curve. We will assume a cost of each false-negative patient worth three times the cost of each false positive. The alpha level was 0.05.

Results

Out of 712 patients who underwent NSM, 524 patients were excluded as they fell into the exclusion criteria and 188 patients were enrolled. Of 188 breast cancers, 43 (22.9%) showed NAC in-

involvement on pathologic examination (Table I). The median tumor size was 29 mm (IQR 15-50 mm); thirty-eight cancers (20.2%) were ≤ 10 mm from the nipple, 72 cancer (38.3%) were ≤ 20 mm and 116 (61.7%) were > 20 mm from the nipple. The median tumor-nipple distance was 22 mm (IQR 13-40 mm).

Seventy-two (38.9%) were invasive ductal carcinomas, 29 (15.7%) were invasive lobular carcinomas, 41 (22.2%) were ductal carcinomas *in situ* and 43 (23.3%) were others type of breast cancer.

At univariate analysis, non-mass enhancement type ($p = 0.009$), multifocal/multicentric tumors ($p = 0.002$), median tumor size ($p < 0.001$), median tumor-nipple distance ($p < 0.001$) and lymphovascular invasion ($p = 0.001$) were all significantly associated with NAC involvement at permanent pathology. The multivariate analysis revealed that

only tumor-nipple distance ≤ 10 mm ($p < 0.001$) provided independent information over the likelihood of NAC involvement at final pathology (Table I).

Several cut-offs of the tumor-NAC distance for the prediction of NAC involvement at MRI were tested (5 mm, 10 mm, 15 mm, 20 mm); Table II shows sensitivity, specificity, PPV, NPV, accuracy, and the area under the curve (AUC) obtained from the ROC curves using these cut-offs (Figure 1).

Discussion

Overall, 22.9% (43/188) of the patients in our series had NAC involvement at the final pathology examination. These results were consistent with previously reported studies^{7,8}, which re-

Table I. Univariate and multivariate analysis associated with involvement of NAC.

Characteristics	Overall	NAC not-involved	NAC involved	p-value	OR (LB-UB)
N	188	145 (77.1%)	43 (22.9%)		
Age	47.7	47.6	47.9	.847	.95 (.87-1.03)
BPE				.324	
1 (ref.)	72 (38.3%)	58 (40.0%)	14 (32.6%)		
2	61 (32.5%)	48 (33.1%)	13 (30.2%)		.53 (.89-3.23)
3	31 (16.5%)	24 (16.5%)	7 (16.3%)		1.26 (.19-8.42)
4	24 (12.8%)	15 (10.3%)	9 (20.9%)		2.75 (.33-22.76)
Enhancement type				.009	
Mass (ref.)	80 (42.8%)	69 (47.9%)	11 (25.6%)		
Non-mass	107 (57.2%)	75 (52.1%)	32 (74.4%)		3.81 (.71-20.47)
Focality				.002	
Unifocal (ref.)	63 (34.2%)	57 (40.1%)	6 (14.3%)		
Multifocal/Multicentric	121 (65.8%)	85 (59.9%)	36 (85.7%)		.55 (.10-2.97)
Median tumor size mm at MR (IQR)	29 (15-50)	24 (14-45)	50 (28-69)	<.001	.34 (.21-4.12)
Median t-NAC distance mm (IQR)	22 (13-40)	28 (20-43)	2 (0-8)	<.001	.31 (.19-2.56)
Tumor-nipple distance					
≤ 10 mm	38 (20.2%)	4 (2.8%)	34 (79.1%)	<.001	10.48 (5.67-16.15) *
≤ 20 mm	72 (38.3%)	34 (23.5%)	38 (88.4%)	<.001	1.92 (.36-1.13)
Grade± 3	62 (37.4%)	46 (36.2%)	16 (41.0%)	.587	-
Lymphovascular Invasion	64 (34.8%)	41 (28.7%)	23 (56.1%)	.001	2.46 (.57-10.63)
ER+	158 (84.0%)	126 (86.9%)	32 (74.4%)	.050	.20 (.02-1.41)
PR+	147 (78.2%)	117 (80.7%)	30 (69.8%)	.128	-
Her2 +	61 (32.5%)	44 (30.3%)	17 (39.5%)	.258	-
Ki67 (20%)	100 (53.2%)	76 (52.4%)	24 (55.8%)	.695	-
Permanent pathology				.366	-
DCIS	41 (22.2%)	28 (19.7%)	13 (30.2%)		-
IDC	72 (38.9%)	59 (41.5%)	13 (30.2%)		-
ILC	29 (15.7%)	21 (14.8%)	8 (17.6%)		-
Others	43 (23.3%)	34 (23.9%)	9 (20.9%)		-

*: p -value < 0.05 ; OR: odds-ratio; LB: lower-bound; UB: upper bound; BPE: background parenchymal enhancement; IQR: interquartile range; ER: estrogen receptors; PR: progesterone receptors; DCIS: ductal carcinoma in-situ; IDC: invasive ductal carcinoma; ILC: invasive lobular carcinoma; t-NAC distance: tumor-nipple areola complex distance.

vealed that nipple invasion ranges from 9.5% to 24.6%. In our study, several clinicopathologic factors were related to NAC involvement in the univariate analysis: median tumor size, non-mass enhancement type, multicentricity/multifocality, lymph node metastasis, and tumor-nipple distance were predictive of NAC invasion. These findings were consistent with previous reports, which showed that large tumor size (≥ 20 mm)^{7,14,30,31}, enhancement type^{14,32-34}, multicentricity or multifocality^{13,14,35}, lymphovascular invasion^{30,31}, and tumor-nipple distance^{2,9,11,13,14} were associated with nipple involvement. In our analysis, only tumor-nipple distance with a 10 mm cut-off was a significant ($p < 0.001$) predictor of NAC involvement by breast cancer. Consistent with our study, tumor-nipple distance was the most notable factor in the prediction of NAC involvement in many studies^{4,9,13,15,17,18,36}; however, no consensus has yet been reached as to the minimum tumor-to-nipple distance acceptable to allow for NAC preservation at the time of mastectomy. Recent works^{4,13} have suggested that tumor-to-nipple distance of less than 20 mm may be appropriate in nipple-sparing mastectomy and if the frozen biopsy specimen is found to be negative for tumor cells. D'Alonzo et al⁴ recommended that a tumor-to-nipple distance of 10 mm could be considered a safe cut-off for NSM candidacy based on their 2012 study of 100 mastectomy cases. Ponzzone et al¹³ recommended a tumor to nipple distance cut-off of 5 mm in determining NSM candidacy based on their prospective study of 112 nipple-sparing mastectomies. Koh et al³² found that tumor-nipple enhancement and tumor-nipple distance on MRI could predict NAC involvement in breast cancer. When enhancement was evaluated on both early and delayed phase images with a combined tumor-nipple distance of ≤ 10 mm, the prediction of NAC involvement showed the best performance. Given different values proposed in the literature, several potential cut-off values of tumor-nipple distance were tested in our study (Table II), and we found that the AUC was the highest (0.881) when a tumor-nipple distance was ≤ 10 mm, with a sensitivity of 79.1% and specificity of 97.2%.

Even though preoperative MRI proved to be an informative tool, intraoperative subareolar tissue frozen section still stands as the reference standard to confirm the absence of tumoral cells in patients who are candidates for NSM³⁷. In the literature, studies evaluating the accuracy of intraoperative subareolar frozen section are limited, and false-negative rates vary from 0.7%³⁸ to

33.3%³⁹. In our study, the intraoperative histopathological analysis showed a sensitivity and specificity of 74.4% and 100%, respectively, with NPV of 92.9% and a PPV of 100%. Moreover, the intraoperative histopathological examination of the subareolar tissue may determine a higher risk of late vascular complications of the NAC.

If subareolar sections can be shown to provide earlier detection of occult NAC involvement, facilitate reconstruction or reduce the total number of surgeries, then there is a benefit to their continued use. In contrast, if the accuracy of subareolar sections is insufficient and does not affect the management strategy, their exclusion from routine practice could be justified³⁷. For these reasons, while some institutions favor the use of intraoperative sub-areolar analysis⁴⁰⁻⁴², others routinely rely on final subareolar pathology results only^{43,44}.

We tried to identify a cut-off value of tumor-nipple distance at preoperative MRI that could exclude with adequate accuracy the NAC involvement, with the final purpose to avoid the intraoperative sub-areolar analysis. Hence, we performed a cost-benefit analysis by setting the ratio between the weight of a false-negative and a false-positive to 3:1, and we found that the best cut-off was 9 mm (NPV 94%, PPV 89%). When we try to maximize the NPV (99%), the best cut-off is 21 mm (PPV 47%). This means that out of 100 patients who display a 21 mm or greater distance between the tumor and the nipple, only one will require secondary treatment following the final pathology examination. According to this performance, 106 patients (56.4%) could have avoided the intraoperative pathological assessment.

The present study has some limitations, including its retrospective nature, which is in part addressed by having all MRI examinations reviewed blinded to surgical and histopathological data. In addition, the present study is a single institution experience at an academic medical center. An important limitation is that MRI findings were not compared with other conventional imaging (such as mammography); unfortunately, a comparison between MX and MRI was not possible in our study since only a few patients had both exams performed.

Conclusions

Our data show that tumor-NAC distance at MRI is the most important predictive factor of NAC-involvement. We found that the 10 mm cut-

Table II. Diagnostic performance of different measurements of tumor-NAC distance by MRI.

Predicting factor	Sensitivity	Specificity	PPV	NPV	Accuracy	AUC
Tumor-nipple distance ≤ 5 mm	53.5%	98.6%	92.0%	87.7%	88.3%	0.760
Tumor-nipple distance ≤ 10 mm	79.1%	97.2%	89.5%	94.0%	93.1%	0.881
Tumor-nipple distance ≤ 15 mm	86.1%	89.0%	69.8%	95.6%	88.3%	0.875
Tumor-nipple distance ≤ 20 mm	88.4%	76.6%	52.8%	95.7%	79.3%	0.824

PPV: positive predicting value; NPV: negative predicting value; AUC: area under the curve.

off is associated with the best AUC. When we considered the cost of each false-negative patient worth three times the cost of each false positive, the best cut-off value was 9 mm. When we tried to maximize the negative predictive value of this test (up to 99%), the best cut-off was 21 mm; this tumor-NAC distance seems sufficiently reliable to indicate the absence of NAC involvement, and it could allow avoiding intraoperative pathologic assessment. However, a randomized controlled trial is necessary to verify the real predictive performances of preoperative MRI examination; meanwhile, intraoperative pathologic assessment is still mandatory.

Conflict of Interest

The Authors declare that they have no conflict of interests.

References

- Ribuffo D, Berna G, De Vita R, Di Benedetto G, Cigna E, Greco M, Valdatta L, Onesti MG, Lo Torto F, Marcasciano M, Redi U, Quercia V, Kaciulyte J, Cherubino M, Losco L, Mori FLR, Scalise A. Dual-plane retro-pectoral versus pre-pectoral DTI breast reconstruction: an Italian multicenter experience. *Aesthetic Plast Surg* 2020. doi: 10.1007/s00266-020-01892-y. Online ahead of print.
- Torto FLO, Marcasciano M, Kaciulyte J, Redi U, Barellini L, De Luca A, Perra A, Frattaroli JM, Cavalieri E, Di Taranto G, Greco M, Casella D. Pre-pectoral breast reconstruction with TiLoop® Bra Pocket: a single center prospective study. *Eur Rev Med Pharmacol Sci* 2020; 24: 991-999.
- Gupta A, Borgen PI. Total skin sparing (nipple sparing) mastectomy: what is the evidence? *Surg Oncol Clin N Am* 2010; 19: 555-566.
- D'Alonzo M, Martincich L, Biglia N, Pisacane A, Maggiorotto F, Rosa G De, Montemurro F, Kubatzki F, Sisoni P, Ponzzone R. Clinical and radiological predictors of nipple-areola complex involvement in breast cancer patients. *Eur J Cancer* 2012; 48: 2311-2318.
- Casella D, Di Taranto G, Marcasciano M, Sordi S, Kothari A, Kovacs T, Lo Torto F, Cigna E, Ribuffo D, Calabrese C. Nipple-sparing bilateral prophylactic mastectomy and immediate reconstruction with TiLoop® Bra mesh in BRCA1/2 mutation carriers: a prospective study of long-term and patient reported outcomes using the BREAST-Q. *Breast* 2018; 39: 8-13.
- Onesti MG, Di Taranto G, Ribuffo D, Scuderi N. ADM-assisted prepectoral breast reconstruction and skin reduction mastectomy: expanding the indications for subcutaneous reconstruction. *J Plast Reconstr Aesthetic Surg* 2020; 73: 673-680.
- Huang N, Wu J. Nipple-sparing mastectomy in breast cancer: from an oncologic safety perspective. *Chin Med J (Engl)* 2015; 128: 2256-2261.
- Headon HL, Kasem A, Mokbel K. The oncological safety of nipple-sparing mastectomy: a systematic review of the literature with a pooled analysis of 12,358 procedures. *Arch Plast Surg* 2016; 43: 328-338.
- Schechter A, Freeman M, Giri D, Sabo E, Weinzeig J. Applicability of the nipple-areola complex-sparing mastectomy: a prediction model using mammography to estimate risk of nipple-areola complex involvement in breast cancer patients. *Ann Plast Surg* 2007; 17: 372-373.
- Billar JAY, Dueck AC, Gray RJ, Wasif N, Pockaj BA. Preoperative predictors of nipple-areola complex involvement for patients undergoing mastectomy for breast cancer. *Ann Surg Oncol* 2011; 18: 3123-3128.
- Loewen MJ, Jennings JA, Sherman SR, Slaikeu J, Ebrom PA, Davis AT, Fitzgerald TL. Mammographic distance as a predictor of nipple-areola complex involvement in breast cancer. *Am J Surg* 2008; 195: 391-395.
- Mallon P, Feron JG, Couturaud B, Fitoussi A, Lemasurier P, Guihard T, Cothier-Savay I, Reyrol F. The role of nipple-sparing mastectomy in the breast cancer: a comprehensive review of the literature. *Plast Reconstr Surg* 2013; 131: 969-984.
- Ponzzone R, Maggiorotto F, Carabalona S, Rivolin A, Pisacane A, Kubatzki F, Renditore S, Carlucci S, Sgandurra P, Marocco F, Magistris A, Regge D, Martincich L. MRI and intraoperative pathology to predict nipple-areola complex (NAC) involvement in patients undergoing NAC-sparing mastectomy. *Eur J Cancer* 2015; 51: 1882-1889.
- Piato JRM, De Andrade RDJA, Chala LF, De Barros N, Mano MS, Melitto AS, Goncalves R, Junior

- JMS, Baracat EC, Filassi JR. MRI to predict nipple involvement in breast cancer patients. *Am J Roentgenol* 2016; 206: 1124-1130.
- 15) Steen ST, Chung AP, Han SH, Vinstein AL, Yoon JL, Giuliano AE. Predicting nipple-areolar involvement using preoperative breast MRI and primary tumor characteristics. *Ann Surg Oncol* 2013; 20: 633-639.
 - 16) Giannini V, Bianchi V, Carabalona S, Mazzetti S, Maggiorotto F, Kubatzki F, Regge D, Ponzone R, Martincich L. MRI to predict nipple-areola complex (NAC) involvement: an automatic method to compute the 3D distance between the NAC and tumor. *J Surg Oncol* 2017; 116: 1069-1078.
 - 17) Cense HA, Rutgers EJT, Cardozo ML, Lanschot JJB Van. Nipple-sparing mastectomy in breast cancer : a viable option ? *Eur J Surg Oncol* 2001; 27: 521-526.
 - 18) Cho J, Chung J, Cha E, Lee JE, Kim JH. Can preoperative 3-T MRI predict nipple-areolar complex involvement in patients with breast cancer ? *Clin Imaging* 2015; 40: 119-124.
 - 19) Karamchandani DM, Chetlen AL, Riley MP, Schetter S, Hollenbeak CS, Mack J. Pathologic-radiologic correlation in evaluation of retroareolar margin in nipple-sparing mastectomy. *Virchows Arch* 2015; 466: 279-287.
 - 20) Chirappappa P, Petit J, De Lorenzi F, Rietjens M, Garusi C, Martella S, Barbieri B, Gottardi A, Manconi A, Lomeo G, Alaa H, Visnu L. Nipple sparing mastectomy: does breast morphological factor related to necrotic complications? *Breast* 2013; 2: 1-7.
 - 21) Frey J, Salibian A, Choi M, Karp N. Mastectomy flap thickness and complications in nipple-sparing mastectomy: objective evaluation using magnetic resonance imaging. *Breast* 2016; 5: 1-8.
 - 22) Lee TJ, Oh TS, Kim EK, Suh H, Ahn SH, Son H, Lee JW, Cho J, Eom JS. Risk factors of mastectomy skin flap necrosis in immediate breast reconstruction using low abdominal flaps. *J Plast Surg Hand Surg* 2016; 50: 302-306.
 - 23) Lohsiriwat V, Rotmensz N, Botteri E, Intra M, Veronesi P, Martella S, Garusi C, Lorenzi F De, Manconi A, Lomeo G, Rietjens M, Schorr M, Kneubil MC, Petit JY. Do clinicopathological features of the cancer patient relate with nipple areolar complex necrosis in nipple-sparing mastectomy? *Ann Surg Oncol* 2013; 20: 990-996.
 - 24) Gould D, Hunt K, Liu J, Kuerer H, Crosby M, Babiera G, Kronowitz S. Impact of surgical techniques, biomaterials, and patient variables on rate of nipple necrosis after nipple-sparing mastectomy. *Plast Reconstr Surg* 2014; 132: 330-338.
 - 25) Carlson GW, Chu CK, Moyer HR, Duggal C, Losken A. Predictors of Nipple Ischemia after Nipple Sparing Mastectomy. *Breast J* 2014; 20: 69-73.
 - 26) Algaithy Z, Petit J, Lohsiriwat V, Maisonneuve P, Rey P, Baros N, Lai H, Mulas P, Barbalho D, Veronesi P, Rietjens M. Nipple sparing mastectomy: can we predict the factors predisposing to necrosis ? *Eur J Surg Oncol* 2012; 38: 125-129.
 - 27) Sardanelli F, Boetes C, Borisch B, Decker T, Federico M, Gilbert FJ, Helbich T, Heywang-ko SH, Kaiser WA, Kerin MJ, Mansel RE, Marotti L, Martincich L, Mauriac L, Meijers-heijboer H, Orecchia R, Panizza P, Ponti A, Purushotham AD, Regitnig P, Rosselli M, Turco D, Thibault F, Wilson R. Magnetic resonance imaging of the breast: recommendations from the EUSOMA working group. *Eur J Cancer* 2010; 46: 1296-1316.
 - 28) Spak DA, Plaxco JS, Santiago L, Dryden MJ, Dogan BE. BI-RADS® fifth edition: a summary of changes. *Diagn Interv Imaging* 2017; 98: 179-190.
 - 29) Nezl CE. Basic principles of ROC analysis. *Semin Nucl Med* 1978; 8: 283-298.
 - 30) Simmons RM, Hollenbeck ST, Latrenta GS. Areola-sparing mastectomy with immediate breast reconstruction. *Ann Plast Surg* 2003; 51: 547-551.
 - 31) Brachtel E, Rusby J, Michaelson J. Occult nipple involvement in breast cancer: clinicopathologic findings in 316 consecutive mastectomy specimens nipple areola skin-sparing mastectomy with immediate transverse rectus abdominis musculocutaneous flap reconstruction is an oncologically safe. *J Clin Oncol* 2011; 27: 4948-4954.
 - 32) Koh J, Park AY, Ko KH, Jung HK. MRI diagnostic features for predicting nipple-areolar-complex involvement in breast cancer. *Eur J Radiol* 2020; 122: 108754.
 - 33) Machida Y, Shimauchi A, Igarashi T, Hoshi K, Fukuma E. Preoperative breast MRI: reproducibility and significance of findings relevant to nipple – areolar complex involvement. *Breast Cancer* 2018; 25: 456-463.
 - 34) Sakamoto N, Tozaki M, Hoshi K, Fukuma E. Is MRI useful for the prediction of nipple involvement? *Breast Cancer* 2013; 20: 316-322.
 - 35) Liao C, Wu Y, Wu W, Chen C, Wu H, Lin Y, Chen S, Chen D, Lee C, Chen S, Kuo S, Lai H. Role of breast magnetic resonance imaging in predicting malignant invasion of the nipple-areolar complex. *Medicine (Baltimore)* 2017; 96: 7170.
 - 36) Zhang H, Li Y, Moran MS, Haffty BG. Predictive factors of nipple involvement in breast cancer : a systematic review and meta-analysis. *Breast Cancer Res Treat* 2015; 151: 239-249.
 - 37) Alperovich M, Choi M, Karp NS, Singh B, Ayo D, Frey JD, Roses DF, Schnabel FR, Axelrod DM, Shapiro RL, Guth AA. Nipple-sparing mastectomy and sub-areolar biopsy: sub-areolar intraoperative frozen section. *Breast J* 2016; 22: 18-23.
 - 38) Jensen JA, Orringer JS, Giuliano AE. Nipple-sparing mastectomy in 99 patients with a mean follow-up of 5 years. *Ann Surg Oncol* 2011; 18: 1665-1670.
 - 39) Luo D, Dip G, Anat S, Ha J, Dip G, Anat S, Latham B, Ingram D, Connell T, Hastrich D, Yeow W, Willsher P, Luo J. The accuracy of intraoperative subareolar frozen section in nipple-sparing mastectomies. *Ochsner J* 2010; 10: 188-192.
 - 40) Petit JY, Veronesi U, Orecchia R, Rey R, Martella S, Didier F, Viale G, Veronesi P, Luini A, Galimberti V, Bedolis R, Rietjens M, Garusi C, De Lorenzi F, Bosco R, Manconi A, Ivaldi GB, Youssef O. Nipple sparing mastectomy with nipple areola intraoperative radiotherapy: one thousand and one cases of a five years experience at the European institu-

- te of oncology of Milan (EIO). *Breast Cancer Res Treat* 2009; 117: 333-338.
- 41) de Alcantara Filho P, Capko D, Barry JM, Morrow M, Pusic A, Sacchini V. Nipple-sparing mastectomy for breast cancer and risk-reducing surgery: the memorial sloan-kettering cancer center experience. *Ann Surg Oncol* 2011; 18: 3117-3122.
- 42) Crowe JP, Patrick RJ, Yetman RJ, Djohan R. Nipple-sparing mastectomy update. *Arch Surg* 2016; 143: 1106-1110.
- 43) Peled AW, Foster RD, Stover AC, Itakura K, Ewing CA, Alvarado M, Hwang ES, Esserman LJ. Outcomes after total skin-sparing mastectomy and immediate reconstruction in 657 breasts. *Ann Surg Oncol* 2012; 19: 3402-3409.
- 44) Spear SL, Rottman SJ, Seiboth LA, Hannan CM. Breast reconstruction using a staged nipple-sparing mastectomy following mastopexy or reduction. *Breast* 2010; 129: 572-581.