

Monteggia fracture associated with ipsilateral intercondylar distal humeral fracture with posterior interosseous nerve palsy: case report, medico-legal implications, and methodological assessment analysis

G. BASILE¹, S. FOZZATO¹, L. BIANCO PREVOT¹, R. ACCETTA¹, A. CICCARELLI², F. FAMILIARI², S. ZAAMI³

¹Department of Trauma Surgery, I.R.C.C.S. Orthopedic Institute Galeazzi, Milan, Italy

²Department of Movement, Human and Health Sciences University of Rome "Foro Italico", Rome, Italy

³Department of Medical and Surgical Sciences, "Magna Graecia" University of Catanzaro, Catanzaro, Italy

⁴Department of Anatomical, Histological, Forensic and Orthopedic Sciences, "Sapienza" University of Rome, Rome, Italy

G. Basile and S. Fozzato contributed equally to this work

Abstract. – BACKGROUND: The Monteggia fracture, defined as a fracture of the proximal third of the ulnar shaft associated with an anterior or posterior dislocation of the proximal radial epiphysis, is a serious injury accounting for 0.7% of all elbow fractures and dislocations in adults. For adult patients, good results can only be obtained through early diagnosis and adequate surgical treatment. Monteggia fracture-dislocations associated with distal humeral fracture are extremely rare injuries in adults and there are few cases described in the literature. Medico-legal implications arising from such conditions have a host of complexities that cannot be discounted.

CASE REPORT: This case report revolves around a patient affected by a type I Monteggia fracture-dislocation, according to the Bado classification, associated with an ipsilateral intercondylar distal humeral fracture. To our knowledge, this combination of lesions has never been reported before in adult patients. A positive result was obtained due to early diagnosis, achievement of anatomical reduction, and optimal stabilization with internal fixation which made it possible to achieve early functional recovery.

CONCLUSIONS: Monteggia fracture-dislocations associated with ipsilateral intercondylar distal humeral fracture are extremely rare in adults. In the case herein reported, a favorable outcome was obtained due to early diagnosis, achievement of anatomical reduction and management with internal fixation with plate and screws, as well as early functional training. Misdiagnosis makes such lesions risky in terms of potentially delayed treatment, increasing the need for surgical interventions and the possibility of high-risk complications

and disabling sequelae, with possible medico-legal implications. In the case of unrecognized injuries under urgent circumstances, the injuries may become chronic, making the treatment more complex. The ultimate outcomes of a misdiagnosed Monteggia lesion can lead to very serious functional and aesthetic damage.

Key Words:

Monteggia, Fracture, Elbow instability, Radial head fracture, Malpractice, Medico-legal implications, Case report.

Introduction

The Monteggia fracture, defined as a fracture of the proximal third of the ulnar shaft associated with an anterior or posterior dislocation of the proximal radial epiphysis, is a serious injury accounting for 0.7% of all elbow fractures and dislocations in adults^{1,2}. In 1967, Bado³ published a first classification of Monteggia fractures-dislocations, dividing them into four different combinations of ulna fracture and radial head dislocation. For adult patients, good results can only be obtained through early diagnosis and adequate surgical treatment. Monteggia fracture-dislocations associated with distal humeral fracture are extremely rare injuries in adults and there are few cases described in the literature^{4,5}.

This case report revolves around a patient affected by a type I Monteggia fracture-dislocation,

according to Bado classification, associated with an ipsilateral intercondylar distal humeral fracture. To our knowledge, this combination of lesions has never been reported before in adult patients.

Case Presentation

A 19-year-old male patient entered the Emergency Department of the I.R.C.C.S. Galeazzi-Sant'Ambrogio (Milan, Italy) after a trauma to the left upper limb during a football match, with impact on the hand with an extended forearm, due to an accidental fall. The patient was in good health, non-smoker, and had already suffered a left radial shaft and a right distal radius fracture.

Following the trauma, he sustained an ipsilateral fracture of the distal intercondylar humerus (AO classification 13-B1) and a Monteggia fracture-dislocation (Bado I type) of the left forearm (Figure 1). On initial clinical examination, a marked weakness of common extensor digitorum and interosseus muscles was detected, with signs consistent with posterior interosseous nerve deficits and ulnar nerve entrapment, however, no wrist extension deficits or peripheral sensory deficits were found.

Open reduction and internal fixation (ORIF) surgery was performed six hours after hospital admission, due to the clinical finding of nerve deficit. In agreement with the anesthetist, general anesthesia without peripheral nerve blocks was chosen to evaluate nerve function in the immediate postoperative period. A posterior surgical approach to the elbow was used for the treatment of the lesions, extending proximally and distally to a total length of 15 cm. Particular attention was paid to the hemostasis of the underlying anatomical planes. For ulnar fracture fixation, a 9-hole straight plate was used in dynamic compression with 3.5 mm diameter screws (Variax®, Stryker Corporation, Kalamazoo, MI, USA). The anatomical reduction of the radial head was then performed, after freeing the capsular-ligament material interposed in the joint cavity which kept the humeral-radial joint dislocated.

For fixation of the distal humerus fracture, the same surgical skin incision was used associated with a bilateral triceps tendon approach to avoid olecranon osteotomy, in light of the already considerable complexity of the fracture pattern. At the humeral level, a posterolateral distal humeral plate with angular stability compression screws (Variax®, Stryker Corporation, Kalamazoo, MI,

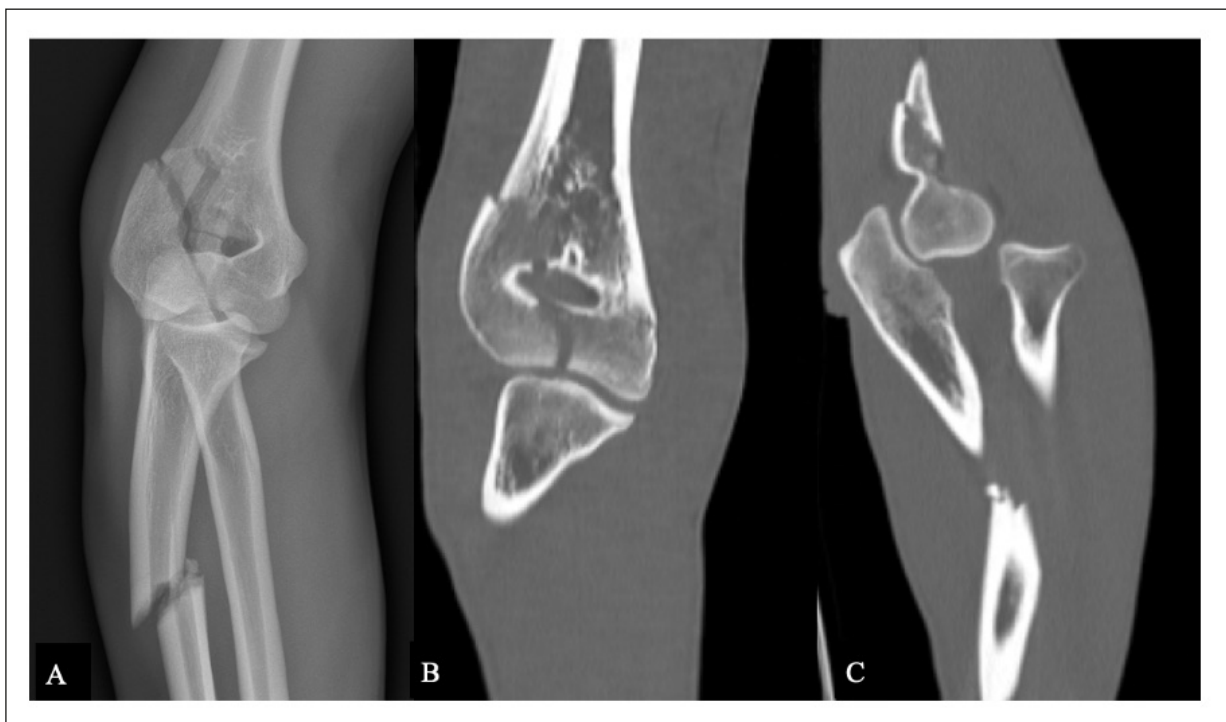


Figure 1. A, Anteroposterior x-ray of the elbow showing the fracture of the proximal third of the ulna and of the humeral blade associated with dislocation of the radial head; (B), CT coronal section showing humeral paddle fracture (AO 13-B1); (C), CT sagittal section showing the fracture of the ulna, the humerus and the anterior dislocation of the radial head.

USA) was used after reducing the articular fragments with a 4 mm diameter partial thread intercondylar screw (ASNIS®, Stryker Corporation, Kalamazoo, MI, USA) (Figure 2).

The radial and ulnar nerves were explored and were not found to be interposed between the fracture fragments. During the reduction and fixation maneuvers, the nerves were protected to prevent possible iatrogenic injuries. At the end of the surgery, a cast with the elbow flexed at 90° was applied.

The postoperative period was regular. There was no postoperative anemia, and the patient was discharged with a hemoglobin value of 14.3 mg/dL, two days after surgery.

Given the condition of the ulnar and posterior interosseous nerve, oral corticosteroids were administered in the postoperative phase (prednisone 25 mg 1 tablet/day for 7 days, then prednisone 12.5 mg 1 tablet/day for 7 days, finally 1/2 cp/die for 7 days) and neurotrophic drugs (acetyl-L-carnitine 500 mg 1 cp x2/die for 15 days) to improve nervous sensitivity. When the sutures were removed, on the fifteenth postoperative day, the protection with the cast was removed and the patient was allowed to start active mobilization in flexion-extension of the elbow.

The follow-up (FU) of the patient's clinical state at discharge was also monitored using telemedicine, through an application on the patient's mobile device enabling direct and continuous communication between the medical staff and the patient, thus permitting personalized treatment, FU optimization and adequate continuity of care⁶.

At 6-weeks FU, the patient did not complain of any symptoms of posterior interosseous nerve or ulnar nerve palsy. The patient had a good elbow range of motion (ROM): 100° flexion, full pronation-supination, and a 30° extension deficit. The obtained Mayo elbow score was 65 points.

In the third postoperative month, complete ROM was achieved by the patient with a Mayo elbow score of 85 points. The informed consent to participate in the study was obtained from the patient, along with his agreement to publish all the necessary information.

Discussion

In this case report, we presented the case of a young patient with an intercondylar distal humeral

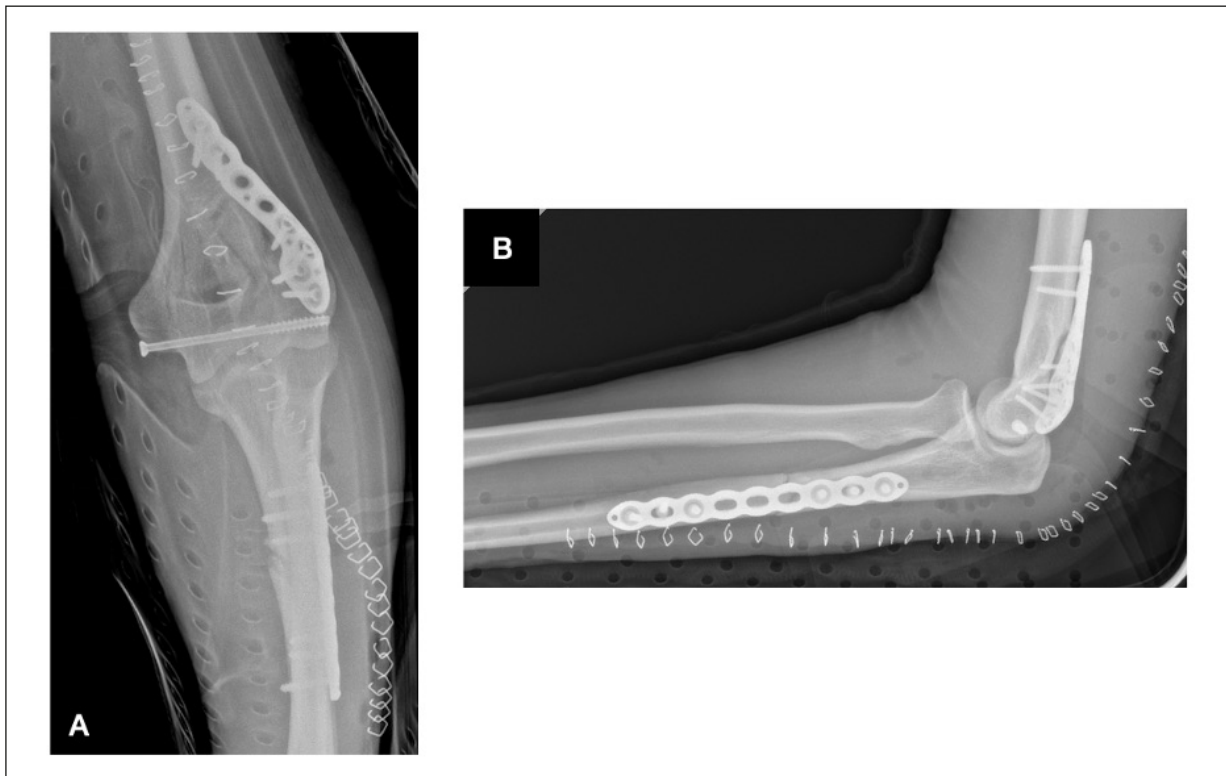


Figure 2. A, Antero-posterior post-operative x-ray; (B), x-ray in lateral projection of the elbow showing the reduction and synthesis of the fractures obtained with the implantation of plates and screws.

fracture AO type 13-B1 associated with an ipsilateral posterior dislocation fracture of Monteggia (Bado type I). The patient also presented an incomplete posterior interosseous nerve palsy and ulnar nerve entrapment. Complete recovery of nerve function was noted at the 6-week FU, while the complete recovery of the ROM was obtained in the third postoperative month. During the surgical approach, the bilateral paratricipital access technique was chosen to avoid a second Chevron osteotomy of the olecranon, which would have exacerbated the fracture of the proximal third of the ulnar shaft. For intercondylar fixation of the distal humerus fracture, a partial thread screw was used to obtain adequate compression of the two articular fragments of the fracture. Although a stable internal synthesis was obtained, a plaster cast was used to facilitate surgical wound healing and for analgesic purposes.

The complex fracture pattern found in this patient represents an uncommon and under-researched variant of the Monteggia fracture-dislocation. The complexity of this injury arises from an inherently unstable fracture pattern associated with a distal humerus fracture that is often associated with a partial or total injury of the ulnar and radial nerves. Such fractures occur more frequently in the pediatric population and rarely in adults. Such fracture dislocations can easily be unnoticed because the radial dislocation can be minimal and hidden by the more obvious ulnar fracture⁷. Thus, in child patients, the diagnosis of Monteggia lesions is more difficult and can be underestimated, resulting in chronic lesions, and disabling sequelae. Between 20% and 50% of Monteggia lesions are reportedly not identified accurately at first diagnosis⁸. This is associated with possible medico-legal repercussions, due to a diagnostic error consisting in the non-identification of a radiographically evident fracture, caused by negligence or inexperience qualified as severe.

The failure to diagnose a fracture constitutes a breach of contract liable to the award of compensatory damages and there are no indications during the visualization of X-ray, which if respected, makes the doctor less punishable in case of no diagnosis (Court of Cassation, Sentence n. 9701 of 2022)⁹.

A missed or delayed diagnosis can cause patient damage or lead to a slow and not entirely effective functional recovery. Consequently, a very high level of suspicion must be maintained. The orthopedic surgeon should always examine the X-rays, even if they have been deemed normal by the radiologist. Positioning of the

affected limb should be carefully evaluated, and additional X-ray should be performed as necessary, particularly when the entire forearm is not visible. A lateral view of the elbow should always be available¹⁰. On elbow X-ray, radial head dislocation can be detected by drawing the radiocapitellar line described by Støren¹¹. This line passes through the neck of the radius on a lateral view and intersects the humeral condyle in the center. It has substantial diagnostic validity, although it may be falsely positive in 9% of cases and subject to physiological variations related to sex and age¹². Another useful radial parameter, visible in the lateral projection of the forearm, is the sign of the ulnar arch described by Lincoln and Mubarak¹³, represented by a slight curvature of the ulnar profile. A further parameter that can be considered is the head-neck relationship on the lateral X-ray, which can be useful to document radial head hypertrophy¹⁴.

In adults these fractures are often the result of high-energy mechanisms and studies¹⁵ have shown that they are easily unnoticed at initial presentation and, if left untreated can cause debilitating loss of ROM. Three different pathological mechanisms have been identified causing Monteggia lesion: (i) direct traumatic force on the posterior aspect of the forearm with direct impact on the ulna which forces the radial head to move anteriorly until dislocation; (ii) fall onto an outstretched arm resulting in forearm overpronation dislocating the radial head followed by fracture of the ulna; (iii) elbow hyperextension with biceps contraction resulting in dislocation of the radial head followed by fracture of the ulna¹⁶.

Adult patients with Monteggia dislocation fractures should always be treated surgically, as nonsurgical treatment is associated with universally worse outcomes¹⁷. The literature shows that the gold standard for treatment is open reduction and plate-and-screw fixation, despite the few cases^{5,18,19} so far documented. Arazi et al⁵ reported the case of a thirteen-year-old girl with a distal humerus fracture associated with Monteggia fracture-dislocation and an ipsilateral radial fracture after a fall⁵. Matta et al¹⁸ described two instances of Monteggia type II fracture-dislocation with concomitant fracture of the distal humerus both treated with open reduction and internal fixation. In both cases, a total recovery of flexion-extension and pronation-supination of the elbow was described at the six-month follow-up¹⁸. Beredjikian et al¹⁹ described two cases of C1 AO distal humerus fractures associated with ipsilateral anterior

Monteggia fracture-dislocations. Also in these two cases, plates and screws were used for the reduction and synthesis of the humeral and ulnar fractures. The results were satisfactory despite the flexion contracture presented in both cases¹⁹.

If the fracture is treated after 3 to 4 weeks, the soft-tissue interposition usually prevents the radial head from returning to its normal position. The medium-long-term prognosis of such chronic injuries can be unfavorable, with possible pain, palpable swelling, joint limitation, instability, progressive valgus deformity, ulnar neuropathy, and post-traumatic arthrosis²⁰. In these cases, is difficult to propose complex surgical treatments, with complications and uncertain results, to prevent possible progressive clinical worsening. Some authors²¹ propose to postpone corrective treatments, with the possibility of performing capitullectomy only in severely symptomatic cases. However, it is difficult to establish the timing to outline a corrective surgical treatment, since the result is conditioned by the patient's age, the time passed since the trauma, and the onset of joint deformities²².

From a medico-legal point of view, it has been highlighted that the fracture healing process is correlated to its correct classification and surgical treatment, and a possible consolidation failure could arise from technical errors in the surgical procedure, as is the case with other conditions as well²³. This may be related to significant worsening of the impairment related to the skeletal injury and its surgical treatment, susceptible to compensation in the civil law field²⁴.

In the case herein reported, a favorable outcome was obtained due to early diagnosis, achievement of anatomical reduction and management with internal fixation with plate and screws, as well as early functional training.

In order to improve and speed up the recovery of the nervous deficit, the patient was treated with the administration of cortisone and a neurotrophic drug (L-acetyl carnitine). However, there is no evidence in the literature of how pharmacological therapies improve the outcome of patients with nervous impairment²⁵.

Conclusions

We believe that early identification of these lesions is critical to improving patient prognosis. The distinct possibility of missing the correct initial diagnostic classification makes such lesions risky in terms of potentially delayed treatment, need for surgical

interventions and a high risk of complications and disabling sequelae, with possible medico-legal implications. In the case of unrecognized injuries under urgent circumstances, the injuries may become chronic, making the treatment more complex.

Therefore, we recommend a correct emergency diagnosis with radiographs of the forearm in toto in standard and oblique projections, possibly completed by a CT examination for a better study of the fracture fragments. Instead, MRI may reveal proximal or distal radioulnar and/or interosseous membrane lesions. A factor that we consider substantially important for a favorable outcome is undoubtedly intense and gradual physiotherapy, which must be started as early as possible and continued until a satisfactory functional recovery is achieved.

Authors' Contributions

Conceptualization, SF, L.B.P, F.F., R.A., S.Z. and G.B.; methodology, G.B., S.F.; validation, G.B., S.F., A.C, F.F., R.A., S.Z. and L.B.P; investigation, G.B., S.F., L.B.P, A.C and R.A.; data curation, G.B., S.F. and R.A.; writing-original draft preparation, S.F., G.B. and L.B.P.; writing-review and editing, G.B., S.F. and S.Z.; visualization, G.B., S.F., F.F. and R.A.; supervision, G.B., S.Z. and S.F. All authors have read and agreed to the published version of the manuscript.

Conflict of Interest

The Authors declare that they have no conflict of interest.

Ethics Approval

This study did not require the approval of the ethics committee and did not entail any damage to the rights, safety, and health of the people involved. This study has pursued as its primary objective, above all others, the well-being of the patient involved.

Informed Consent

The informed consent to participate in the study was obtained from the patient, along with his agreement to publish all the necessary information and data.

Funding

This research received no external funding.

Data Availability

The data presented in this case report are available on request from the corresponding author.

CARE Checklist Statement

The manuscript was prepared and revised according to the CARE Checklist (2016).

ORCID ID

G. Basile: 0000-0001-9602-4223
 S. Fozzato: 0000-0002-6368-2614
 L. Bianco Prevot: 0000-0002-9093-630
 R. Accetta: 0009-0002-7924-4405
 F. Familiari: 0000-0002-3453-2043
 S. Zaami: 0000-0001-5741-7139
 A. Ciccarelli: 0009-0008-6556-8437

References

- 1) Trillat A, Marsan C, Lapeyre B. Classification et traitement des fractures de Monteggia. A propos de 36 observations [Classification and treatment of Monteggia fractures. Apropos of 36 cases]. *Rev Chir Orthop Reparatrice Appar Mot* 1969; 55: 639-657.
- 2) Suarez R, Barquet A, Fresco R. Epidemiology and treatment of Monteggia lesion in adults: series of 44 cases. *Acta Ortop Bras* 2016; 24: 48-51.
- 3) Rehim SA, Maynard MA, Sebastin SJ, Chung KC. Monteggia fracture dislocations: a historical review. *J Hand Surg Am* 2014; 39: 1384-1394.
- 4) Wang YH, Han QL, Tao R, Sun FR. Ipsilateral intercondylar distal humeral fracture and Bado type II Monteggia lesion in an adult: a case report. *Orthop Surg* 2010; 2: 161-164.
- 5) Arazi M, Oğün TC, Kapicioğlu MI. The Monteggia lesion and ipsilateral supracondylar humerus and distal radius fractures. *J Orthop Trauma* 1999; 13: 60-63.
- 6) Basile G, Accetta R, Marinelli S, D'Ambrosi R, Petrucci QA, Giorgetti A, Nuara A, Zaami S, Fozzato S. Traumatology: Adoption of the Sm@rtEven Application for the Remote Evaluation of Patients and Possible Medico-Legal Implications. *J Clin Med* 2022; 11: 3644.
- 7) Cohen A, Talwar C, Magnani J, Wahhab J. Adult Bado type I Monteggia fracture dislocation: A case report. *Trauma Case Rep* 2021; 36: 100541.
- 8) Dormans JP, Rang M. The problem of Monteggia fracture-dislocations in children. *Orthop Clin North Am* 1990; 21: 251-256.
- 9) Busardò FP, Frati P, Santurro A, Zaami S, Fineschi V. Errors and malpractice lawsuits in radiology: what the radiologist needs to know. *Radiol Med* 2015; 120: 779-784.
- 10) Gallone G, Trisolino G, Di Gennaro GT, Antonioni D, Stilli S. Classificazione, inquadramento diagnostico e trattamento della lesione di Monteggia in età pediatrica. *Lo Scalpello* 2018; 32: 262-270.
- 11) Storen G. Traumatic dislocation of the radial head as an isolated lesion in children; report of one case with special regard to roentgen diagnosis. *Acta Chir Scand* 1959; 116: 144-147.
- 12) Souder CD, Roocroft JH, Edmonds EW. Significance of the Lateral Humeral Line for Evaluating Radiocapitellar Alignment in Children. *J Pediatr Orthop* 2017; 37: 150-155.
- 13) Lincoln TL, Mubarak SJ. "Isolated" traumatic radial-head dislocation. *J Pediatr Orthop* 1994; 14: 454-457.
- 14) Kim HT, Conjares JN, Suh JT, Yoo CI. Chronic radial head dislocation in children, Part 1: pathologic changes preventing stable reduction and surgical correction. *J Pediatr Orthop* 2002; 22: 583-590.
- 15) Egol KA, Tejwani NC, Bazzi J, Susarla A, Koval KJ. Does a Monteggia variant lesion result in a poor functional outcome?: A retrospective study. *Clin Orthop Relat Res* 2005; 438: 233-238.
- 16) Kim JM, London DA. Complex Monteggia Fractures in the Adult Cohort: Injury and Management. *J Am Acad Orthop Surg* 2020; 28: 839-848.
- 17) Wong JC, Getz CL, Abboud JA. Adult Monteggia and Olecranon Fracture Dislocations of the Elbow. *Hand Clin* 2015; 31: 565-580.
- 18) Matta JF, El Rassi GS, Abd El Nour HG, El Asmar R. Uncommon Variant of Type II Monteggia Fracture with Concomitant Distal Humeral Fracture. *Case Rep Orthop* 2015; 2015: 374673.
- 19) Beredjikian PK, Bozentka DJ, Ramsey ML. Ipsilateral intercondylar distal humerus fracture and Monteggia fracture-dislocation in adults. *J Orthop Trauma* 2002; 16: 438-440.
- 20) Fabricant PD, Baldwin KD. Missed Pediatric Monteggia Fracture: A 63-Year Follow-Up. *J Pediatr* 2015; 167: 495.
- 21) Kalamchi A. Monteggia fracture-dislocation in children. Late treatment in two cases. *J Bone Joint Surg Am* 1986; 68: 615-619.
- 22) Horii E, Nakamura R, Koh S, Inagaki H, Yajima H, Nakao E. Surgical treatment for chronic radial head dislocation. *J Bone Joint Surg Am* 2002; 84: 1183-1188.
- 23) Basile G, Fozzato S, Petrucci QA, Gallina M, Bianco Prevot L, Accetta R, Zaami S. Treatment of Femoral Shaft Pseudarthrosis, Case Series and Medico-Legal Implications. *J Clin Med* 2022; 11: 7407.
- 24) Basile G, Avato FM, Passeri A, Accetta R, Amadei F, Giorgetti A, Castoldi D, Fozzato S. Atrophic pseudarthrosis of humeral diaphyseal fractures: medico-legal implications and methodological analysis of the evaluation. *Acta Biomed* 2022; 93: 2022176.
- 25) Bhatia A, Flamer D, Shah PS. Perineural steroids for trauma and compression-related peripheral neuropathic pain: a systematic review and meta-analysis. *Can J Anesth* 2015; 62: 650-662.