

Does laparoscopic-guided transversus abdominis plane block have an effect on postoperative pain and recovery after sleeve gastrectomy?

G. OKUT¹, E. TURGUT², K. KAPLAN³, Y.M. BAG⁴, S. AKBAS⁵,
F. SUMER⁶, C. KAYAALP⁷

¹Gastroenterology Surgery Department, Bozyaka Research and Training Hospital, Izmir, Turkey

²Gastroenterology Surgery Department, Tepecik Research and Training Hospital, Izmir, Turkey

³Gastroenterology Surgery Department, Adana City Hospital, Adana, Turkey

⁴Gastroenterology Surgery Department, Van Research and Training Hospital, Van, Turkey

⁵Anesthesiology and Reanimation Department, Inonu University Turgut Ozal Medical Center, Malatya, Turkey

⁶Gastroenterology Surgery Department, Irmek International Hospital, Tekirdag, Turkey

⁷Gastroenterology Surgery Department, Yeditepe University, Istanbul, Turkey

Abstract. – **OBJECTIVE:** Postoperative pain management is thought to have an effect on patient comfort, morbidity, and mortality after bariatric surgery. Local anesthetic agents are frequently used for this purpose. Local anesthetics can be used in many different ways. In this study, we aimed to investigate the effect of transversus abdominis plane (TAP) block on postoperative pain by laparoscopic method.

PATIENTS AND METHODS: A prospective randomized clinical trial was performed. While TAP block was applied to one group with bupivacaine, no action was taken for the other group. Postoperative analgesia was given to both patient groups with the “patient-controlled analgesia (PCA)” device. Demographic, operational, and postoperative clinical and pain data of the patients were recorded.

RESULTS: TAP block and non-TAP block groups consisted of 30 patients each. Visual analog scale (VAS) scores of the patients at 6, 12, and 24 hours were lower in the TAP group compared to the non-TAP group ($p=0.015$, 0.018 , 0.04 , respectively). According to the PCA device data, the analgesic requirement was lower in the TAP group at 6, 12, and 24 hours ($p<0.001$). Rescue analgesia was required more in the non-TAP group ($p=0.04$). There was no statistically significant difference between the two groups in terms of gas discharge time ($p=0.102$), stool discharge occurred earlier in the TAP group ($p=0.02$). Oral intake times ($p=0.554$) and length of stay hospital ($p=0.551$) were similar.

CONCLUSIONS: Laparoscopic TAP block using bupivacaine can be safely administered in morbidly obese patients and reduces postoperative analgesic requirements. Thus, side effects that may develop secondary to the use of analgesics are avoided.

Key Words:

Sleeve gastrectomy, TAP block, Bupivacaine.

Introduction

Obesity is one of the most important health problems in the world and causes serious morbidity and mortality due to its comorbidities. Bariatric surgery effectively achieves and maintains weight loss and reduces obesity-related comorbidities¹. Even if this surgical procedure is performed with a minimally invasive approach, patients suffer from moderate to severe pain that begins immediately after surgery². Pain can lead to cardiovascular, thromboembolic, and pulmonary complications by preventing cough and ambulation in the postoperative period. Patients with obesity are at higher risk for these complications and therefore mortality risk is higher³. Effective postoperative pain management is crucial to promoting early ambulation and deep breathing, which are known to reduce the risk of complications. Multimodal analgesia has been advocated by many authors as part of Enhanced Recovery After Surgery (ERAS) programs to reduce the incidence and severity of postoperative pain. Multimodal analgesia involves the use of two or more drugs with different mechanisms of action to maximize analgesic efficacy while reducing the risk and severity of side effects⁴. Achieving adequate analgesia, especially the wise administration of opiates, can be a double-edged sword.

Opiates provide a large part of the postoperative pain regimen necessary for early ambulation and adequate ventilation but have many side effects. Increased opiate use is associated with increased rates of delirium, ileus, urinary retention, and respiratory depression, and may have strong addictive potential. An opioid-induced cardiopulmonary arrest usually occurs within the first 24 hours of surgery⁵. Therefore, the transverse abdominis plane (TAP) block is attractive as it can reduce postoperative pain, nausea, and vomiting in addition to reducing the amount of opioid consumption⁶. The TAP block is a regional anesthesia technique that targets the sensory nerve supply of the anterior-lateral abdominal wall. Using the Petit triangle as a landmark, it is performed by injecting a local anesthetic into the plane between the internal oblique and transverse abdominis muscles. This TAP plane is infiltrated with local anesthetics to target the T7-T12 intercostal nerves, ilioinguinal, iliohypogastric, and lateral cutaneous branches of the dorsal rami of L1-L3^{7,8}. This study was designed to test the hypothesis that laparoscopic guided TAP block using bupivacaine reduced postoperative analgesic use, postoperative pain, and hospital stay.

Patients and Methods

A prospective, randomized, double-blind clinical study of patients undergoing sleeve gastrectomy (SG) in a single institution was conducted between April 2019 and June 2020.

Approval was obtained from the Inonu University Faculty of Medicine ethics committee of our center for a prospective study. Inclusion criteria were body mass index (BMI) > 40 kg/m² or obesity-related comorbidities and BMI > 35 kg/m².

Exclusion criteria: with other bariatric techniques, severe underlying cardiovascular disease, chronic renal failure or liver dysfunction, previous upper abdominal surgery, recent opiate use, history of chronic pain or using gabapentin, BMI > 55 kg/m², American Society of Anesthesiologists class IV were patients with psychiatric disorders, pregnant, breastfeeding or a history of seizures, and complicated during the laparoscopic procedure. Patients with postoperative complications (2 patients with TAP block and 2 patients without TAP block were excluded from the study) were not included in the analysis (TAP block procedure could not be evaluated objectively because postoperative leakage and bleeding affected the pain

scale of the patients). Patients were randomized into two groups using a simple 1:1 randomization scheme: with a TAP block (TAP group) and no TAP block (non-TAP group).

Data collected include age, gender, BMI, comorbidity status, subjective pain assessment using the visual analgesic scale (VAS) (at postoperative 6, 12, 24 hours), Patient Controlled Analgesia (PCA) device data (at postoperative 6, 12, 24 hours), postoperative rescue analgesic requirement, postoperative antiemetic use, and length of hospital stay (LosHos). Pain assessment in the first 24 hours was evaluated by a nurse who was unaware of the TAP block status.

Bupivacaine was used as a local anesthetic. A Petit triangle was preferred as the injection area. For bupivacaine administration, a Veress needle was used to access the preperitoneal space directly under laparoscopic visualization after the camera port was inserted. 20 ml of 5% bupivacaine, diluted with 30 ml of saline, was injected bilaterally in equal amounts into the plane between the internal oblique and transverse abdominis muscles. Laparoscopic guidance consists of inserting the needle on both sides until the tip protrudes into the peritoneal layer (Figure 1). The needle is then retracted by 3 mm, the estimated thickness of the preperitoneal space and the transversus abdominis muscle so that the anesthetic drug can be introduced into the space between the internal oblique muscle and the transversus abdominis muscle. It is injected until a swelling occurs on the peritoneum (Figure 2).

Paracetamol 1000 mg/8 hours was given intravenously to both groups. At the same time, analgesic treatment was given to both groups with the PCA device in the first 24 hours postoperatively. The PCA device was set to infuse 25 mg of tramadol as a bolus injection, with a lockout time of 20 minutes.

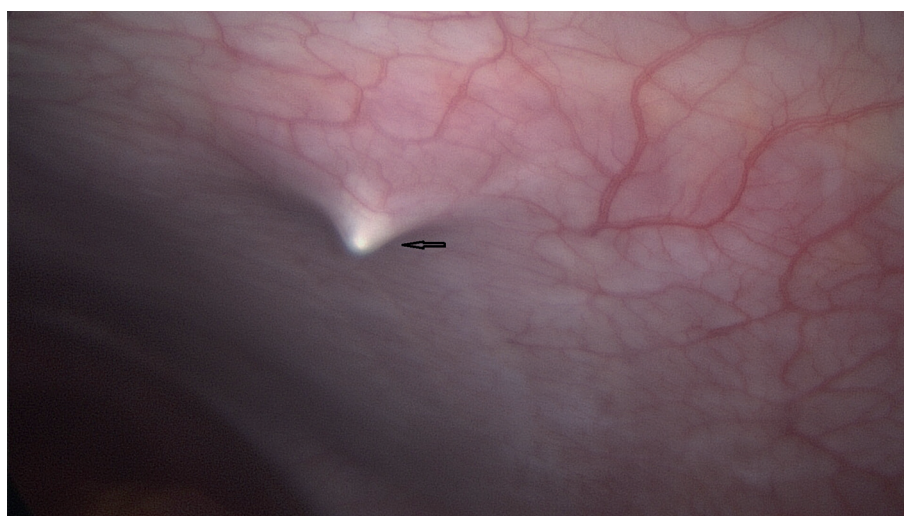
Statistical Analysis

All statistical analyzes were performed using SPSS software version 22 for Windows (SPSS Corp., Armonk, NY, USA) and the results were considered statistically significant if $p < 0.05$. Shapiro-Wilk test was used in the distribution analysis of numerical variables. Continuous variables were expressed as median (range) and categorical variables were expressed as frequency (percentage). Mann-Whitney U and Student *t*-test were used to analyze numerical data. Nominal variables are expressed as percentages and frequency. Chi-square or Fischer's

Table I. Preoperative patient data.

	TAP block group	Non-TAP block group	<i>p</i>
Age (year)	34.9±11.67	32.4±8.63	0.446
Gender (Female)	16	16	1
BMI (kg/m ²)	42.05 (37.6-55)	42.9 (37.7-54.9)	0.645
Obesity related comorbidities (n)	3	5	0.695
Prior abdominal operation (n)	3	5	0.729
Drain (n)	1	1	1

TAP: Transversus abdominis plane, BMI: Body mass index. Obesity related comorbidities: Diabetes mellitus, hypertension, cardiac disease, chronic obstructive pulmonary disease, goiter.

**Figure 1.** Laparoscopic guidance consists of inserting the needle on both sides until the tip protrudes in the peritoneal layer.

exact test was used in the analysis of nominal variables.

Results

During the study period, 60 patients met the inclusion criteria. Patients in both the non-TAP and TAP block groups had similar age, gender, comorbidity, prior abdominal operation, ASA, and BMI (Table I). VAS scores of the patients at 6, 12, and 24 hours were lower in the TAP group

compared to the non-TAP group ($p=0.015$, 0.018 , 0.04 , respectively). According to the PCA device data, the analgesic requirement was lower in the TAP group at 6, 12, and 24 hours ($p<0.001$). Rescue analgesia was required more in the non-TAP group ($p=0.04$) (Table II). While there was no statistically significant difference between the two groups in terms of gas discharge time ($p=0.102$), stool discharge occurred earlier in the TAP group ($p=0.02$) (Table III). There was no significant difference between oral intake times ($p=0.554$), nausea/vomiting ($p=0.883$), and LosHos ($p=0.551$)

Table II. VAS scores and rescue analgesic requirement.

	TAP block group	Non-TAP block group	<i>p</i>
6 hour VAS	3 (2-8)	5 (2-8)	0.015
12 hour VAS	3 (2-4)	4 (2-7)	0.018
24 hour VAS	2 (1-5)	4 (2-6)	0.004

TAP: Transversus abdominis plane, VAS: visual analog scale.

Table III. Time to first flatus and defecation.

	TAP block group	Non-TAP block group	<i>p</i>
Flatus (day)	2 (1-2)	2 (1-3)	0.102
Defecation (day)	2 (2-3)	3 (2-5)	0.020

TAP: Transversus abdominis plane.

Table IV. First oral intake time and length of stay in the hospital time for each group.

	TAP block group	Non-TAP block group	<i>p</i>
12-24 hours	11	13	0.554
24-36 hours	8	7	
> 36 hours	1		
LosHos (day)	3 (3-6)	3 (3-7)	0.551

LosHos: Length of hospital stay, TAP: Transversus abdominis plane.

(Table IV). TAP block-related complications were not observed in any of the patients.

Discussion

This study aims to investigate the effect of laparoscopy-assisted TAP block using bupivacaine on outcomes in patients who underwent sleeve gastrectomy. Postoperative rescue analgesic requirement was significantly higher in the non-TAP group. VAS scores were statistically signifi-

cantly lower in patients in the TAP block group at 6, 12, and 24 hours postoperatively.

There are three components of postoperative pain after bariatric surgery: parietal pain due to abdominal wall damage during trocar insertion, visceral pain due to irritation of the gastrointestinal serosa, and pain in the left shoulder caused by the pneumoperitoneum irritating the diaphragmatic muscles. After laparoscopic surgery, 50-70% of total pain is parietal pain, 10-20% is visceral pain and 20-30% is pain due to pneumoperitoneum⁹. In patients who have undergone bariatric surgery, the effect of the analgesic substance

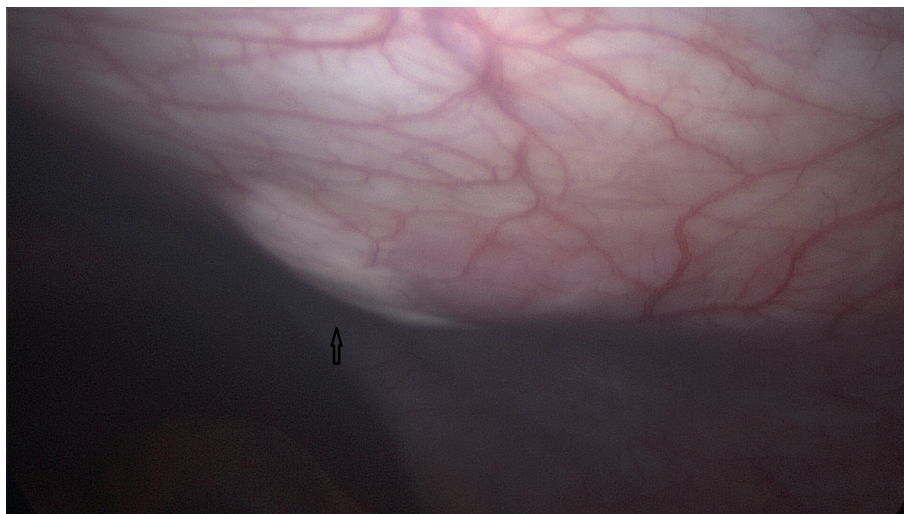


Figure 2. Analgesic drug is injected until a swelling occurs on the peritoneum.

applied to the anterior abdominal wall is mainly local, nerve conduction is blocked by reducing the sodium permeability of the neuronal membrane with direct contact with the drug¹⁰.

Many scholars¹¹ have shown that TAP block is a safe and effective component of postoperative pain control, extends the time to the first opioid request, and reduces general opioid consumption.

In the patient obesity group, the main problem in the injection of anesthetic drugs into the subaponeurotic region is the blind injection due to the thick area that the needle passes through. Some authors¹² advocate that ultrasound-guided anesthetic infiltration may be beneficial in the injection procedure since it allows the identification of abdominal wall layers in patients with obesity. However, due to the deep anatomical location of the structures and nerves, ultrasonographic waves travel a greater distance. It is a factor that decreases the sensitivity of ultrasonography. We decided to do this with laparoscopic guidance. Indeed, laparoscopic guidance is not as precise as ultrasound guidance, as the muscle layers cannot be revealed. After seeing the protrusion of the needle over the peritoneum, we retract 3 mm depending on the estimated thickness of the transversus abdominis muscle and the preperitoneal space.

In our study, the TAP block and non-TAP groups were evaluated in terms of analgesic use (standardized with a PCA device) and VAS scores at the postoperative 6th, 12th, and 24th hours. Results were obtained in favor of the TAP block group. One of the important points in our study is that PCA devices containing equal amounts of analgesics and infusing equal doses were used to compare the use of analgesics in both patient groups.

Saber et al¹³ found that in study groups of 90 patients, TAP block status did not significantly affect postoperative analgesia requirements, nausea/vomiting scores, mobilization time, duration of hospital stay, or time to return to work after discharge. Wassef et al¹⁴ conducted a prospective randomized control study to investigate the effect of an ultrasound-guided TAP block. Although the pain scores of the patients decreased significantly in the first 12 hours, there was no difference in opioid use. In addition to studies that argue that TAP block is not beneficial, there are also studies supporting the effectiveness of TAP block in the literature. Sinha et al¹² demonstrated in the article they published that after TAP block, patients had lower pain scores and fewer analgesic requirements in the first 24 hours. In addition,

Moon et al's¹⁵ study involving 191 patients who underwent bariatric surgery showed that patients who underwent TAP block used fewer postoperative analgesics. The inclusion of more than one bariatric procedure in this study can be criticized. We think that different procedures may make a difference between patients in terms of analgesic requirements.

Mittal et al¹⁶ conducted a prospective randomized control study to investigate the efficacy of ultrasound-guided TAP block in patients undergoing laparoscopic sleeve gastrectomy. Patients who underwent TAP block had lower pain scores in the first 48 hours and required less total rescue analgesia.

TAP block can be done by two different methods: ultrasonography and laparoscopic guidance. In the first of the studies comparing both methods, Ravichandran et al¹⁷ demonstrated that every good method is equally effective. In a study conducted on a group of pediatric patients, it was shown that both methods are equivalent in terms of analgesic control¹⁸. On the other hand, both studies^{17,18} stated that patients would receive less general anesthesia due to the faster laparoscopic TAP block. The absence of an ultrasonography device and radiologist/anesthesiologist makes the laparoscopic method advantageous for surgeons.

Differences have also been described in the literature in terms of the infiltration site of the anesthetic drug. Omar and Abualsel¹⁸ compared the effects of liposomal bupivacaine (LB) and saline on postoperative pain in 100 patients' bariatric surgery studies. However, the anesthetic was infiltrated into the intraperitoneal space. They found that there was no difference in pain scores at the 24th and 48th hours, but that there was a significant decrease in the use of opioid PCA¹⁸. Trocar site infiltration of local anesthetic has been defined as the other pain relief method. It is highly preferred because of its low cost, ease, and safety. Despite this, there is some controversy about its analgesic efficacy. In addition to those claiming to provide excellent postoperative analgesia, some authors argue that it is ineffective^{19,20}.

Ruiz-Tovar et al¹⁹ conducted a prospective randomized control study comparing laparoscopic TAP block with trocar site infiltration in patients undergoing laparoscopic gastric bypass. Patients in the TAP group had significantly lower pain scores and analgesic requirements in the first 24 hours.

Another important point of "TAP block" is the type of anesthetic used. Two local anesthet-

ics stand out in this regard: bupivacaine and liposomal bupivacaine. Sinha et al¹² and Saber et al¹³ used bupivacaine in their study and achieved the lowest analgesia requirement, especially in the 1st and 3rd hours. Studies using liposomal bupivacaine have shown that longer-term analgesia is provided^{21,22}. In a study²³ comparing bupivacaine and liposomal bupivacaine, it was suggested that the analgesic effect and duration of both anesthetic agents were similar.

In our study, no statistically significant difference was found between the TAP block and non-TAP block groups in terms of nausea and vomiting. Bhakta et al²² found that patients who underwent TAP block with liposomal bupivacaine required more antiemetics within the first 24 hours after surgery, but this finding was not significant during the entire hospital stay. Increased nausea in the first 24 hours can be considered as a side effect of liposomal bupivacaine that can be seen in 40% of patients^{24,25}.

One of the advantages of our study was that all patients were given analgesics with the PCA device, so the statistical comparison between the two groups was significant. If both groups did not have a PCA device, they might have been less likely to request analgesics, as patients were informed that the TAP block was performed for pain control. Similarly, the nursing staff did not know which patient had a TAP block, so they were less likely to offer or encourage opioids.

Limitations

One of the limitations of laparoscopic TAP block processing is that it depends on the surgeon. In addition, until the learning curve is completed, it may be necessary to confirm the tap block-infiltration space with ultrasonography. Quantitative determination of the duration of the TAP block application could have been valuable for our study, but we can say that it did not take longer than 3 minutes (performed by the same team).

Another limitation is that needle placement sites are empirical in terms of dermatomes and may lead to differences in results. The dermatome is mainly an area of skin innervated by a single spinal nerve. The exact location of dermatomes varies between patients.

Conclusions

Our study supports that laparoscopic TAP block using bupivacaine reduces postoperative

analgesic requirements. More studies are needed to determine whether this reduced opioid use translates into improved patient outcomes, including reduced nausea and vomiting, shorter duration of stay, increased patient satisfaction, and decreased opioid use after discharge.

Conflicts of Interest

The authors declare no conflicts of interest.

Funding Sources

This research received no external funding.

Authors' Contribution

Study concept and design: G.O., E.T., S.A.; statistical analysis: Y.M.B, K.K., G.O.; analysis and interpretation of data: E.T, K.K, F.S.; drafting of the manuscript: G.O., C.K., S.A.; critical revision of the manuscript for important intellectual content: C.K., F.S, G.O. All authors commented on previous versions of the manuscript. All authors read and approved the final manuscript.

Acknowledgments

Inonu University Faculty of Medicine ethics committee approval was obtained with the decision numbered 2021/1734.

Informed Consent

Informed written consent was obtained from all patients for the surgical procedures.

References

- 1) Lombardo V, Baratta R, Giannone G. Laparoscopic sleeve gastrectomy for morbid obesity. Our initial experience. *Ann Ital Chir* 2010; 81: 17-20.
- 2) Weingarten TN, Sprung J, Flores A, Baena AMO, Schroeder DR, Warner DO. Opioid requirements after laparoscopic bariatric surgery. *Obes Surg* 2011; 21: 1407-1412.
- 3) Holländer SW, Siftt A, Hess S, Klingen HJ, Djalali P, Birk D. Identifying the bariatric patient at risk for pulmonary embolism: prospective clinical trial using duplex sonography and blood screening. *Obes Surg* 2015; 25: 2011-2017.
- 4) Grieco M, Pernazza G, Gasparrini M, Marino P, Apponi F, Persiani R, Brescia A. The "Lazio Network" experience. The first Italian regional

- research group on the Enhanced Recovery After Surgery (ERAS) program. A collective database with 1200 patients in 2016-2017. *Ann Ital Chir* 2019; 90: 157-161.
- 5) Hah JM, Bateman BT, Ratliff J, Curtin C, Sun E. Chronic opioid use after surgery: implications for perioperative management in the face of the opioid epidemic. *Anesth Analg* 2017; 125: 1733.
 - 6) Ganapathy S, Sondekoppam RV, Terlecki M, Brookes J, Adhikary SD, Subramanian L. Comparison of efficacy and safety of lateral-to-medial continuous transversus abdominis plane block with thoracic epidural analgesia in patients undergoing abdominal surgery: a randomised, open-label feasibility study. *Eur J Anaesthesiol* 2015; 32: 797-804.
 - 7) McDonnell JG, O'Donnell BD, Farrell T, Gough N, Tuite D, Power C, Laffey JG. Transversus abdominis plane block: a cadaveric and radiological evaluation. *Reg Anesth Pain Med* 2007; 32: 399-404.
 - 8) El-Dawlatly AA, Turkistani A, Kettner SC, Machata AM, Delvi MB, Thallaj A, Kapral S, Marhofer P. Ultrasound-guided transversus abdominis plane block: description of a new technique and comparison with conventional systemic analgesia during laparoscopic cholecystectomy. *Br J Anaesth* 2009; 102: 763-767.
 - 9) Mouton WG, Bessell JR, Otten KT, Maddern GJ. Pain after laparoscopy. *Surg Endosc* 1999; 13: 445-448.
 - 10) Moncada R, Martinaitis L, Landecho M, Rotellar F, Sanchez-Justicia C, Bellver M, de la Higuera M, Silva C, Osés B, Martín E, Pérez S, Hernandez-Lizoain JL, Frühbeck G, Valentí V. Does preincisional infiltration with bupivacaine reduce postoperative pain in laparoscopic bariatric surgery? *Obes Surg* 2016; 26: 282-288.
 - 11) Ma N, Duncan JK, Scarfe AJ, Schuhmann S, Cameron AL. Clinical safety and effectiveness of transversus abdominis plane (TAP) block in post-operative analgesia: a systematic review and meta-analysis. *J Anesth* 2017; 31: 432-452.
 - 12) Sinha A, Jayaraman L, Punhani D. Efficacy of ultrasound-guided transversus abdominis plane block after laparoscopic bariatric surgery: a double blind, randomized, controlled study. *Obes Surg* 2013; 23: 548-553.
 - 13) Saber AA, Lee YC, Chandrasekaran A, Olivia N, Asarian A, Al-Ayoubi S, DiGregorio R. Efficacy of transversus abdominis plane (TAP) block in pain management after laparoscopic sleeve gastrectomy (LSG): a double-blind randomized controlled trial. *Am J Surg* 2019; 217: 126-132.
 - 14) Wassef M, Lee DY, Levine JL, Ross RE, Guend H, Vandepitte C, Hadzic A, Teixeira J. Feasibility and analgesic efficacy of the transversus abdominis plane block after single-port laparoscopy in patients having bariatric surgery. *J Pain Res* 2013; 6: 837.
 - 15) Moon RC, Lastrapes L, Wier J, Nakajima M, Gaskins W, Teixeira AF, Jawad MA. Preoperative Transversus abdominis plane (TAP) block with liposomal bupivacaine for bariatric patients to reduce the use of opioid analgesics. *Obes Surg* 2019; 29: 1099-1104.
 - 16) Mittal T, Dey A, Siddhartha R, Nali A, Sharma B, Malik V. Efficacy of ultrasound-guided transversus abdominis plane (TAP) block for postoperative analgesia in laparoscopic gastric resection: a randomized single blinded case control study. *Surg Endosc* 2018; 32: 4985-4989.
 - 17) Ravichandran NT, Sistla SC, Kundra P, Ali SM, Dhanapal B, Galidevara I. Laparoscopic-assisted Transversus Abdominis Plane (TAP) Block Versus Ultrasonography-guided Transversus Abdominis Plane Block in Postlaparoscopic Cholecystectomy Pain Relief: Randomized Controlled Trial. *Surg Laparosc Endosc Percutan Tech* 2017; 27: 228-232.
 - 18) Diyaolu M, Taylor J, Austin J, Gibson M, Ramamurthi RJ, Tsui B, Chao S. Laparoscopic versus ultrasound-guided visualization of transversus abdominis plane blocks. *J Pediatr Surg* 2021; 56: 1190-1195.
 - 19) Omar I, Abualseel A. Efficacy of intraperitoneal instillation of bupivacaine after bariatric surgery: randomized controlled trial. *Obes Surg* 2019; 29: 1735-1741.
 - 20) Ruiz-Tovar J, Garcia A, Ferrigni C, Gonzalez J, Levano-Linares C, Jimenez-Fuertes M, Llaverro C, Duran M. Laparoscopic-guided transversus abdominis plane (TAP) block as part of multimodal analgesia in laparoscopic Roux-en-Y gastric bypass within an enhanced recovery after surgery (ERAS) program: a prospective randomized clinical trial. *Obes Surg* 2018; 28: 3374-3379.
 - 21) Tam T, Harkins G, Wegrzyniak L, Ehrgood S, Kunselman A, Davies M. Infiltration of bupivacaine local anesthetic to trocar insertion sites after laparoscopy: a randomized, double-blind, stratified, and controlled trial. *J Minim Invasive Gynecol* 2014; 21: 1015-1021.
 - 22) Bhakta A, Glotzer O, Ata A, Tafen M, Stain SC, Singh PT. Analgesic efficacy of laparoscopic-guided transverse abdominis plane block using liposomal bupivacaine in bariatric surgery. *Am J Surg* 2018; 215: 643-646.
 - 23) Wong KA, Cabrera AG, Argiroff AL, Pechman DM, Parides MK, Vazzana JT, Moran-Atkin EM, Choi JJ, Camacho DR. Transversus abdominis plane block with liposomal bupivacaine and its effect on opiate use after weight loss surgery: a randomized controlled trial. *Surg Obes Relat Dis* 2020; 16: 886-893.
 - 24) Said AM, Balamoun HA. Continuous transversus abdominis plane blocks via laparoscopically placed catheters for bariatric surgery. *Obes Surg* 2017; 27: 2575-2582.
 - 25) Candiotti K. Liposomal bupivacaine: an innovative nonopioid local analgesic for the management of postsurgical pain. *Pharmacotherapy* 2012; 32: 19S-26S.