

A double communication branch between musculocutaneous and median nerves: first case report, anatomical study, and comprehensive review of clinical implications

C. FUMO^{1,2}, L. MARZELLA³, A. LAZZERINI³, F. DE FRANCESCO⁴, R. DE VITIS^{1,2}

¹Fondazione Policlinico Universitario A. Gemelli IRCCS, Rome, Italy

²Università Cattolica del Sacro Cuore, Rome, Italy

³IRCCS Orthopedic Institute Galeazzi, Hand Surgery Division, Milan, Italy

⁴Department of Reconstructive Surgery and Hand Surgery, University Hospital (AOU Ospedali Riuniti di Ancona), Ancona, Italy

Abstract. – BACKGROUND: According to the literature, the brachial plexus presents a high rate of anatomical variations in the human neural system. The musculocutaneous nerve, a vital component of the brachial plexus, exhibits significant anatomical variations that hold clinical relevance across multiple medical disciplines. This case report, with a comprehensive review, explores the different variations in the course, branching patterns, and clinical implications of the musculocutaneous nerve. Understanding these variations is essential for surgeons, radiologists, and clinicians to enhance surgical precision, improve diagnostic accuracy, and reduce the risk of iatrogenic complications.

CASE REPORT: During an anatomical dissection we observed a very rare anatomical variation of the musculocutaneous nerve. Based on this discovery, we performed research in the literature with the aim of finding if this variation has been previously described. Firstly, we identified various classifications of anatomical variations of communicating branches between the musculocutaneous and median nerves, and then we observed that these variations corresponded to various rates of frequency. Our finding is a rare undescribed anatomical variant within the variants classified as Type II according to Le Minor, which is observed in 6.8-10.7% of cases.

CONCLUSIONS: The peculiar position of anatomical variations and anastomosis has clinical and functional relevance. Healthcare professionals must be aware of these variations to minimize surgical complications, accurately diagnose neurovascular pathologies, and optimize patient management. Further research into the genetic and embryological underpinnings of these variations may provide additional insights into this intriguing aspect of human anatomy.

Key Words:

Musculocutaneous nerve, Median nerve, Anatomical variations, Brachial plexus, Anastomosis.

Introduction

The musculocutaneous nerve, originating from the lateral cord of the brachial plexus, plays a pivotal role in motor and sensory innervation of the anterior arm^{1,2}. Its variations are of considerable interest in clinical practice due to their potential impact on surgical procedures, diagnosis, and patient management^{3,4}.

The musculocutaneous nerve typically arises from the lateral cord of the brachial plexus and pierces the coracobrachialis muscle before continuing as the lateral cutaneous nerve of the forearm. However, anatomical variations have been documented^{2,3}, including:

1. Variations in origin: the musculocutaneous nerve may occasionally originate directly from the anterior division of the upper trunk or the lateral cord of the brachial plexus.
2. Branching patterns: branching variations involve communications with neighboring nerves, such as the median nerve or radial nerve or the absence of a distinct musculocutaneous nerve.
3. Course alterations: variations in the course of the musculocutaneous nerve can include looping around or passing through the coracobrachialis muscle, impacting surgical dissections.

An important role in the observed variations is played by the embryological development of the

brachial plexus and genetic factors. Therefore, elucidating these mechanisms further may enhance our understanding of why certain individuals exhibit specific nerve variations.

Knowledge of the anatomical variations of the musculocutaneous nerve is crucial in various clinical scenarios:

1. Surgery: surgeons, particularly those involved in procedures on the anterior shoulder and upper arm, must be aware of nerve variations to prevent iatrogenic injuries.
2. Diagnostic: radiologists interpreting imaging studies of the brachial plexus need to recognize variations to avoid misinterpretation of pathology.
3. Rehabilitation and therapy: knowledge of musculocutaneous nerve variations can help guide rehabilitation protocols following nerve injuries, optimizing patient outcomes.

This report describes a new morphology in anatomical variations of musculocutaneous and median nerves, and the accompanying review aims to provide an in-depth analysis of the anatomical variations of the musculocutaneous nerve and their clinical significance.

Case Presentation

After obtaining the authorization of the ICLO San Francesco of Sales in Arezzo in 2018, we

performed the routine dissection of the left upper limb of an old caucasian female cadaver. The specimen was obtained within two days of death and stored at -5.2° .

We observed a double accessory branch of communication between the musculocutaneous nerve and the median nerve at the first third of the arm (Figure 1). The first branch, which originated from the musculocutaneous nerve, reinforced the median nerve, which has a larger diameter distally to communication. The second branch, which originated from the median nerve, reinforced the musculocutaneous nerve, which has a larger diameter distally than proximally.

According to the classifications of anatomical variants of the musculocutaneous nerve, we found an undescribed morphology of the anatomical variant classified in Type II of Le Minor⁵, which is observed in 6.8-10.7% of cases.

This variation has never been observed in subsequent dissections performed on 48 cadavers in the following years.

Based on this finding, we performed a literature search on variations of communicating branches between musculocutaneous and median nerves, on the frequency of presentation, on the different types of classifications, and on functional outcomes connected.

In PubMed, we searched the following keywords: “variations” and “communicating branches” and/or “musculocutaneous nerve” and “median nerve”. 47 articles were retrieved and analyzed.

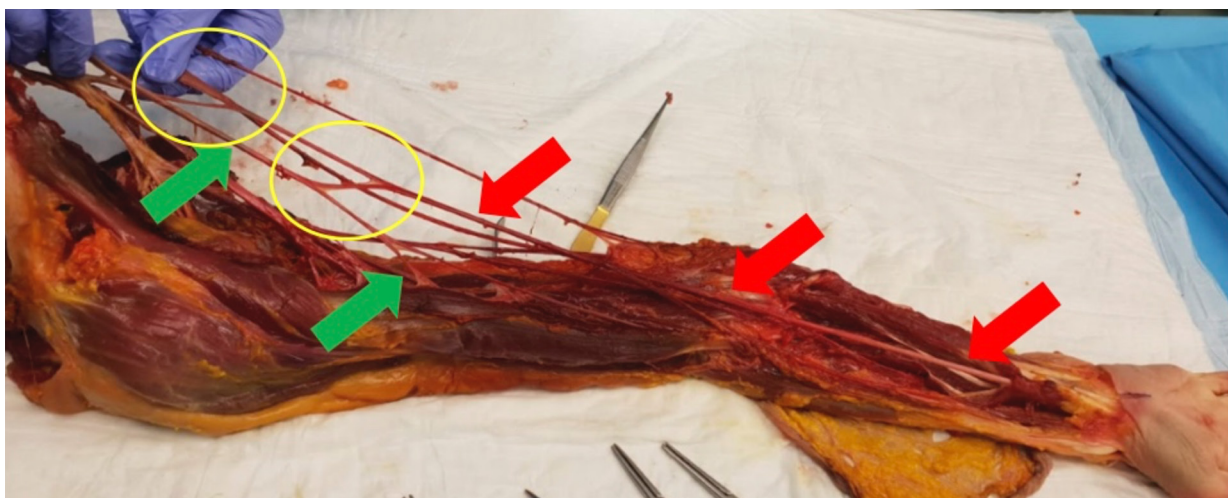


Figure 1. Our anatomical finding of the double communication between the musculocutaneous nerve and the median nerve. In the circles: the double branch of communication. Green arrows: musculocutaneous nerve; red arrows: the median nerve that runs down to the wrist.

Discussion

The brachial plexus (BP) is a network of nerve fibers formed by intercommunications among the ventral (anterior) rami (roots) of the four lower cervical nerves (C5-C8) and the first thoracic root (T1).

At the infraclavicular level, the lateral fascicle of the brachial plexus usually bifurcates and forms the musculocutaneous nerve (MCN) and the lateral root of the median nerve (MN)¹.

The MCN runs downward, passing through the coracobrachialis muscle (CBM), and then moves to the anterior compartment of the arm². More than 50% of anatomical variations of the human neural system occur in the brachial plexus^{3,4}.

The peculiar position of anatomical variations and anastomosis has clinical and functional relevance.

Anatomical variations firstly described and more commonly found are between median and ulnar nerves: the Martin Gruber⁶ anastomosis, between the median and the ulnar nerve; the Canieau and Richè⁷ anastomosis, between the thenar motor branch of the median nerve and the deep branch of the ulnar nerve in the palm of the hand, the Berrettini⁸ anastomosis, between the sensory branches of both nerves in the hand palm.

In literature, the prevalence of variations of the MCN is reported⁹ to be around 6.25%.

These anatomical variations (nerve anastomoses) lead to the exchange of fascicles between nerves and contribute to changes in motor and sensory innervation. Different investigations, such as electromyography studies, selective anesthetic nerve block, and anatomical dissections, show a variable incidence of nerve communications¹⁰.

Different types of communications between MN and MCN have been described.

The classification proposed by Maeda et al¹¹ is based on the localization of connections.

In Type I, the communication is present at the mid or distal thirds of the arm, and four subtypes are present. In subtype Ia, the communication originates from MCN in its intramuscular *via* the coraco brachialis muscle (CbM). In subtype Ib, the communicating branch takes its origin from MCN before the biceps muscle (BM) branch. In subtype Ic, the communication is between the branches going to the BM and to the brachialis muscle (BrM). In the last subtype, the Id, the communicating branch takes origin distally to the formation of the BrM branch. Type II considers the communicating branches between the MN

and the MCN¹¹. Venieratos and Anagnostopoulou¹² classified the connections between the MCN and MN in relation to the CBM. In Type I, the communication is proximal to the entrance of the MCN into the CBM, whereas in Type II, the communication is distal to the muscle, and in Type III, the CBM is not pierced either from the nerve or its communicating branch.

According to Choi et al¹³, communications between MN and MCN could be classified into three types. In Type I, the MCN and MN are fused; in Type II, there is only one link between the MCN and MN; and in Type III, two connecting branches between the MCN and MN are found.

Guerra-Guttenberg and Ingolotti¹⁴ proposed a four-step algorithm that assigns numbers and letters at each step. The first step considers the presence or absence of the MC; the second step considers whether the MC pierces the coracobrachialis muscle, while the third step determines whether communications between the MC and the median nerve or other variations exist. The last step focuses on the relationship of the communications between the MC and the median nerve with the point of entry of the MC into the coracobrachialis muscle¹³.

Le Minor⁵ distinguished between five types of communications: in Type I, there is no communication between the MN and the MCN, as described in classic textbooks². The MCN pierces the CBM and innervates it and two other muscles of the anterior compartment of the arm, as well as the anterolateral region of the antebrachial skin. In Type II, some fibers of the medial root of the MN pass through the MCN and join the MN in the middle of the arm to form the main trunk of the MN. In Type III, the lateral root fibers of the median nerve (MN), originating from the lateral cord, travel along the musculocutaneous nerve (MCN) before diverging after a certain distance to form the lateral root of the MN or join its main trunk. In Type IV, the fibers of the MCN initially merge with the lateral root of the MN, and after a non-constant distance, the MCN separates from the MN. In Type V, the MCN is absent, and its fibers travel entirely within the MN throughout its course without piercing the coracobrachialis muscle (CBM). In Type V, the MCN is also absent, with all its fibers passing through the lateral root, and the muscles usually supplied by the MCN receive innervation directly from the MN.

According to the classifications of anatomical variants of the musculocutaneous nerve, we can define our finding as a rare, previously un-

described anatomical variant within the Type II variants of Le Minor⁵, which are observed in 6.8-10.7% of cases.

Gumusburun and Adiguzel¹⁵ describe the bilateral absence of the musculocutaneous nerve. The lateral cord of the brachial plexus is formed by an anterior division with the upper and middle trunks, and two branches appear to supply the coracobrachialis muscle; the fibers of the musculocutaneous nerve are incorporated into the lateral root of the median nerve¹⁵. A complete lack of the musculocutaneous nerve is a very rare anomaly, and few authors have referred to it, like Ravishankar et al¹⁶.

The development of the brachial plexus during embryogenesis is a highly coordinated process involving precise molecular signals and cellular movements¹⁷⁻²⁰.

Between the 3rd and 4th weeks of gestation, the neural tube forms from the neural plate through neurulation. Neural crest cells, which will become peripheral neurons, migrate from the neural tube to their destined locations¹⁷⁻²⁰.

During the 4th and 5th weeks of gestation, neural crest cells differentiate into various cell types, including the sensory and motor neurons that form the brachial plexus. These cells migrate ventrally to create the dorsal root ganglia and ventral roots of the spinal nerves¹⁷⁻²⁰.

From the 5th to the 8th week of gestation, motor axons extend from the spinal cord, while sensory axons emerge from the dorsal root ganglia. These axons navigate toward their targets in the developing limb, guided by a combination of chemoattractive and chemorepulsive signals¹⁷⁻²⁰.

Between the 7th and 10th weeks of gestation, the formation of the brachial plexus occurs with the development of trunks and cords. During the 10th to 12th weeks of gestation, these cords give rise to the terminal branches of the brachial plexus¹⁷⁻²⁰.

The development of the brachial plexus is regulated by a complex interplay of molecular signals and genetic factors, including growth factors [such as nerve growth factor NGF and brain-derived neurotrophic factor (BDNF)], guidance cues (like semaphorins, netrins, and ephrins), and transcription factors [such as the subset of homeobox genes (*HOX*), Paired box genes (*Pax*), and homeobox *LIM* family]¹⁷⁻²⁰.

Disruptions in the normal development of the brachial plexus can lead to various neural abnormalities and clinical conditions, which may arise from genetic mutations, environmental factors, or mechanical injuries during development¹⁷⁻²¹.

The cause of aberrant communication between MN and MCN is not completely understood.

The presence of anomalies in the mechanism of formation of forelimb muscles and peripheral nerves during embryonic life could play a role in this sense¹⁷⁻²¹. During the fifth week of embryological development, the myotome (mesenchyme of the para-axial mesoderm) gives origin to the forelimb muscles¹⁸.

The BP originates as a single radicular cone of spinal nerve axons. The axons develop distally to achieve the limb bud mesenchyme. Then, they differentiate into the ventral and dorsal divisions. The median and ulnar nerves originate from the ventral division, while the musculocutaneous nerve is formed later from the median nerve¹⁸.

A complicated signaling interaction manages the growth of the axons, and any interference can cause significant alterations.

Although it is reported^{11,22} with low frequency, during the embryonic life, it is possible that fibers of the MCN initially run along the MN and later reestablish their configuration through a communicating branch.

Defects in the development of CBM can cause the MCN to not pierce the coracobrachialis muscle¹². The midrange frequency of the MCN-MN communication is between 17% and 36%^{1,13}.

Some authors^{11,14} reported an incidence of around 37-54.7%.

A lower incidence range (5-16%) is reported in studies^{1,12} conducted in various populations. The dimension of the samples, the protocol applied, and the ancestral biologic factors could be responsible for different expressions of these structures in the evaluated populations^{1,7}.

According to the literature^{13,22}, there is a predominance of unilateral occurrence of these variations.

A single communicating branch occurs around 90-93.2% of cases, while the observation of two communicating branches, like our Type II of Le Minor⁵, is less frequent (6.8-10.7%)^{12,14}. The MCN-MN communicating branch could be present with an additional head of the biceps brachii^{1,11,22,23}. This is a relevant finding that has to be considered during the planning of surgical procedures in the arm. This association was not present in our sample. The absence of a musculocutaneous nerve is reported²⁴ in 1.7-15% of cases and it has been described by Hoogbergen and Kauer²⁵ and Nakatani et al²⁶. The MCN entrapment can be caused by an inadequate positioning of the arm during sleep because the

coracobrachialis muscle (CbM) and biceps muscle (BM) act as anchor points for the MCN¹⁴. In the presence of a communicating branch where a part of MN passes through CbM, the manifestation could be similar to the findings of MN neuropathy in the hand. The diagnosis of MCN-MN communication in this clinical presentation by electromyographic methods could prevent unnecessary releases of the carpal tunnel¹.

Anomalies of the brachial plexus could lead to failure during brachial plexus blockade procedures and surgical management of brachial plexus tumors or trauma³. The MCN-MN communication should be considered for clinical examination of nerve injuries at the axilla and the arm, for surgical approach to this region in case of neuromuscular flaps, peripheral nerve repair such as neurotization procedures, and in case of surgery for trauma or for the nerve blocks at the upper extremities in anesthetic practice. Isolated lesions of the MC have been reported with increasing frequency. Atraumatic lesions can occur in the proximal area, affecting the entire nerve, or in the distal area, with the involvement of only the lateral cutaneous nerve¹⁴. In the first group, the causes were reported to be entrapment syndromes at the level of the coracobrachialis¹⁴ as well as in between the biceps brachii and brachialis muscle²⁷. A narrow space, bordered by the coracobrachialis muscle anteriorly and by the upper third of the humerus posteriorly, is crossed by the musculocutaneous nerve after it moved under the pectoralis minor. In this area, the nerve is susceptible to dynamic compression, with paresthesia in the anterolateral surface of the forearm. Athletes and bodybuilders with hypertrophic muscle can experience this. Compression can be caused either by intense contractions after strenuous physical activity²⁸ or by chronic pressure secondary to hypertrophy²⁹ as it occurs in weightlifters, leading to direct mechanical and ischemic injury to the nerve with subsequent focal demyelination and variable axonal degeneration³⁰. With prolonged compression, the anterior surface of the arm muscles (biceps and brachial) can present hypotrophy. The presence of fibrous bands between the biceps and brachial muscles may compress the musculocutaneous nerve³¹. Mass lesions should also be considered in patients with atraumatic MC neuropathies³². Guerri-Guttenberg and Mariana Ingolotti¹⁴ reported an isolated MC lesion in a 22-year-old patient caused by a proximal humeral osteochondroma. Symptoms similar to carpal tunnel syndrome or other

less frequent compressive neuropathies (pronator teres syndrome or anterior interosseous nerve syndrome) can be referred to in the presence of a compression proximal to the nerve communication. Symptoms depend on the type of fibers that belong to the nerve communication¹⁰. Weakness of the flexor muscles of the forearm or of the thenar region muscles could be present after injury of the musculocutaneous nerve proximally to nerve communication with clinical signs similar to a partial injury of the median nerve. The diagnosis of these variations could be difficult, and a detailed clinical examination and an electroneuromyography might be mandatory¹⁰.

Ultrasound and MRI could be useful and integrative to electroneuromyography in doubtful cases³³⁻³⁶.

Careful dissection during surgery may prevent the wound from an anastomotic branch. Meticulous clinical examination supported by electromyographic methods can assist in the diagnosis and discourage unnecessary surgical procedures. The MCN has the potential to be effectively utilized as a recipient nerve for restoring elbow flexion¹. In cases involving lower brachial plexus injuries, the motor branch of the MCN to the BrM can serve as a donor nerve for both the anterior interosseous nerve and the posterior interosseous nerve¹.

Knowledge and understanding of these topics have an important medico-legal implication. There is unanimous consensus that awareness of anatomical variations is paramount for healthcare professionals to prevent iatrogenic injuries, accurately diagnose neurovascular pathologies, and optimize patient management. This implies that the physician must provide all relevant information to the patient regarding the potential risks of iatrogenic injuries. In executing a thorough informed consent process, physicians have the professional obligation to elucidate and engage in a discussion about the risks, benefits, and possible alternatives to a specific procedure. Explaining and discussing possible alternatives is a fundamental component of the disclosure process; patients may not be able to evaluate risks in abstract terms and, therefore, require a comparative framework to make a truly informed decision³⁷.

From a future perspective, it could be helpful to explore further how neural variations may vary among different ethnic groups or geographical populations. This could help better understand the differences in the prevalence and characteristics of neural variations in different contexts.

Conclusions

Variations in the anatomy of the musculocutaneous nerve are not uncommon and have significant clinical relevance. These variations make the nerve vulnerable during routine neural repair and other surgical interventions in the pectoral and axillary regions.

Healthcare professionals must be aware of these variations. Adequate knowledge of neural and vascular variations may help interpret various clinical signs and symptoms with precision and is fundamental to minimizing surgical complications and optimizing patient management. Further research into the genetic and embryological underpinnings of these variations may provide additional insights into this intriguing aspect of human anatomy.

Ethical Statement

This case is a report found during an anatomical dissection of the Italian Society of Hand Surgery at the ICLO cadaveric center in Verona. The cadaveric specimen used in this study was donated with informed consent for its use in research and education. Ethics approval is not required for case reports.

Conflict of Interest

The authors declare that there are no conflicts of interest to disclose.

Funding

This research received no specific grant from any funding agency in the public, commercial, or not-for-profit sectors.

Data Availability

Data and materials are available for consultation from the corresponding author.

AI Disclosure

The authors disclose that they have not used any form of generative artificial intelligence for writing the manuscript.

CARE Guidelines

The authors read the CARE guidelines, and the manuscript was prepared and revised according to them.

ORCID ID

C. Fumo: 0000-0001-9841-6431
L. Marzella: 0000-0002-8106-342X
A. Lazzarini: 0000-0002-3636-3730
F. De Francesco: 0000-0003-2977-7828
R. De Vitis: 0000-0002-9714-1285

References

- 1) Ballesteros LE, Forero PL, Buitrago ER. Communication between the musculocutaneous and median nerves in the arm: an anatomical study and clinical implications. *Rev Bras Ortop* 2014; 50: 567-572.
- 2) Gray H. *Gray's Anatomy: the Anatomical Basis of Clinical Practice*, Elsevier, 2016
- 3) Emamhadi M, Chabok SY, Samini F, Alijani B, Behzadnia H, Firozabadi FA, Reihanian Z. Anatomical Variations of Brachial Plexus in Adult Cadavers; A Descriptive Study. *Arch Bone Jt Surg* 2016; 4: 253-258.
- 4) Azimi A, Eyni H, Ghorbani S, Pasbakhsh P. Variation of the musculocutaneous nerve: a case report. *MOJ Anat Physiol* 2015; 1: 82-83.
- 5) Le Minor JM. Une variation rare des nerfs médian et musculo-cutané chez l'homme [A rare variation of the median and musculocutaneous nerves in man]. *Arch Anat Histol Embryol* 1990; 73: 33-42.
- 6) Gruber W. Ueber die Verbindung des nervus medianus mit dem nervus ulnaris am unteren Arm des Menschen um der Saugethiere. [On the connection between the median nerve and the ulnar nerve in the forearm of humans and mammals]. *Arch Physiol* 1870; 37: 501-522.
- 7) Caetano EB. Contribuição ao estudo da inervação dos músculos da região tenar e da anastomose de Cannieu e Riché (tese) [Contribution to the study of the innervation of the muscles of the thenar region and the Cannieu and Riché anastomosis (thesis)]. Sorocaba, SP: Pontifícia Universidade Católica de São Paulo, Faculdade de Ciências Médicas e da Saúde 1982.
- 8) Vieira LA, Caetano MB, Yoshi PM, Sabongi Neto JJ, Caetano EB. Estudo anatômico da anastomose entre os nervos mediano e ulnar na palma da mão. [Anatomical study of the anastomosis between the median and ulnar nerves in the palm of the hand.] *Rev Bras Ortop* 2002; 37: 336-340.
- 9) Bhattarai P, Poudel P. Unusual variation in musculocutaneous nerves. *Kathmandu Univ Med J (KUMJ)* 2009; 7: 408-410.
- 10) Caetano EB, Vieira LÂ, Cavalheiro CS, Razuk M Filho, Almargo MA, Caetano MF. Anatomic study of the nervous communication between the median and musculocutaneous nerve. *Acta Ortop Bras* 2016; 24: 200-203.
- 11) Maeda S, Kawai K, Koizumi M, Ide J, Tokiyoshi A, Mizuta H, Kodama K. Morphological study of the communication between the musculocutaneous and median nerves. *Anat Sci Int* 2009; 84: 34-40.
- 12) Venieratos D, Anagnostopoulou S. Classification of communications between the musculocutaneous and median nerves. *Clin Anat* 1998; 11: 327-331.
- 13) Choi D, Rodríguez-Niedenführ M, Vázquez T, Parkin I, Sañudo JR. Patterns of connections between the musculocutaneous and median nerves in the axilla and arm. *Clin Anat* 2002; 15: 11-17.

- 14) Guerri-Guttenberg RA, Ingolotti M. Classifying musculocutaneous nerve variations. *Clin Anat* 2009; 22: 671-683.
- 15) Gumusburun E, Adiguzel E. A variation of the brachial plexus characterized by the absence of the musculotaneous nerve-a case report. *Surg Radiol Anat* 2000; 22: 63-65.
- 16) Ravishankar MV, Jevoor PS, Shaha L. Bilateral absence of musculocutaneous nerve. *J Sci Soc* 2012; 39: 34-36.
- 17) Johnson EO, Vekris M, Demesticha T, Soucacos PN. Neuroanatomy of the brachial plexus: normal and variant anatomy of its formation. *Surg Radiol Anat* 2010; 32: 291-297.
- 18) Schoenwolf GC, Bleyl SB, Brauer PR, Francis-West PH. *Larsen's Human Embryology E-Book*, Elsevier Health Sciences 2014.
- 19) Connolly MR, Auchincloss HG. Anatomy and Embryology of the Thoracic Outlet. *Thorac Surg Clin* 2021; 31: 1-10.
- 20) Leijnse JN, de Bakker BS, D'Herde K. The brachial plexus - explaining its morphology and variability by a generic developmental model. *J Anat* 2020; 236: 862-882.
- 21) Senes FM, Campus R, Becchetti F, Catena N. Upper limb nerve injuries in developmental age. *Microsurgery* 2009; 29: 529-535.
- 22) Kosugi K, Shibata S, Yamashita H. Supernumerary head of biceps brachii and branching pattern of the musculocutaneous nerve in Japanese. *Surg Radiol Anat* 1992; 14: 175-185.
- 23) Ozturk NC, Uzmansel D, Ozturk H. An unreported pattern of musculocutaneous and median nerve communication with multiple variations of biceps brachii: a case report. *Surg Radiol Anat* 2010; 32: 887-890.
- 24) Rodríguez-Niedenführ M, Vázquez T, Choi D, Parkin I, Sañudo JR. Supernumerary humeral heads of the biceps brachii muscle revisited. *Clin Anat* 2003; 16: 197-203.
- 25) Hoogbergen MM, Kauer JM. An unusual ulnar nerve- median nerve communicating branch. *J Anat* 1992; 181: 513-516.
- 26) Nakatani T, Tanaka S, Mizukami S. Two rare anomalies of the brachial plexus. *J Anat* 1998; 192: 303-304.
- 27) DeFranco MJ, Schickendantz MS. Isolated musculocutaneous nerve injury in a professional fast-pitch softball player: A case report. *Am J Sports Med* 2008; 36: 1821-1823.
- 28) Simonetti S. Musculocutaneous nerve lesion after strenuous physical activity. *Muscle Nerve* 1999; 22: 647-649.
- 29) Fattal C, Weber J, Beuret-Blanquart F. Isolated musculocutaneous nerve palsy in a spinal cord injury. *Spinal Cord* 1998; 36: 591-592.
- 30) Papanikolaou A, Maris J, Tsampazis K. Isolated musculocutaneous nerve palsy after heavy physical activity. *Injury Extra* 2005; 36: 486-488.
- 31) Caetano EB, Lech O. Síndromes compressivas do membro superior. [Compression syndromes of the upper limb.] Rio de Janeiro: Dilivros 2016.
- 32) Juel VC, Kiely JM, Leone KV, Morgan RF, Smith T, Phillips LH II. Isolated musculocutaneous neuropathy caused by a proximal humeral exostosis. *Neurology* 2000; 54: 494-496.
- 33) Griffith JF. Ultrasound of the Brachial Plexus. *Semin Musculoskelet Radiol* 2018; 22: 323-333.
- 34) Porter SB, Garner HW, Schoch BS, Murray PM, Robards CB, Franco MJ. Anomalous Course of the Brachial Plexus Identified During Ultrasound-Guided Brachial Plexus Nerve Block. *Turk J Anaesthesiol Reanim* 2022; 50: 312-314.
- 35) Boulanger X, Ledoux JB, Brun AL, Beigelman C. Imaging of the non-traumatic brachial plexus. *Diagn Interv Imaging* 2013; 94: 945-956.
- 36) Szaro P, McGrath A, Cizek B, Geijer M. Magnetic resonance imaging of the brachial plexus. Part 1: Anatomical considerations, magnetic resonance techniques, and non-traumatic lesions. *Eur J Radiol Open* 2021; 9: 100392.
- 37) Bolcato V, Franzetti C, Fassina G, Basile G, Martinez RM, Tronconi LP. Comparative study on informed consent regulation in health care among Italy, France, United Kingdom, Nordic Countries, Germany, and Spain. *J Forensic Leg Med* 2024; 103: 102674.