

# Clinical value and effectiveness profiles of oblique lateral interbody fusion and posterior lumbar interbody fusion in the treatment of lumbar brucellosis spondylitis

Y.-L. JIA<sup>1</sup>, X.-H. ZUO<sup>2</sup>, Y. ZHANG<sup>1</sup>, Y. YAO<sup>1</sup>, Y.-L. YIN<sup>1</sup>, X.-M. YANG<sup>1</sup>

<sup>1</sup>Department of Orthopedics, The First Affiliated Hospital of Hebei North University, Zhangjiakou, Hebei Province, China

<sup>2</sup>Zhangjiaku College of Nursing, Zhangjiakou, Hebei, China

**Abstract. – OBJECTIVE:** The aim of this study was to assess the clinical efficacy of oblique lateral interbody fusion (OLIF) and posterior lumbar interbody fusion (PLIF) for lumbar brucellosis spondylitis.

**PATIENTS AND METHODS:** Between April 2018 and December 2021, 80 cases of lumbar brucellosis spondylitis admitted to our institution were evaluated for eligibility and randomly assigned to either PLIF (group A, lesion removal by posterior approach + interbody fusion + percutaneous pedicle screw internal fixation) or OLIF (group B, lesion removal by anterior approach + interbody fusion + percutaneous pedicle screw internal fixation). The outcome measures included operative time, intraoperative bleeding, hospital stay, preoperative and postoperative visual analogue scale (VAS) ratings, American Spinal Injury Association (ASIA) classification, Cobb angle, and interbody fusion time.

**RESULTS:** PLIF resulted in shorter operative time and hospital stay and less intraoperative bleeding vs. OLIF ( $p < 0.05$ ). All eligible patients showed significantly lower VAS scores, and smaller ESR values and Cobb angles after treatment ( $p < 0.05$ ), but no significant intergroup differences were observed ( $p > 0.05$ ). The two groups showed similar preoperative ASIA (American Spinal Injury Association) classification and interbody fusion time ( $p > 0.05$ ). PLIF was associated with better ASIA classification at three months postoperatively vs. OLIF ( $p < 0.05$ ).

**CONCLUSIONS:** Both surgical techniques are efficient at removing the lesion, relieving pain, maintaining spinal stability, promoting implant fusion, and facilitating prognostic inflammation control. PLIF features a shorter surgical duration and hospital stay, less intraoperative bleeding, and greater neurological improvement vs. OLIF. Nevertheless, OLIF outperforms PLIF in the excision of peri-vertebral abscesses. PLIF is indicated for posterior spinal column lesions, particularly those with spinal nerve compression in the spinal canal, whereas OLIF is indicated for structural bone deterioration in the anterior column, particularly for those with perivascular abscesses.

## Key Words:

Spinal fusion, Brucellosis spondylitis, Lumbar spine, Oblique lateral interbody fusion, Posterior lumbar interbody fusion.

## Introduction

Brucellosis is an infectious-zoonotic disease caused by *Brucella* and is characterized by chronic pain, high fever, excessive sweating, arthralgia, and hepatosplenomegaly. An epidemiological survey found that the global incidence of brucellosis is about 2.93/100,000 cases, while the incidence of brucellosis in China only in 2012 has been as high as 3.11/100,000 cases, with a yearly growth trend<sup>1</sup>. The infected strains in China are mainly sheep strains, followed by bovine strains, and the disease is mainly prevalent in the northwest, northeast, Qinghai-Tibet Plateau, and Inner Mongolia with pastoral areas in China<sup>2,3</sup>. *Brucella* is a Gram-negative intracellular parasitic bacterium that is mainly infected through scars and wounds on the skin. *Brucella* infection invades numerous systems throughout the body, and in humans mostly manifests as osteoarticular and spinal involvement, with L4-5 and L5-S1 spinal infections being the most common clinical cases. In recent years, with the development of the breeding industry and the increase in the number of urban pets in China, the disease shows a growing prevalence. Inadequate treatment may lead to infectious lesions of the bone and joint, and lesions in the spine or vertebrae are called brucellosis spondylitis.

*Brucella* spondylitis lacks a uniform treatment protocol. In general, cases in the acute stage, without symptoms of nerve damage, imaging showing inconspicuous vertebral destruction, and without

paravertebral soft tissue swelling are mostly treated conservatively or medically, such as prolonged bed bracing, enhanced supportive therapy, and antibiotic therapy. If formal conservative treatment is ineffective, surgical treatment is indicated. Surgical treatment is indicated in the event of abscess compressing the spinal cord, resulting in severe damage to the vertebrae and/or discs and vertebral instability<sup>4-6</sup>.

Posterior lumbar interbody fusion (PLIF) is mostly used clinically for patients who are eligible for surgical indications and compared with oblique lateral interbody fusion (OLIF), PLIF features smaller surgical trauma, shorter operative time, and no intraoperative change in patients' position; however, OLIF is superior to PLIF in removing periventricular abscesses<sup>7-9</sup>. Despite the efficacy of treatments such as surgery and antibiotics, surgery results in significant trauma to the patient. Thus, the combination of Chinese and Western medicine may provide patients with more better treatment options for post-operative rehabilitation. The characteristics of multi-target and multi-pathway mechanisms can effectively compensate for the deficiencies of simple Western drug therapy, and the combination of Chinese and Western medicine is expected to constitute a new direction in the clinical treatment of *Brucella* spondylitis.

In traditional Chinese medicine (TCM), *Brucella* spondylitis is classified as "paralysis", and its pathogenesis is mainly attributed to the invasion of wind, cold, and dampness, which leads to the stagnation of qi and blood in the meridians and obstruction of qi flow, resulting in joint fixation and non-extension, and eventually joint ankylosis. The treatment should be based on clearing heat to overcome dampness, promoting paralysis, and relieving pain. Herein, 80 cases of lumbar brucellosis spondylitis were recruited to assess the clinical efficacy of OLIF and PLIF<sup>10,11</sup>.

## Patients and Methods

### Baseline Data

Between April 2018 and December 2020, 80 cases of lumbar brucellosis spondylitis admitted to our institution assessed for eligibility were recruited and were assigned (1:1) to receive PLIF (group A) or OLIF (group B).

The randomization was carried out using an online web-based randomization tool (<http://www.randomizer.org/>). For concealment of allocation, the randomization procedure and assign-

ment were managed by an independent research assistant who was not involved in screening or evaluation of the participants.

The original sample size calculation estimated that 40 patients in each group would be needed to detect a 3-point difference between groups in a 2-sided significance test with a power of 0.8 and an alpha error level of 0.05.

The baseline characteristics of group A [19 males and 21 females, aged 44-65 years, mean age (54.3±5.8) years, course of disease of (1.8-5.3) months, course of disease of (3.6±0.9) months, 31 cases involving one segment (11 cases of L<sub>3-4</sub>, 15 cases of L<sub>4-5</sub>, and 5 cases of L<sub>5</sub>-S<sub>1</sub>), 9 cases involving two segments (4 cases of L<sub>2-4</sub> and 5 cases of L<sub>3-5</sub>)] were comparable with those of group B [20 males and 20 females, aged 45-67 years, mean age (54.5±5.4) years, course of disease of (0.8-5.2) months, course of disease of (3.4±1.0) months, 30 cases involving one segment [10 cases of L<sub>3-4</sub>, 14 cases of L<sub>4-5</sub>, and 6 cases of L<sub>5</sub>-S<sub>1</sub>], 10 cases involving two segments (4 cases of L<sub>2-4</sub> and 6 cases of L<sub>3-5</sub>)] ( $p>0.05$ ) (Table I).

### Ethical Statement

The studies involving human participants were reviewed and approved by The First Affiliated Hospital of Hebei North University, all methods were performed in accordance with the Declaration of Helsinki. The patients provided their written informed consent to participate in this study.

### Inclusion and Exclusion Criteria

#### Inclusion criteria

Patients were included if the epidemiological history, clinical manifestations, imaging characteristics, and clinical-specific serological findings [such as rose bengal plate test (RBPT), serum agglutination test, complement fixation test (CFT), and anti-human immunoglobulin (Coombs) test conformed to the diagnostic criteria for brucellosis promulgated by the Department of Endemic Disease Prevention and Control of the Ministry of Health] were available as well as if at least one of the following conditions was observed:

- 1) with one course of regular drug treatment and no relief of symptoms;
- 2) with a large and difficult to absorb paravertebral abscess or lumbar muscle abscess;
- 3) with intravertebral canal abscess or inflammatory granuloma;
- 4) with intractable back pain elicited by intravertebral disc destruction;

**Table I.** Comparison of baseline data [n (%)].

	Group A (n=40)	Group B (n=40)	t/ $\chi^2$	P
Gender			0.05	0.823
Male	19	20		
Female	21	20		
Mean age (year)	54.3±5.8	54.5±5.4	-0.20	0.842
Mean course (month)	3.6±0.9	3.4±1.0	0.925	0.358
Lesion site			0.069	0.793
One segment	31	30		
L3-4	11	10		
L4-5	15	14		
L5-S1	5	6		
Two segments	9	10		
L2-44	4	4		
L3-5	5	6		

- 5) with large foci of vertebral destruction ( $\geq 1$  cm in diameter) or joint breakthrough affecting spinal stability; 6) with compression of the spinal cord or cauda equina nerve root.

*Exclusion criteria*

Exclusion criteria were patients 1) without formal drug treatment; 2) with immature skeletal development; 3) with immunosuppressive drugs in the past 6 months; 4) with other spinal infections; 5) with mild local spinal symptoms and systemic brucellosis toxicity as the main manifestation; 6) with simple vertebral or intervertebral infection or combined with small foci of bone destruction or small abscesses, with good spinal stability and no neurological dysfunction.

**Preoperative Preparation**

Patients were required to remain bedridden during treatment. Correction of malnutrition and improvement of anemia were carried out to improve the patient’s resistance to disease. First-line oral anti-brucellosis spondylitis drug therapy (Doxycycline 0.1 g 2 times/d, Rifampin 0.6 g 1 time/d, Sulfamethoxazole 1.0 g) was administered twice daily for 2-3 weeks. The patients were considered operable after significantly reduced systemic brucellosis symptoms, alleviated malnutrition, hemoglobin not less than 110 g/L, and erythrocyte sedimentation rate less than 45 mm/h.

**Surgical Procedures**

Group A: The patients were given general anesthesia in a prone position. A posterior median spinal incision was made to expose the spinous process, the vertebral plate, the articular process,

and one vertebral segment above and below the lesion, followed by accurate insertion of pedicle screws under the C-arm X-ray fluoroscopy. If the preoperative imaging showed mild destruction of the vertebral body, sclerotic bone, and good bone quality of the pedicle and vertebral body at the nail placement site, the pedicle screws were then placed into the diseased vertebrae after the use of streptomycin. In the case of severe damage to the vertebral body or spinal instability, pedicle screw fixation was performed on the vertebral segment above and below the lesion, respectively. Decompression of the diseased vertebral lamina was conducted to expose the spinal cord or dural sac and nerve roots of the diseased segment and remove the pus from the spinal canal. In the presence of inflammatory granulomas or abscesses in the anterior aspect of the spinal cord or dural sac, below the posterior longitudinal ligament and around the nerve roots, the envelope was incised and the inflammatory granulomas or abscesses and the area of bone destruction at the posterior edge of the vertebral body were excised. The fibrous annulus between the two diseased vertebrae was then dissected, the intervertebral space was scraped of infected disc tissue or destroyed cartilage plates, and the visibly sclerotic vertebral bone was excised until oozing blood was observed from the bone surface. The diseased tissue at the anterior edge of the vertebral body was carefully removed by scraping under the guidance of a C-arm x-ray machine. The removal of lesion tissue behind the anterior longitudinal ligament was observed by endoscopic observation of the disc, and additional removal was conducted for any residual lesion. The diseased vertebral interarticular and transverse processes were polished for

bone grafting. The wound was repeatedly rinsed three times with hydrogen peroxide, iodophor dilution, and a large amount of gentamicin rinse saline, swabbed dry, and then the granulated vertebral plate bone was implanted with 1 g of dry streptomycin powder in the interarticular and transverse processes (autologous iliac bone can be taken if the amount of bone-implant was insufficient), followed by placement of drainage tube and closure of the incision.

Group B: The patients were given general anesthesia in a prone position. The patients firstly received percutaneous pedicle screw internal fixation, which was identical to that used for group A. After fixation, the patients were changed to a supine or lateral position and received anterior lesion removal and interbody fusion. A low renal incision was used for L1-3 vertebral lesions and an inverted figure-of-eight incision was used for L3-S1 vertebral lesions, and abscesses or inflammatory granuloma tissue in the paravertebral area, lumbar major muscle, and anterior edge of the vertebral body were thoroughly removed after full exposure of the lesion segment. The destroyed disc, cartilage plate, and foci of bone destruction were then cleared, and the paravertebral contralateral abscess and the abscess or inflammatory granuloma tissue anterior to the dura in the spinal canal were removed through the intervertebral space. A separate incision could be made *via* the contralateral side to remove the abscess for a large contralateral abscess. The wound was repeatedly rinsed three times with hydrogen peroxide, iodophor dilution, and a large amount of gentamicin rinse saline, swabbed dry, and 1 g of dry streptomycin powder was sprinkled inside the lesion. Autologous iliac bone blocks were used for the intervertebral support implants to stabilize the spinal structure, while the autologous granulated bone was implanted inside the larger foci of vertebral bone destruction after removal, followed by placement of drainage tubes and closure of the incision.

The surgery was performed under the same responsible chief physician in both groups. Pathological examination and bacterial culture and drug sensitivity tests were conducted on the excised lesions during surgery. Postoperative anti-brucellosis treatment was continued with the same drugs as preoperative medication.

The two groups received oral administration of Qianghuo Shengshi Decoction. The ingredients of the decoction included 15 g each of *Radix Stephaniae Tetrandrae*, *Saposhnikoviae Radix*, *Ramulus Mori*, *Talcum*, *Semen Coicis*, *Poria*, and *Clematidis Radix Et Rhizoma*, 9 g each of *Fructus Gardeniae*,

*Radix Angelicae Pubescentis*, *Rhizoma Et Radix Notopterygii*, *Tangerine Peel*, *Pinelliae Rhizoma*, *Caulis Lonicerae*, *Herba Siegesbeckiae*, and *Gentiana Macrophyllae Radix*, and 6 g of liquorice root. The above herbs were decocted with water to obtain 400 mL of filtrates and administered daily with half dose in the morning and half dose in the evening. The duration of treatment was 3 months.

### **Outcome Measure and Evaluation Criteria**

1. The operative time, intraoperative bleeding, and postoperative hospital stay were monitored and recorded in all eligible patients.
2. Visual analogue scale (VAS) score: this sliding scale has a total of 10 points, with higher scores indicating more severe pain.
3. American Spinal Injury Association (ASIA) neurological function grading. Grade A indicates complete injury: sacral segment S4 and S5 without any sensory and motor function preserved. Grade B indicates incomplete injury: the sensory function below the nerve plane including sacral segment S4 and S5 exists, without any motor function. Grade C indicates incomplete injury: there is motor function preserved below the nerve plane, more than half of the key muscle strength < grade 3. Grade D indicates incomplete injury: there is motor function preserved below the nerve plane, more than half of the key muscle strength  $\geq$  grade 3. Grade E indicates normal: normal sensory and motor function.
4. Erythrocyte sedimentation rate (ESR). The ESR was determined using the Westergren method. The isolated anticoagulated blood solution was placed in a specially graduated measuring tube, standing vertically at room temperature, and the 1 hours erythrocyte layer sinking distance was reported in millimeters (mm) values.
5. The Cobb angle. X-rays were used to obtain frontal and lateral views of the spine to determine the property of the disease. The posterior convexity was determined from the lateral view with the normal displaced vertebrae. The Cobb angle was determined by an angle formed by two vertical lines drawn at the upper edge of the displaced vertebral body. A vertical line was drawn at the upper edge and the lower edge of the displaced vertebral body, respectively.
6. Interbody fusion time. All patients were followed up for 14-38 months, with a mean of (25.76 $\pm$ 5.81) months, and the interbody fusion time was observed and recorded regularly in both groups by X-rays.

**Statistical Analysis**

The SPSS 22.0 (IBM Corp., Armonk, NY, USA) was used for data analyses, and GraphPad Prism 8 (GraphPad Software, Inc., San Diego, CA, USA) was used for image rendering. Normally distributed measurement data were expressed as mean plus or minus standard deviation ( $\bar{x} \pm s$ ). The comparison of means between two groups was preceded by the Chi-squared F-test. Data with Chi-squared differences were tested with the independent samples *t*-test, and data with non-Chi-squared differences were tested with the independent samples *t*-test. Intra-group pre-post comparisons were performed with paired samples *t*-test. The count data were expressed as the number of cases (rate) and processed by the Chi-square test. Differences were considered statistically significant at  $p < 0.05$ .

**Results**

**Comparison of Perioperative Indices**

PLIF resulted in shorter operative time and hospital stay, and less intraoperative bleeding vs. OLIF ( $p < 0.05$ ) (Table II).

**Comparison of VAS Scores**

After therapy, all eligible patients had considerably decreased VAS scores ( $p < 0.05$ ), and no

significant intergroup differences were observed ( $p > 0.05$ ) (Table III).

**Comparison of ESR Values**

All eligible patients' ESR readings were significantly decreased after surgery ( $p < 0.05$ ), but no differences were identified between the two groups. ( $p > 0.05$ ) (Table IV).

**Comparison of Cobb Angles**

All eligible patients' Cobb angles were considerably lowered following surgery ( $p < 0.05$ ), with no differences detected between the two groups. ( $p > 0.05$ ) (Table V).

**Comparison of ASIA Classification**

In group A, there were 18 patients with preoperative neurological dysfunction (7 cases of grade C and 11 cases of grade D) and 19 patients with preoperative neurological dysfunction in group B (8 cases of grade C and 11 cases of grade D). There was one patient in group A with neurological dysfunction (1 case of grade D) three months after surgery, and nine patients in group B with neurological dysfunction (2 cases of grade C and 7 cases of grade D). The two groups had comparable preoperative ASIA classifications ( $p > 0.05$ ). PLIF was associated with better ASIA classification at three months postoperatively vs. OLIF ( $p < 0.05$ ) (Figure 1).

**Table II.** Comparison of perioperative indices ( $\bar{x} \pm s$ ).

Groups	n	Operative time (min)	Intraoperative bleeding (mL)	Length of hospital stay (d)
Group A	40	212.5±59.3	877.3±412.1	15.6±4.1
Group B	40	367.6±50.7	1,287.6±601.7	22.8±6.8
<i>t</i>	-	-12.584	-3.557	-5.753
<i>p</i>	-	<0.001	0.001	<0.001

**Table III.** Comparison of VAS scores ( $\bar{x} \pm s$ ).

Groups	n	VAS scores (points)					F	<i>p</i>
		Preoperatively	3 days postoperatively	2 weeks postoperatively	3 months postoperatively	Last follow-up		
Group A	40	9.1±0.3	3.8±0.5 <sup>a</sup>	2.2±0.3 <sup>a</sup>	1.0±0.2 <sup>a</sup>	0 <sup>b</sup>	3,945.376	<0.01
Group B	40	9.1±0.1	3.9±0.4 <sup>a</sup>	2.1±0.2 <sup>a</sup>	0.9±0.3 <sup>a</sup>	0 <sup>b</sup>	6,601.953	<0.01
<i>t</i>	-	-1.352	-0.739	1.590	1.600	-	-	-
<i>p</i>	-	0.180	0.462	0.116	0.116	-	-	-

VAS: visual analogue scale. <sup>a</sup>indicates  $p < 0.05$  in the comparison between preoperative VAS scores and postoperative VAS scores at different time points in the group; <sup>b</sup> indicates no pain at the last follow-up.

Comparison of effectiveness of different operations on brucellosis spondylitis

**Table IV.** Comparison of ESR values ( $\bar{x}\pm s$ ).

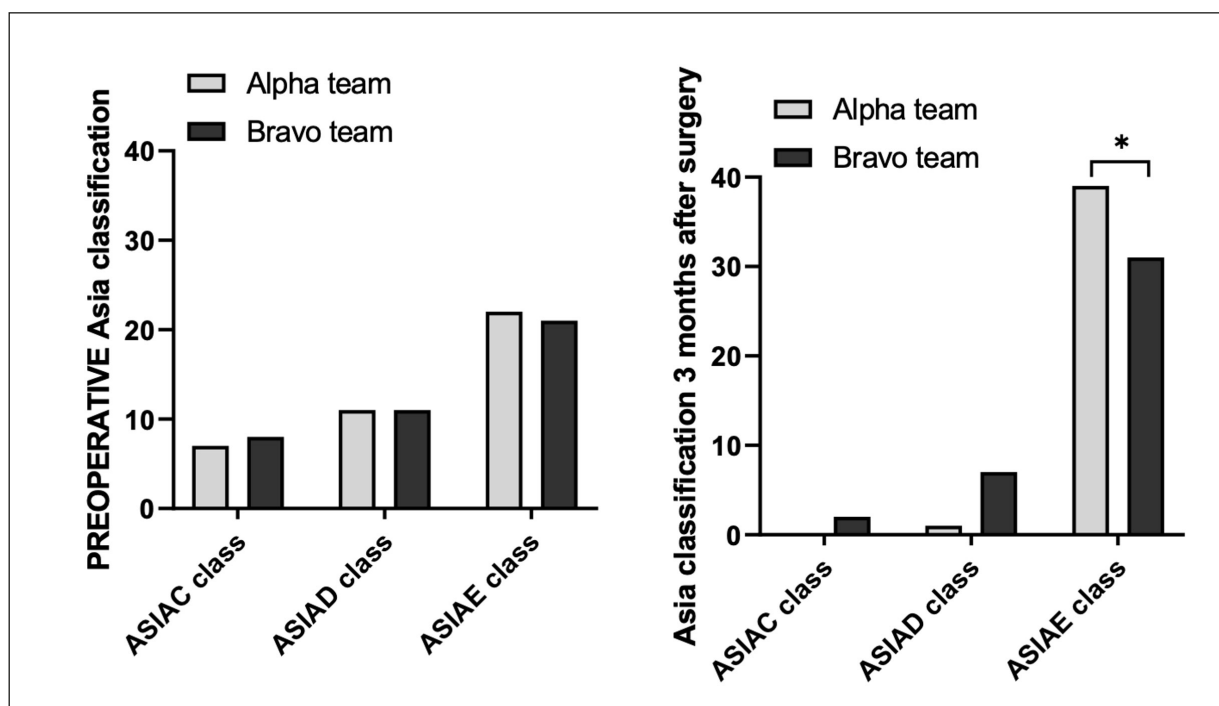
Groups	n	ESR (mm/h)					F	p
		Preoperatively	3 days postoperatively	2 weeks postoperatively	3 months postoperatively	Last follow-up		
Group A	40	38.5±5.5	20.3±3.7 <sup>a</sup>	15.0±2.9 <sup>a</sup>	8.3±2.1 <sup>a</sup>	5.3±2.7 <sup>a</sup>	546.701	<0.01
Group B	40	38.3±6.0	19.5±4.3 <sup>a</sup>	14.6±3.1 <sup>a</sup>	7.9±2.5 <sup>a</sup>	5.2±2.5 <sup>a</sup>	453.292	<0.01
t	-	0.231	0.882	0.492	0.603	0.174	-	-
p	-	0.818	0.381	0.624	0.548	0.863	-	-

ESR: erythrocyte sedimentation rate. <sup>a</sup>indicates  $p<0.05$  in the comparison between preoperative ESR values and postoperative ESR values at different time points in the group.

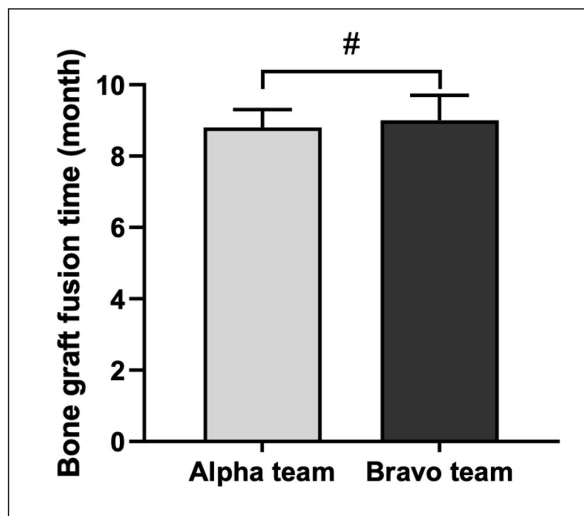
**Table V.** Comparison of Cobb angles ( $\bar{x}\pm s$ ).

Groups	n	Cobb angles (°)					F	p
		Preoperatively	3 days postoperatively	2 weeks postoperatively	3 months postoperatively	Last follow-up		
Group A	40	33.2±7.3	12.3±2.7 <sup>a</sup>	11.4±3.5 <sup>a</sup>	11.2±3.7 <sup>a</sup>	10.9±2.8 <sup>a</sup>	203.111	<0.01
Group B	40	33.5±7.6	12.1±3.4 <sup>a</sup>	11.6±4.0 <sup>a</sup>	11.3±3.4 <sup>a</sup>	11.1±2.9 <sup>a</sup>	185.873	<0.01
t	-	-0.181	0.437	-0.241	-0.003	-0.168	-	-
p	-	0.857	0.664	0.810	0.998	0.867	-	-

<sup>a</sup>indicates  $p<0.05$  in the comparison between preoperative Cobb angles and postoperative Cobb angles at different time points in the group.



**Figure 1.** Comparison of ASIA classification [n (%)]. \*indicates  $\chi^2 = 7.314$ ,  $p=0.007$  in the comparison of the number of patients with ASIA grade E at 3 months postoperatively in both groups; ASIA grade E=normal sensory and motor function.



**Figure 2.** Comparison of interbody fusion ( $\bar{x} \pm s$ ). # indicates  $t=-1.068$ ,  $p=0.289$  in the comparison of interbody fusion time between the two groups of patients.

### Comparison of Interbody Fusion

Patients in group A had an interbody fusion time of 8-10 ( $8.8 \pm 0.5$ ) months, whereas patients in group B had an interbody fusion time of 7-11 ( $9.0 \pm 0.7$ ) months. In terms of interbody fusion time, there was no statistically significant difference between the two groups of patients ( $p > 0.05$ ) (Figure 2).

## Discussion

Brucellosis is a serious zoonotic infection that affects multiple hosts and is highly contagious and widespread. *Brucella* spondylitis is one of the osteoarticular systemic manifestations of brucellosis and is a very rare form of spondylitis. *Brucella* spondylitis accounts for 7.5% of brucellosis and involves several parts of the spine, with the lumbar spine being the most common, mainly presenting as vertebral and intervertebral disc inflammation with lesions involving the bone and periarticular areas<sup>12,13</sup>. The application of long-term, adequate, co-administered, and multi-path sensitive antibiotics is the primary and most reliable treatment and prevention of brucellosis spondylitis, and the vast majority of patients is associated with curative treatment with regular pharmacotherapy<sup>14,15</sup>. Patients with pronounced back pain, spinal cord compression, reduced neurological function, spinal instability, and abscesses who obtain no improvement following routine pharmacological therapy with curative purpose are indicated for surgery.

After preoperative therapy with standardized medicine, all eligible patients in the current study exhibited better systemic brucellosis toxicity symptoms and obvious indications for surgery, but no improvement of local spinal symptoms. Currently, surgery for brucellosis spondylitis comprises mostly of OLIF and PLIF, which facilitates to relieve pain, stabilize the spine, and restore neurological function. Nonetheless, the analysis of the specific strengths and drawbacks of each procedure was not reported.

Posterior lumbar interbody fusion is simple and safe, with small trauma and rapid and clear exposure, but should be preceded by internal fixation of the pedicle nail to avoid medically induced spinal cord, cauda equina, or nerve root injury due to vertebral disruption or instability<sup>16,17</sup>. Internal fixation overcomes the defect of internal fixation loosening and subsequent loss of correction due to difficulty in controlling the quality of the anteriorly secured vertebrae, prevents kyphosis aggravation, allows immediate and long-term spinal segment stability, restores the physiological curvature of the spine, maintains the stability of the anterior, middle, and posterior spinal implants, and promotes implant fusion. It allows the implanted internal fixation to be distanced from the lesion, thereby lowering the risk of infection and non-healing of the implant. However, internal fixation affects the segmental motion function of the spine and leads to degeneration of the adjacent segments to varying degrees, which requires scientific and reasonable expansion of the scope of internal fixation. Destruction of the vertebral articular processes is the characteristic bone destruction of spondylolisthesis and is the main cause of spinal instability. If the preoperative imaging showed mild destruction of the vertebral body, little sclerotic bone, and good bone quality of the pedicle and vertebral body at the nail placement site, the pedicle screws were then placed into the diseased vertebrae after applying streptomycin. Pedicle screw fixation was conducted on the vertebral segment above and below the lesion in the cases of extensive vertebral body injury or spinal instability. Although posterior lesion removal under direct vision allows complete removal of damaged disc lesion tissue, intracanalicular abscess, inflammatory granuloma, and vertebral body posterior margin destruction of bone to relieve spinal cord and nerve root compression, it only reveals the posterior column region of the spine. It requires C-arm X-ray fluoroscopic guidance and dichoscopic assistance to complete le-

sion clearance in the anterior column region of the spine. Moreover, it fails to completely remove large abscesses around the vertebral body and predisposes to postoperative recurrence.

In the present study, there were 18 cases with preoperative neurological dysfunction in group A and only one case had insignificant improvement 3 months after surgery, which indicates a favorable result of removing the intraspinal spinal cord, cauda equina, or nerve root compression through the posterior direct vision. Four patients experienced postoperative recurrence due to insufficient abscess removal due to the limited surgical field of vision, and scraping angle, and were treated by anterior lesion excision again after failed anti-brucellosis medication treatment. Brucellosis is a chronic infectious wasting illness, and some patients are severely malnourished prior to surgery. With a less invasive profile than OLIF, PLIF is more suited for patients with low nutritional status with sensitivity to protracted, invasive, and bleeding operations.

The results of the present study showed that PLIF resulted in shorter operative time and hospital stay, and less intraoperative bleeding vs. OLIF. PLIF has the following advantages: (1) the removal of lesions from the vertebral body, intervertebral space, articular eminence and spinal canal, the bone grafting between transverse synapses, and internal fixation of the vertebral arch were all performed through one surgical incision, the bone grafting area is distanced from the lesion, and no changes in position are required during the operation<sup>18</sup>; (2) the surgery can be operated within the same incision to remove bilateral lesions of posterior spinal column structures or bilateral inflammatory compression-causing materials of the dura mater and nerve roots<sup>19,20</sup>; (3) PLIF thoroughly removes inflammatory granulation tissue (especially around nerve roots), abscesses, necrotic intervertebral discs and destroyed cartilage surfaces in the spinal canal, and release the cause of spinal cord or nerve root compression, which effectively relieves pain and reduces complications.

OLIF is a common method used for the treatment of infectious spondylitis with excellent clinical efficacy. Shen et al<sup>21</sup> used a staged approach, with anterior lesion removal in one stage and posterior fixation and fusion of the diseased spine in the second stage after stabilization of patient condition. However, their results showed that staged surgery is not associated with reduced surgical trauma and risk. The advantages of OLIF are as follows: (1) The removal of lesions in the anterior approach only reveals

the diseased vertebral body and intervertebral space, which contributes to reducing the probability of bacterial spread in normal tissues. (2) The anterior lesion removal directly and completely clears the huge abscess of the paravertebral or lumbar muscle, and scrapes away the foci of vertebral bone destruction and disc lesions, to release the limited compression in front of the spinal cord or dura mater. (3) Anterior intervertebral implants restores the height of the anterior mid-column, corrects the retroflexion deformity, achieves support for the unstable spine, and fills the bone defect for the foci of bone destruction, eliminates the dead cavity, and fulfills the biomechanical requirements of the spine<sup>22,23</sup>. (4) Posterior pedicle screws fixation requires a limited incision under C-arm X-ray and effectively corrects kyphosis and vertebral collapse by adjusting the curvature of the rods, thereby restoring the physiological curvature of the spine and the height of the vertebral body. (5) Posterior internal fixation provides a well-established mechanical environment for immediate postoperative spinal stability and fusion of bone graft, and the fusion of anterior bone graft lays the foundation for permanent spinal stability, the combination of which allows early out-of-bed activities after surgery. (6) In OLIF, the separation of the internal fixation and anterior lesion removal incision avoids direct contact between the internal fixation and the lesion, reduces the probability of postoperative infection, and facilitates the fusion of anteriorly supported bone graft or intervertebral space graft<sup>24</sup>.

Moreover, TCM decoction was also administered to all eligible patients. In the Qianghuo Shengshi Decoction, *Rhizoma Et Radix Notopterygii* and *Radix Angelicae Pubescentis* dispel wind and dampness, promote joint circulation, remove paralysis and relieve pain. *Radix Stephaniae Tetrandrae*, *Saposhnikoviae Radix*, *Ramulus Mori*, *Talcum*, *Semen Coicis* clear heat and dampness, remove paralysis and relieve pain. *Fructus Gardeniae*, *Tangerine Peel*, *Poria*, *Pinelliae Rhizoma*, *Caulis Loniceræ*, *Clematidis Radix Et Rhizoma*, *Herba Siegesbeckiae*, *Gentianae Macrophyllae Radix*, *Tangerine Peel*, *Poria*, *Pinelliae Rhizoma* strengthen the spleen, dry dampness, percolate dampness and water, strengthen the spleen and stomach. *Fructus Gardeniae* clears away heat and dampness, relieves fire and distress. *Caulis Loniceræ*, *Clematidis Radix Et Rhizoma*, *Herba Siegesbeckiae*, *Gentianae Macrophyllae Radix* open the ligaments and promote paralysis and relieve pain, and liquorice root relieves pain



and alleviates urgency, strengthens the spleen and tonifies the qi. The combined treatment of Chinese and Western medicine can exert significant anti-inflammatory effects.

## Conclusions

To summarize, both surgical techniques are efficient in removing the lesion, reducing pain, maintaining spinal stability, encouraging implant fusion, and enabling prognostic inflammatory control. In comparison to OLIF, PLIF features a shorter surgical duration and hospital stay, less intraoperative bleeding, and greater neurological improvement. Nevertheless, OLIF outperforms PLIF in the excision of peri-vertebral abscesses. PLIF is indicated for posterior spinal column lesions, particularly those involving spinal nerve compression in the spinal canal, whereas OLIF is indicated for structural bone deterioration in the anterior column, particularly those with perivascular abscesses. Selection bias exists in the present study due to the small sample size, short observation time, and few evaluation indicators. Therefore, further observational studies with large samples, and multiple index parameters are required to investigate the long-term clinical efficacy.

## Informed Consent

All subjects included in this study have signed informed consent and know the purpose and content of this study.

## Ethics Approval

This clinical study has been approved and approved by the Ethics Committee of The First Affiliated Hospital of Hebei North University (Ethics approval number: JU-LI 20180506).

## Authors' Contributions

Conceptualization: Y.-L. Jia, Y.-L. Yin and X.-M. Yang. Methodology: X.-H. Zuo, Y. Zhang, Y. Yao and X.-M. Yang. Writing - Original Draft Preparation: Y.-L. Jia and X.-H. Zuo. Writing, Review & Editing: Y.-L. Yin and X.-M. Yang. Formal Analysis: Y.-L. Jia and X.-H. Zuo. Supervision: X.-M. Yang.

## ORCID ID

Xinming Yang: 0000-0001-7316-1030

## Data Availability

The datasets used during the present study are available from the corresponding author upon reasonable request.

## Funding

This work was supported by Provincial Government Aid Clinical Medical Talents Cultivation and Basic Research Projects of Hebei Province (361009); Key Project of Technical Research and Achievement Transformation in Health Field of Hebei Province of Hebei Province (zh2018014); Medical Application Technology Tracking Project of Hebei Province (G2018074, GZ2022068); Medical Science Research Project of Hebei Province (20200504).

## Conflict of Interest

All authors declared that they have no financial conflict of interest.

## References

- 1) Shakir R. Brucellosis. *J Neurol Sci* 2021; 420: 117280.
- 2) Dahl MO. Brucellosis in food-producing animals in Mosul, Iraq: A systematic review and meta-analysis. *PLoS One* 2020; 15: e0235862.
- 3) Djangwani J, Ooko Abong G, Gicuku Njue L, Kaindi DWM. Brucellosis: Prevalence with reference to East African community countries - A rapid review. *Vet Med Sci* 2021; 7: 851-867.
- 4) Edao BM, Ameni G, Assefa Z, Berg S, Whatmore AM, Wood JLN. Brucellosis in ruminants and pastoralists in Borena, Southern Ethiopia. *PLoS Negl Trop Dis* 2020; 14: e0008461.
- 5) Liu Z, Wei D, Li Y, Zhou H, Huang D, Guan P. Different Clinical Manifestations of Human Brucellosis in Pregnant Women: A Systematic Scoping Review of 521 Cases from 10 Countries. *Infect Drug Resist* 2020; 13: 1067-1079.
- 6) Roushan MRH, Ebrahimpour S, Afshar ZM, Babazadeh A. Cervical Spine Spondylitis with an Epidural Abscess in a Patient with Brucellosis: A Case Report. *J Crit Care Med (Targu Mures)* 2019; 5: 103-106.
- 7) Chen XW, Xu HG, Liu P, Yang XM, Zhang Y, Li YF. [One-stage transpedicular debridement, posterior internal fixation and fusion for the treatment of senile thoracolumbar tuberculosis]. *Zhongguo Gu Shang* 2020; 33: 454-458.
- 8) Farah K, Peyriere H, Graillon T, Prost S, Dufour H, Blondel B, Fuentes S. Minimally invasive posterior fixation and anterior debridement-fusion for thoracolumbar spondylodiscitis: A 40-case series and review of the literature. *Neurochirurgie* 2020; 66: 24-28.
- 9) Guo X, Han Z, Chen Q, Yang J, Chen F, Guo Q, Lin P, Ni B. Is Initial Posterior Atlantoaxial Fixation and Fusion Applying Bilateral C1-2 Transarticular Screws and C1 Laminar Hooks Reliable for Acute Pediatric Atlantoaxial Instability?: A Minimal 10-Year Analysis of Outcome and Radiological Evaluation. *Spine* 2020; 45: 244-249.
- 10) Jia F, Wang G, Sun J, Liu X. Combined Anterior-Posterior Versus Posterior-only Spinal Fusion

- in Treating Dystrophic Neurofibromatosis Scoliosis With Modern Instrumentation: A Systematic Review and Meta-analysis. *Clin Spine Surg* 2021; 34: 132-142.
- 11) Lee KY, Lee JH, Kang KC, Im SK, Chang DG, Choi SH. Spino-Pelvic Thresholds for Prevention of Proximal Junctional Kyphosis Following Combined Anterior Column Realignment and Short Posterior Spinal Fusion in Degenerative Lumbar Kyphosis. *Orthop Surg* 2020; 12: 1674-1684.
  - 12) Ruoff CM, Kerwin SC, Taylor AR. Diagnostic Imaging of Discospondylitis. *Vet Clin North Am Small Anim Pract* 2018; 48: 85-94.
  - 13) Al-Tawfiq JA, Memish ZA. Antibiotic susceptibility and treatment of brucellosis. *Recent Pat Anti-infect Drug Discov* 2013; 8: 51-54.
  - 14) Al Jindan R. Scenario of pathogenesis and socio-economic burden of human brucellosis in Saudi Arabia. *Saudi J Biol Sci* 2021; 28: 272-279.
  - 15) Bouaziz MC, Bougamra I, Kaffel D, Hamdi W, Ghannouchi M, Kchir MM. Noncontiguous multifocal spondylitis: an exceptional presentation of spinal brucellosis. *Tunis Med* 2010; 88: 280-284.
  - 16) Liu F, Shi SY, Zheng Q, Shen J, Wang YF, Cao TY. [One-stage posterior debridement combined with lumbar-iliac fixation and bone graft fusion for the treatment of lumbosacral tuberculosis]. *Zhongguo Gu Shang* 2020; 33: 166-172.
  - 17) Liu Z, Li W, Xu Z, Zhang Y, Wu Y, Wang X, Zeng H. Treatment of Monosegment Spinal Tuberculosis via Posterior Unilateral Vertebral Lamina Fenestration Debridement and Bone Grafting Fusion Combined with Laminar Reconstruction and Internal Fixation: A Retrospective Case-Control Study with a Minimum 5-Year Follow-Up. *World Neurosurg* 2020; 135: e468-e476.
  - 18) Zou X, Yang H, Ge S, Chen Y, Ni L, Zhang S, Xia H, Wu Z, Ma XY. Anterior Transoral Débridement Combined with Posterior Fixation and Fusion for Atlantoaxial Tuberculosis. *World Neurosurg* 2020; 138: e275-e281.
  - 19) Long W, Gong L, Cui Y, Qi J, Duan D, Li W. Single posterior debridement, interbody fusion, and fixation on patients with continuous multivertebral lumbar spine tuberculosis (CMLSTB). *BMC Musculoskelet Disord* 2020; 21: 606.
  - 20) Machino M, Ando K, Kobayashi K, Ota K, Morozumi M, Tanaka S, Ito K, Kato F, Ishiguro N, Imagama S. A comparative study of two reconstruction procedures for osteoporotic vertebral fracture with lumbar spinal stenosis: Posterior lumbar interbody fusion versus posterior and anterior and combined surgery. *J Orthop Sci* 2020; 25: 52-57.
  - 21) Shen J, Zheng Q, Wang Y, Ying X. One-stage combined anterior-posterior surgery for thoracic and lumbar spinal tuberculosis. *J Spinal Cord Med* 2021; 44: 54-61.
  - 22) Yang H, Gao C, Lu X, Shi J, Wang L, Sun Y, Sun J. Exclusion of Ossified Ligaments Behind C2 Vertebra Combined with Anterior Controllable Antedisplacement and Fusion for Cervical Ossification of the Posterior Longitudinal Ligament Extending to C2 Segment. *World Neurosurg* 2021; 146: e1351-e1359.
  - 23) Zhong Y, Yang K, Ye Y, Huang W, Liu W, Luo J. Single Posterior Approach versus Combined Anterior and Posterior Approach in the Treatment of Spinal Tuberculosis: A Meta-Analysis. *World Neurosurg* 2021; 147: 115-124.
  - 24) Liu Z, Zhang P, Li W, Xu Z, Wang X. Posterior-only vs. combined posterior-anterior approaches in treating lumbar and lumbosacral spinal tuberculosis: a retrospective study with minimum 7-year follow-up. *J Orthop Surg Res* 2020; 15: 99.