

Is there a relationship between low back pain and ligamentum flavum hypertrophy?

A.H. ALI^{1,2}, O. SERHAN³, H. ALI AMER³, H. SALEM ALDOSARI⁴,
A. ALODAIB⁵, T. HAZAAZI⁵, A. ALBOGAMI⁵, A. ALYAMNI⁵, S. ALKANAAAN⁵,
A. ALBASSAM⁵, O. ALALWI⁵, A.A. ALGHAMDI⁵, A.K. ALHUTHAYLI⁶,
A.M. AMANY^{1,7}, H.A. ABOELSOU^{1,7}

¹Anatomy Department, College of Medicine, Prince Sattam Bin Abdulaziz University, Al-Kharj, KSA

²Anatomy Department, Faculty of Medicine, Al-Azhar University, Cairo, Egypt

³Radiology Department, King Khalid Hospital, Ministry of Health, Al-Kharj, KSA

⁴Radiology Department, Wadi Al-Dawasir General Hospital, Ministry of Health, Wadi Al-Dawasir, KSA

⁵College of Medicine, Prince Sattam Bin Abdulaziz University, Al-Kharj, KSA

⁶King Khalid Hospital, Riyadh First Health Cluster, Ministry of Health, Riyadh, KSA

⁷Department of Anatomy and Embryology, Faculty of Medicine (Girls), Al-Azhar University, Cairo, Egypt

ABSTRACT. – OBJECTIVE: A condition known as ligamentum flavum (LF) hypertrophy occurs when the ligamentum flavum (LF) swells as a result of pressures applied to the spine. Among the elderly population, lumbar spinal stenosis is a major cause of pain and disabilities. Numerous studies indicate that lumbar spinal stenosis etiology involves the ligamentum flavum in a major way. This study looks into the relationship between low back pain and ligamentum flavum thickening.

PATIENTS AND METHODS: The imaging tests and case histories of all patients with low back pain who had consecutive magnetic resonance imaging exams performed at the Prince Sattam University and King Khalid hospitals in Al Kharj City will serve as the basis for this retrospective observational study. A radiologist utilized the Pfirrmann grading system, which is based on spinal levels starting from the first lumbar to the first sacral vertebrae, to measure the thickness of the ligamentum flavum in all cases who underwent magnetic resonance imaging (MRI). A correlation between age, hypertrophy of LF, and low back pain was investigated.

RESULTS: There were 79 participants in the study, ages ranging from 21 to 82, 49 of which were men. The patients' average age was 54 years, and 62% of them were men. We found no appreciable variations in LF thickness according to gender. At the L4-L5 and L5-S1 levels, the left LF was noticeably thicker than the right. Moreover, there was a significant difference ($p < 0.05$) in the bilateral LF thicknesses at L5-S1 compared to the comparable sides at L4-L5.

CONCLUSIONS: By evaluating the thickness of LF on magnetic resonance images, we discovered that it may be closely associated with the etiology of pain processes in the spine.

Key Words:

Ligamentum flavum, Stenosis, MRI, Disc degeneration, Low back pain.

Introduction

Cases with lumbar spinal canal stenosis frequently have lower back discomfort and weakness of the lower extremity in addition to neurogenic intermittent claudication¹. When the spinal canal narrows as a result of changes in the physical features of the spine, the nerves become compressed, resulting in these clinical symptoms. The ligamentum flavum (LF) hypertrophy and disc prolapse lower the amount of space in the spinal canal, which compresses the nerves in the dural sac^{2,3}. Even in the absence of a protruding annulus fibrosus, osseous spur or herniated nucleus pulposus, the pathogenesis of lumbar spinal stenosis typically involves hypertrophy of LF, which narrows the spinal canal and compresses the nerve roots and dural sac, causing symptoms. Ligamentum flavum is a well-defined elastic structure made up of 20% collagen and 80% elastic fibers. Hypertrophied ligamentum flavum tissues are characterized by disorganization, degeneration, and reduced levels of elastic fibers⁴. On the other hand, even in the absence of a bulging annulus fibrosus, osseous spurs, or a herniated nucleus pulposus, canal constriction mechanically compresses the nerve root or cauda equina and causes sciatica and lower back pain⁵. Matrix metalloproteinases, age, mechanical stress, and transforming growth

factor-beta are all thought to have a role in ligamentum flavum degeneration⁶. According to some studies^{7,8}, long-term wide segmental movement causes the ligamentum flavum to enlarge, which may play an important role in the development of stenosis and nerve compression. For example, one study found that the ligamentum flavum thickening is associated with disc stenosis, degeneration, aging, and herniation of the disc, and that it is caused by disc degeneration-related vertebral canal deformation rather than ligamentum flavum hypertrophy⁷.

Due to compression of the neural tissue in the spinal canal, patients with lumbar spinal stenosis manifest with neurogenic claudication, radiculopathy, and/or neurological impairment. Decompression surgery needs to be considered the main therapeutic option for individuals who do not respond to conservative therapies, such as anti-inflammatory drugs, physical therapy, and epidural steroid injections. This is especially true for patients whose symptoms are severe⁹.

Regretfully, recurrence of stenotic symptoms at the operative site or at neighboring levels carries an elevated risk of reoperation. Revision surgeries are undesirable as patients experience less favorable outcomes than in the index operation⁹. Revision operations are not preferred because the results are not as good for the patients as they were for the index operation¹⁰. A variety of factors, such as age, activity level, and mechanical stress on the LF, might contribute to LF hypertrophy. An inflammatory response and subsequent development of tissue scarring may be brought on by mechanical stress-induced tissue injury, and the accumulation of these scars may lead to LF hypertrophy.

Therefore, the goal of this study was to investigate the relationship between LF hypertrophy and low back discomfort using enhanced MR imaging.

Patients and Methods

This study received approval from the Ethics Committee of Prince Sattam bin Abdulaziz University Institutional Review Board, January 17-2023 (SCBR-168-2023). The case histories and imaging examinations of all patients with chronic low back pain who underwent MRI exams concurrently at the outpatient clinic of the Prince Sattam bin Abdul Aziz and King Khalid Hospitals between January 2023 and August 2023 served as the basis for this retrospective observational analysis. The study involved 79 participants, 49

of whom were men and whose ages ranged from 18 to 70. Patients with transitional vertebrae, fractures, spine tumors or infections, past operations, deformities like scoliosis or kyphosis, or congenital anomalies, such as spina bifida, were eliminated. Patients with low back pain for at least three months were included. Patients with foraminal or lateral stenosis, instability, a history of lumbar surgery, a history of psychological disorders, and radiologic evidence of other pathologies associated with symptoms like a prominent ruptured disc or infection were excluded from the study. The study measured ligamentum flavum at the level of the lumbar spine using the sagittal and axial planes. Intervertebral spaces were located at the spinal level using T1-weighted sagittal images. For axial pictures, the interslice gap was 1 mm, and the slice thickness was 4 mm. Without obtaining any clinical details, the ligamentum flavum was measured by the same radiologist (AAS). LF thickness values were assessed with Dicom Works version 1.3.5 (Informer Technologies, Inc; Los Angeles, CA, USA). The same radiologist measured each patient's maximum LF thickness in millimeters.

Statistical Analysis

The Statistical Package for Social Science SPSS 24 (IBM Corp., Armonk, NY, USA) was used to perform the statistical analysis. For discrete variables, the data was presented as frequencies and percentages; for continuous variables, the data was presented as means and standard deviations. The correlation between the variables under investigation was measured using Spearman's correlation. Correlation coefficients were calculated using Pearson's correlation test. When applicable, descriptive statistical techniques were employed. The analyses were performed using the Statistical Package for Social Sciences (SPSS) version 16 software (SPSS Inc., Chicago, IL, USA). A p -value < 0.05 was considered significant.

Results

Of the 79 participants, 30 were female and 49 were male. Patients' ages ranged from 21 to 82 years old. The prevalence of ligamentum flavum hypertrophy was more common among elderly patients. Table I shows the participants' demographic distribution – the majority of patients (62%) were men. There were 26 cases (32.9%) of LF hypertrophy. Table II shows the maximum

Table I. Demographic distribution among participants (N = 79).

	Mean (SD)	Percentage
Male	49	62%
Female	30	38%
Age from 21-30	6	7.59%
Age from 31-40	19	24.05%
Age from 41-50	23	29.11 %
Age from 51-82	31	39.24 %
No. of ligamentum flavum hypertrophy	26	32.9 %

and minimum thickness of ligamentum flavum at various levels. The ligamentum flavum's mean (\pm SD) thicknesses at the L4-L5 level were 3.4609 ± 0.48273 and 33.4086 ± 0.52461 mm on the left and right, respectively, as shown in Table III. At the L5-S1 level, they were 3.6128 ± 0.53194 and 3.5539 ± 0.47369 mm, respectively. Gender-related differences in ligamentum flavum thickness

were not statistically significant (independent samples test, $p > 0.05$). In comparison to the right side, the left LF was noticeably thicker at the L4-L5 and L5-S1 levels (Table III). Figure 1 shows the LF thickness at the L4-L5 and L5-S1 levels. Additionally, ligamentum flavum thickening is visible in two of the cases' sagittal MRI sections shown in Figure 2.

Discussion

When it comes to disc surgery, the LF is a crucial structure. In the axial plane, it can be simply divided into the pars interspinalis, pars interlaminaris, and pars capsularis¹⁰. The bulk of the pars interlaminaris should be cut during surgery in order to reveal and decompress the nerve root and dural sac. In the sagittal plane, LF is further separated into superficial and deep components.

Table II. Descriptive statistics among participants.

	Maximum	Minimum	Mean	SD
Age	82 y	21 y	44.61	13.562
Right L4- L5 (mm)	4.86	1.75	3.4085	0.53196
Left L4- L5 (mm)	4.87	1.86	3.4628	0.48273
Right L5- S1 (mm)	5.04	2.41	3.5540	0.47369
Left L5- S1 (mm)	5.52	1.84	3.6129	0.53195

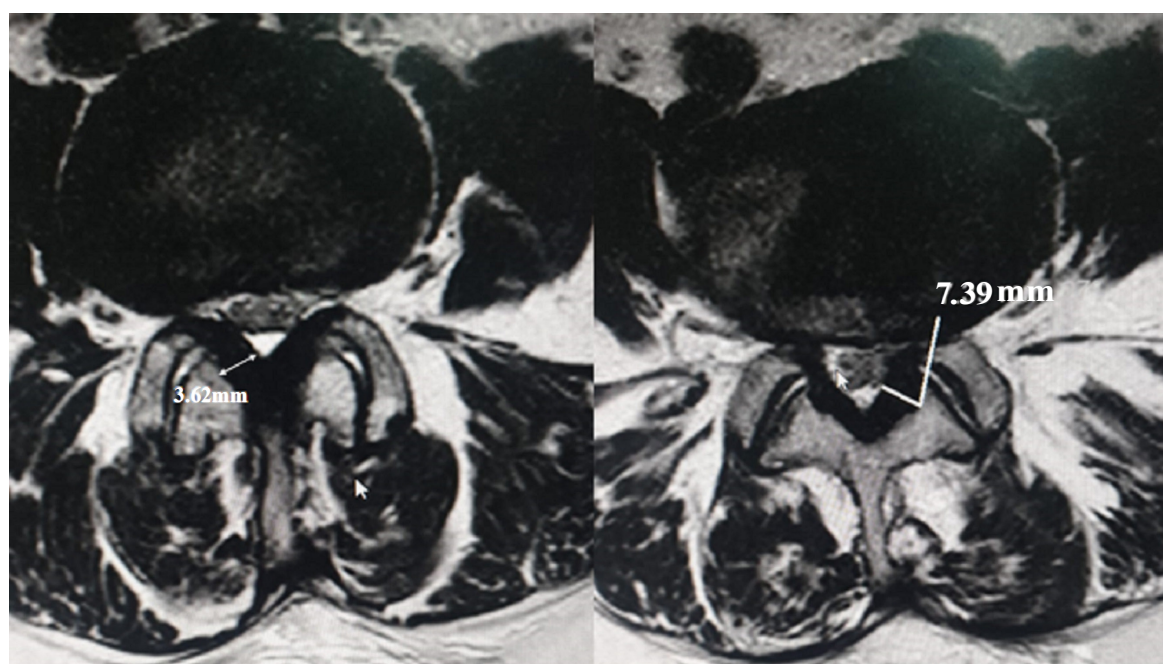
**Figure 1.** Metric analysis in T2-weighted MR sequence of a ligamentum flavum at L4-L5 level in the axial plane.

Table III. LF thickness (mm) comparison.

Level	Right (mm)	Left (mm)	<i>t</i>	<i>df</i>	<i>p</i>
L4-L5	3.4086 ± 0.52461	3.4609 ± 0.48273	3.347	319	0.002
L5-S1	3.5539 ± 0.47369	3.6128 ± 0.53194	3.294	319	0.001

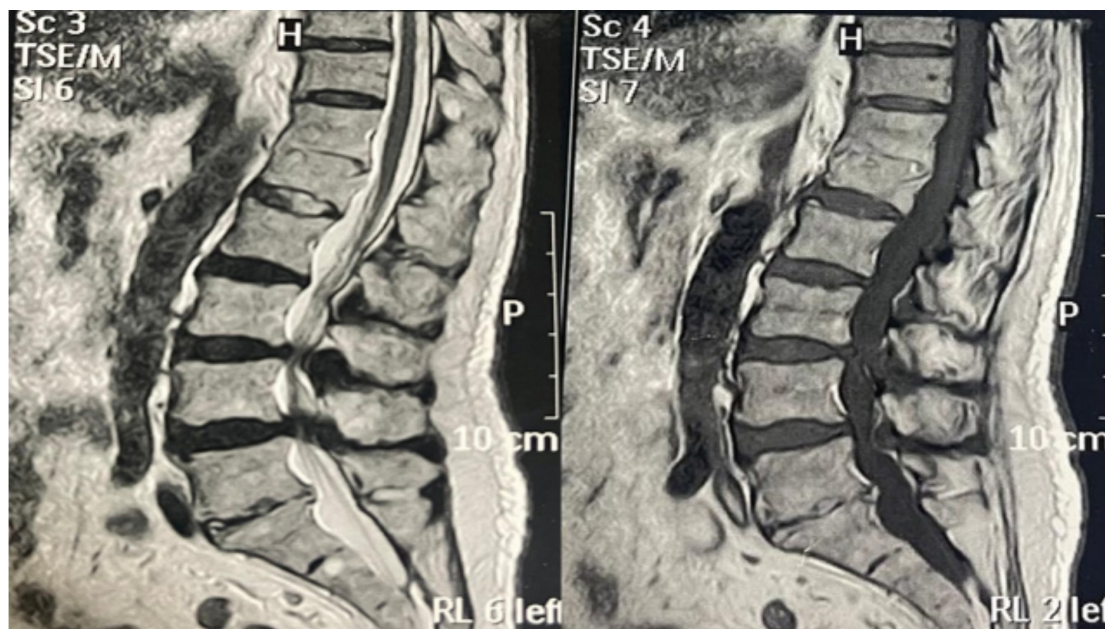


Figure 2. Sagittal T2WIs of a patient show ligamentum flavum thickening.

Filling the interlaminar gap is a fibrous, light-yellow tissue that is the superficial component of the ligamentum flavum. It has a thickness of 2.5-3.5 mm. The ventral surface is formed by a thin, dark yellow structure known as the deep component. It has a thickness of about 1 mm. Spinal canal imaging not only aids in the detection of rare diseases but also advances the development of innovative surgical techniques. In particular, minor surgical intervention can be used to treat neurological symptoms caused by “pure LF pathologies”¹¹.

We measured the LF thickness in patients with low back pain using MR imaging and specially designed spine-specific assessment procedures. It is unclear what causes the ligamentum flavum to thicken. It is still debated whether the thickening is due to tissue distortion or hypertrophy. Some research claims that the ligament’s hypertrophy is the cause of the canal’s narrowing, while others contend that the LF’s abnormalities inside the spinal canal squeeze the nerve tissues^{12,2}. Furthermore, although “hypertrophy” and “thickening” do not always mean the same thing, these terms are often used interchangeably in the literature¹³. Research

on the ligamentum flavum’s pathophysiology has focused on the variables that impact its thickness, primarily segmental instability. Only one previous study indicated that the thickening of the ligamentum flavum was due to hypertrophied or malformed tissue, and authors questioned if this was connected to disc degeneration observed during MRI tests¹³. Two primary explanations account for the emergence of hypertrophic ligamentum flavum. Ligamentum flavum hypertrophy is attributed to fibrotic alterations and supporting evidence of collagen production. Elevated expression of these biomarkers stimulates fibroblasts to produce collagen and promotes the deterioration of elastic fibers¹⁴. These mechanisms are a component of the spine’s degenerative process. Canal narrowing results from ligamentum flavum decreased flexibility and protrusion into the canal space despite its normal thickness¹⁵. Histological studies also demonstrated the loss of elastic fibers and their conversion to ligamentum flavum cartilaginous tissue¹⁶. In 79 patients, we assessed the LF thickness at the L4-L5 and L5-S1 levels. Since more than 95% of disc and stenotic spinal canal surgeries are done at these

levels, these intervertebral levels were selected. Due to their dependent position and weight-bearing characteristics, these levels are also the ones of the spine that are most frequently damaged, which is another rationale for their selection¹⁷. According to our research, age or gender did not significantly affect the LF thickness. In contrast, another study¹⁸ that examined the mean thickness of the LF in 77 participants ranging in age from ten to eighty-five years discovered that, although the thickness at the L5/S1 level did not change significantly after the age of 30, the thickening at the L4/5 level increased steadily with age. At the same level, there was a noticeable variation in LF thickness between the contralateral sides.

This study suggests that there may be an asymmetry associated with LF thickness. Anatomical variances, such as those found in our study, and changes in posture can have an impact on surgical decision-making and surgical outcome. Prior to and during surgery, all anatomical, morphological, and postural concerns must be taken into consideration. Because the patient is in a supine posture during the surgical operation, positional buckling, particularly in the extended position, may be overlooked. If preoperative imaging slices show this type of result, LF is excised extensively.

When interpreting the results, it is important to take into account the limitations of our study. First and foremost, a variety of conditions, including facet osteoarthritis and spondylolisthesis, lead to spinal canal narrowing beyond the thickness of the LF. These further variables should also be taken into account in the analysis in order to have a deeper understanding of the pathophysiology of the canal narrowing. There were only a few people in our study group, and there was no control group.

Consequently, it was not possible to assess the relationship between LF thickness and spinal canal stenosis symptoms in the context of our investigation. Furthermore, a thickness of greater than 3.5 mm, which denotes a limited range of LF thickness seen in earlier investigations, was used to characterize the thickening of the LF.

Conclusions

An essential anatomical feature that can result in low back and/or leg pain is the ligamentum flavum, which can also induce spinal and/or lateral recess stenosis. The thickness of the ligamentum flavum is a significant determinant in low back pain. This finding may support the reactive na-

ture of the LF to higher mechanical stresses at the lower lumbar levels, as well as the degenerative process in the LF that happens with aging. Therefore, in the event that spinal and/or lateral recess stenosis is suspected, the thickness of the LF and, in particular, changes in location should be measured carefully before surgery.

Conflict of Interest

The authors declared no potential conflicts of interest with respect to the research, authorship, and/or publication of this article.

Funding

This study was supported by the Prince Sattam bin Abdulaziz University project number (PSAU/2023/R/1444).

Acknowledgments

The authors thank Prince Sattam bin Abdulaziz University for funding this study (project number PSAU/2023/R/1444). In addition, we thank those who participated and contributed to the study.

Ethics Approval

This study received approval from the Ethics Committee of Prince Sattam bin Abdulaziz University Institutional Review Board, January 17-2023 (SCBR-168-2023).

Informed Consent

Not applicable due to the retrospective nature of the study.

Availability of Data and Materials

The data are available upon request from the corresponding author.

ORCID ID

A.H. Ali: 0000-0002-1195-5684
O. Serhan: 0009-0008-0385-3435
H. Ali Amer: 0009-0004-3692-2290
H. Salem Aldosari: 0009-0006-7903-7528
T. Hazazi: 0009-0000-0039-9697
A. Alodaib: 0009-0005-8065-979X
A. Albogami: 0009-0007-3616-9296
A. Albassam: 0009-0003-7812-162X
O. Alalwi: 0009-0002-0706-5803
A. Alghamdi: 0009-0007-8197-6222
A. Alhuthayli: 0009-0001-7946-9631
A.M. Amany: 0000-0002-6166-3700
H. Aboelsoud: 0000-0002-7736-414X

References

- 1) Kim K, Shin KM, Hunt CL, Wang Z, Bauer BA, Kwon O, Lee JH, Seo BN, Jung SY, Youn Y, Lee SH, Choi JC, Jung JE, Kim J, Qu W, Kim TH, Eldridge JS. Nonsurgical integrative inpatient treatments for symptomatic lumbar spinal stenosis: a multi-arm randomized controlled pilot trial. *J Pain Res* 2019; 28: 1103-1113.
- 2) Sakamaki T, Sairyo K, Sakai T, Tamura T, Okada Y, Mikami H. Measurements of ligamentum flavum thickening at lumbar spine using MRI. *Arch Orthop Trauma Surg* 2009; 129: 1415-1419.
- 3) Kim J, Kwon WK, Cho H, Lee S, Lee JB, Park JY, Jin DU, Jung EY, Hur JW. Ligamentum flavum hypertrophy significantly contributes to the severity of neurogenic intermittent claudication in patients with lumbar spinal canal stenosis. *Medicine (Baltimore)* 2022; 9: e30171.
- 4) Chen J, Liu Z, Zhong G, Qian L, Li Z, Qiao Z, Chen B, Wang H. Hypertrophy of ligamentum flavum in lumbar spine stenosis is associated with increased miR-155 level. *Dis Markers* 2014; 2014: 786543.
- 5) Kreiner DS, Shaffer WO, Baisden JL, Gilbert TJ, Summers JT, Toton JF, Hwang SW, Mendel RC, Reitman CA; North American Spine Society. An evidence-based clinical guideline for the diagnosis and treatment of degenerative lumbar spinal stenosis (update). *Spine J* 2013; 13: 734-743.
- 6) Sugimoto K, Nakamura T, Tokunaga T, Uehara Y, Okada T, Taniwaki T, Fujimoto T, Mizuta H. Matrix metalloproteinase promotes elastic fiber degradation in ligamentum flavum degeneration. *PLoS One* 2018; 13: e0200872.
- 7) Altinkaya N, Yildirim T, Demir S, Alkan O, Sarica FB. Factors associated with the thickness of the ligamentum flavum: is ligamentum flavum thickening due to hypertrophy or buckling? *Spine (Phila Pa 1976)* 2011; 15: E1093-E1097.
- 8) Zhu X, Qiu Z, Liu Z, Shen Y, Zhou Q, Jia Y, Sun X, Li S. CT-Guided Percutaneous Lumbar Ligamentum Flavum Release by Needle Knife for Treatment of Lumbar Spinal Stenosis: A Case Report and Literature Review. *J Pain Res* 2020; 13: 2073-2081.
- 9) Deer T, Sayed D, Michels J, Josephson Y, Li S, Calodney AK. A Review of Lumbar Spinal Stenosis with Intermittent Neurogenic Claudication: Disease and Diagnosis. *Pain Med* 2019; 1; 20: S32-S44.
- 10) Griffka J, Witte H, Schulze H, Heers G, Bohlen J, Recknagel S. Das lumbale Ligamentum flavum. Anatomische Besonderheiten in Hinsicht auf die Mikrodiskotomie [The lumbar ligamentum flavum. Anatomic characteristics with reference to microdiscotomy]. *Z Orthop Ihre Grenzgeb* 1997; 135: 328-334.
- 11) Wang VY, Kanter AS, Mummaneni PV. Removal of ossified ligamentum flavum via a minimally invasive surgical approach. *Neurosurg Focus* 2008; 25: E7.
- 12) Park JB, Chang H, Lee JK. Quantitative analysis of transforming growth factor-beta 1 in ligamentum flavum of lumbar spinal stenosis and disc herniation. *Spine (Phila Pa 1976)* 2001; 26: E492-E495.
- 13) Abbas J, Hamoud K, Masharawi YM, May H, Hay O, Medlej B, Peled N, Hershkovitz I. Ligamentum flavum thickness in normal and stenotic lumbar spines. *Spine (Phila Pa 1976)* 2010; 35: 1225-1230.
- 14) Zhang K, Sun W, Liu XY, Zhao CQ, Li H, Sun XJ, You-Zhuan X, Ding W, Zhao J. Hypertrophy and Fibrosis of the Ligamentum Flavum in Lumbar Spinal Stenosis is Associated With Increased Expression of LPA and LPAR1. *Clin Spine Surg* 2017; 30: E189-E191.
- 15) Bagley C, MacAllister M, Dosselman L, Moreno J, Aoun SG, El Ahmadi TY. Current concepts and recent advances in understanding and managing lumbar spine stenosis. *F1000Res* 2019; 8: F1000 Faculty Rev-137.
- 16) Yoshida M, Shima K, Taniguchi Y, Tamaki T, Tanaka T. Hypertrophied ligamentum flavum in lumbar spinal canal stenosis. Pathogenesis and morphologic and immunohistochemical observation. *Spine (Phila Pa 1976)* 1992; 17: 1353-1360.
- 17) Frost BA, Camarero-Espinosa S, Foster EJ. Materials for the Spine: Anatomy, Problems, and Solutions. *Materials (Basel)* 2019; 12: 253.
- 18) Sairyo K, Biyani A, Goel V, Leaman D, Booth R Jr, Thomas J, Gehling D, Vishnubhotla L, Long R, Ebraheim N. Pathomechanism of ligamentum flavum hypertrophy: a multidisciplinary investigation based on clinical, biomechanical, histologic, and biologic assessments. *Spine (Phila Pa 1976)* 2005; 30: 2649-2556.