

Minimally invasive technique for curettage of chondroblastoma using endoscopic technique

C. ERRANI, F. TRAINA, M. CHEHRASSAN, D. DONATI, C. FALDINI

Orthopaedic Service, Rizzoli Institute, Rizzoli-Sicilia, Bagheria (PA), Italy

Abstract. Chondroblastoma is a rare benign bone tumor. The treatment for chondroblastoma usually consists of curettage of the lesion and packing the tumor cavity with bone grafts or bone cement. However, chondroblastomas are known to recur in 10% to 20% of cases after excision, possibly because the incomplete removal of pathological tissue at surgery.

We present a case of chondroblastoma in the distal femur treated by endoscopic curettage, which allowed a complete resection of tumor tissue and a minimal damage of the bone. The patient had relief of symptoms, rapid function restoration and no local recurrence.

Endoscopic curettage is a promising new treatment for chondroblastoma. In fact, the extra-articular technique enters the tumor cavity via a tunnel drilled through the medullary canal, allowing to visualize possible residual tumor tissue or defects of the articular surface, without violating the joint and without taking away a much bigger cortical window.

Key Words:

Benign bone tumors, Chondroblastoma, arthroscopy, Endoscopic curettage.

Introduction

Aggressive benign bone tumors require treatment by curettage of the lesion and packing of the cavity with bone grafts or bone cement. Remove the pathological tissue by a wide bone exposure is usually mandatory to avoid the risk of local recurrence¹.

This report present an innovative minimally invasive technique for curettage and packing of chondroblastoma in the distal femur performed by a small bone window and endoscopic inspection of the tumor cavity by an arthroscope.

The purpose is to demonstrate that endoscopy resection can be used safely and effectively for the treatment of chondroblastoma.

Case Report

A 15-years old girl presented with a 6 months history of local swelling and pain localized to the left knee joint. There was no history of injury. Plain radiographs showed a lytic lesion in the medial aspect of the lateral femoral condyle (Figure 1). Further evaluation with MRI scan confirmed a 2 x 3 cm focal, well-circumscribed lesion with a sclerotic bony margins, which was located entirely within the epiphysis (Figure 2). CT scan study showed that cortical bone was thinned and interrupted (Figure 3). A CT guided trocar biopsy confirmed the diagnosis of chondroblastoma.

Surgery was performed under spinal anesthesia with the patient in the supine position on the operating table with a tourniquet placed on the thigh. Distal lateral approach of the left thigh was made with inclusion of the previous needle biopsy insertion point.

Under fluoroscopy control by insertion of the hand trocar the correct direction of the tunnel was confirmed. Using a high-speed burr a 1.5 x 1.5 cm the orifice of the canal was performed. Subsequently, by a finer high-speed burr a tunnel was drilled down into the lesion. A brownish tumor tissue was removed with a curette from the cavity of the lesion. The canal was opened and expanded into the tumor cavity. Blinded curettage was performed using a medium curette.

Using arthroscopy instruments, the precise inspection and curettage of the tumor cavity was planned. The cavity contained a brownish, soft material clearly differentiated from surrounding bone. The remaining tumor was visualized and removed under endoscopic control (Figure 4). After all gross tumor was removed, the cavity was then burred with a high-speed burr and washed until all pathologic tissue was removed. Integrity of the cavity was checked and a cotton swab with phenol was used as a local adjuvant. Walls of the

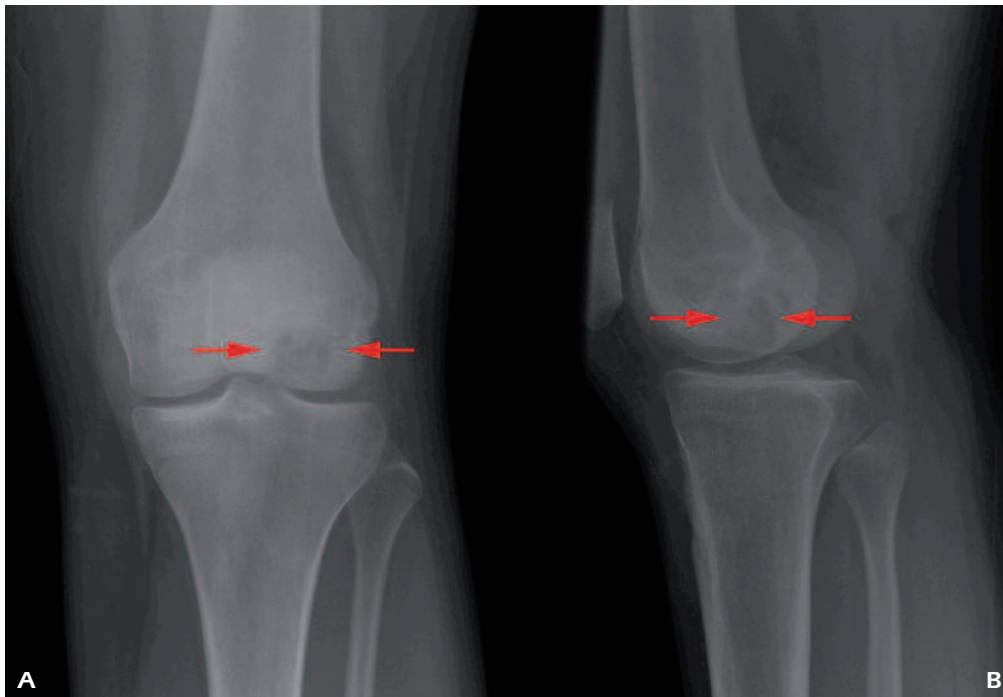


Figure 1 Posteroanterior (A) and lateral (B) radiographs of the knee show an osteolytic lesion of the distal femur (narrows).

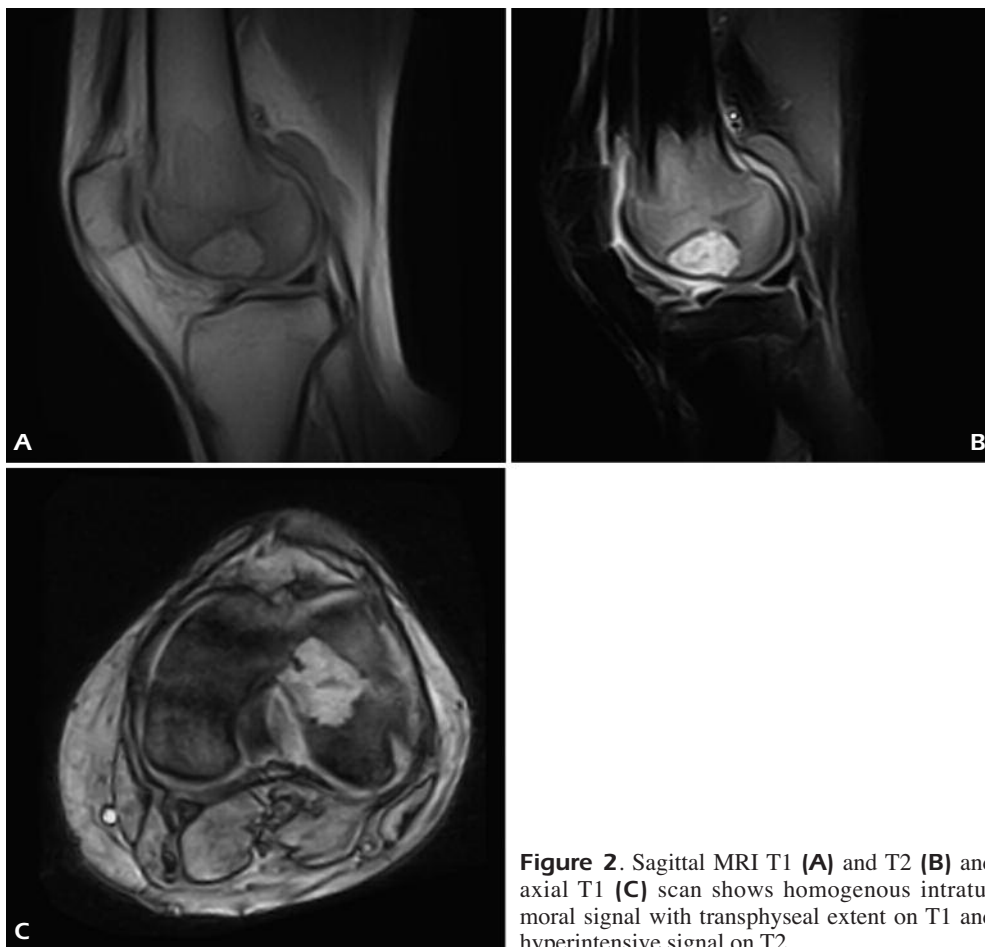


Figure 2. Sagittal MRI T1 (A) and T2 (B) and axial T1 (C) scan shows homogenous intratumoral signal with transphyseal extent on T1 and hyperintense signal on T2.

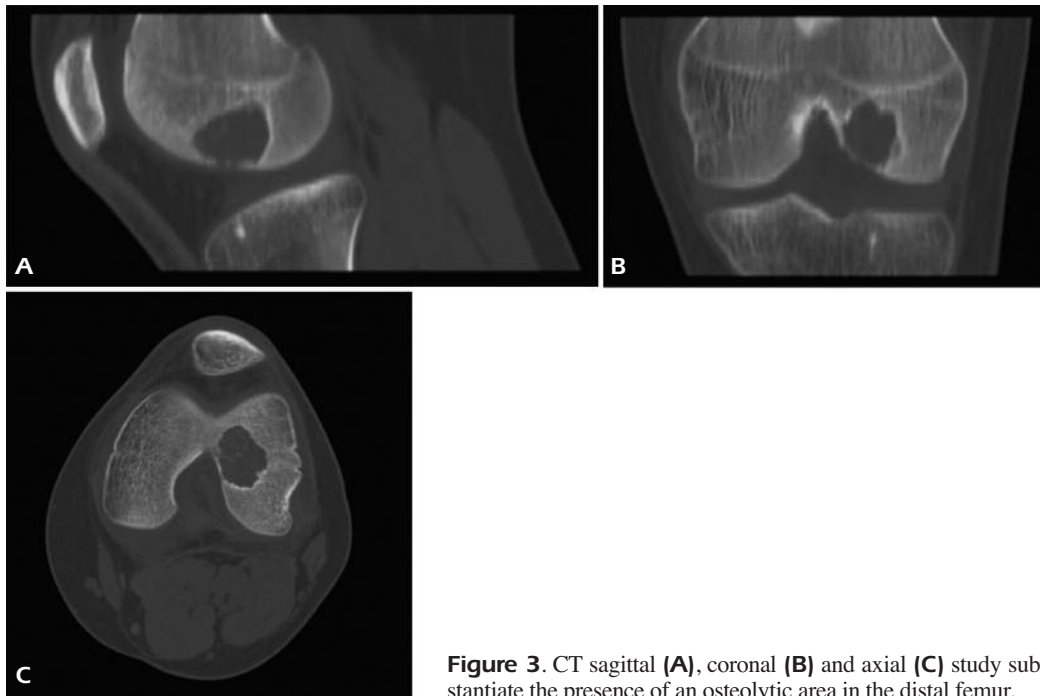


Figure 3. CT sagittal (A), coronal (B) and axial (C) study substantiate the presence of an osteolytic area in the distal femur.

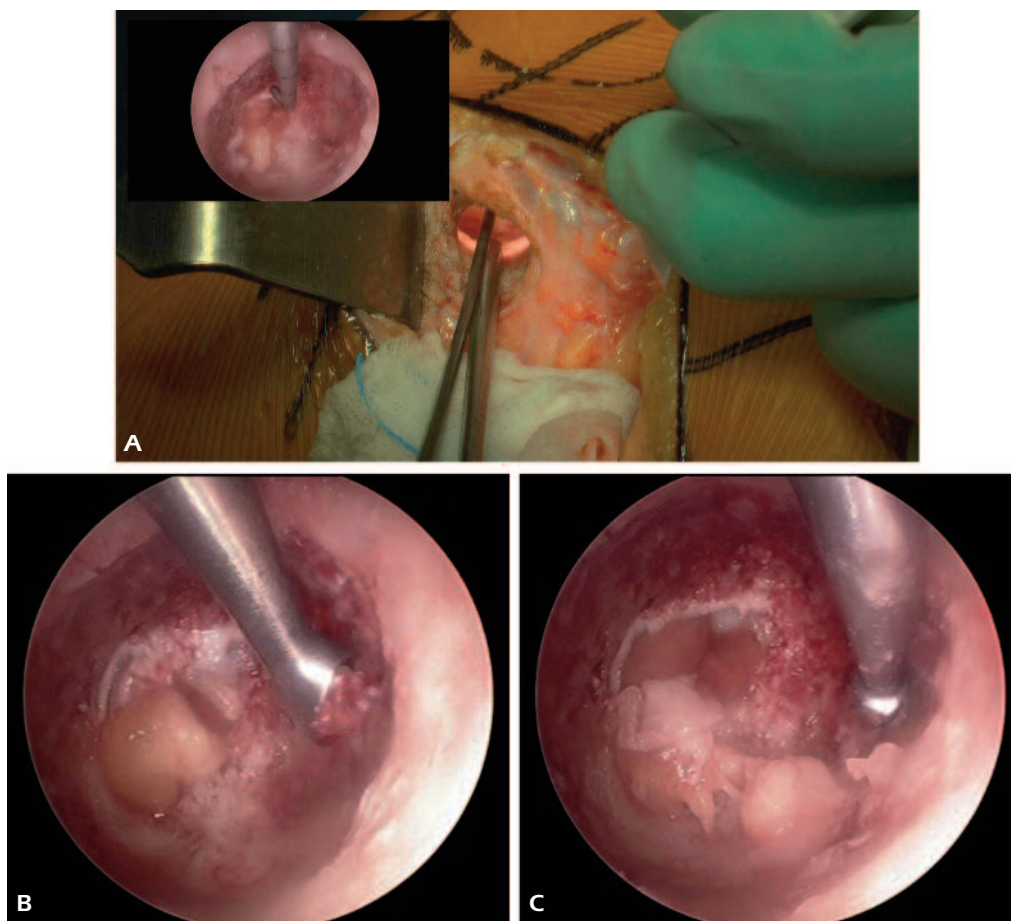


Figure 4. Intraoperative view of minimally invasive endoscopic technique; (A) small circular window permits endoscopic approach, (B) curettage and (C) high speed burring of the lesion under direct endoscopic view.

cavity were soaked by phenol. Subsequently alcohol was used as a second local adjuvant. Finally, the cavity was washed abundantly with normal saline. Distal cortical defect was identified and a piece of absorbable gelatin sponge was placed to cover the cortical defect to prevent cement penetration inside the joint. The residual cavity was filled with bone cement. A drainage tube was inserted and the wound was closed anatomically in multiple layers. Post-operative radiographs demonstrated the refilling of tumor cavity and tunnel with bone cement (Fig. 5). The patient was discharged 3 days post-operatively full weight-bearing. The patient improved rapidly and at 1 year after operation, the knee is pain free and the patient had a full motion of her knee joint without radiological evidence of local recurrence.

Discussion

In our present report, chondroblastoma of the distal femur was treated by curettage of the lesion and packing the tumor cavity with bone cement using a minimally invasive technique. Thanks to this technique, the curettage could be performed by small bone window, and the arthroscope allowed a complete curettage of tumor tissue.

Chondroblastoma is a benign tumor of bone composed of chondroblasts. Typically, the tumor originates in an epiphysis or apophysis. Chondroblastoma is uncommon and prefers the male sex by 2 to 1, typically occurring in the second decade of life. Pain is the principal symptom, usually referred to a joint with mild functional impairment of the joint^{2,3}.

The treatment for chondroblastoma usually consists of curettage of the lesion and packing the tumor cavity with bone grafts or bone cement, using open approaches with large bone window. However, chondroblastomas are known to recur in 10% to 20% of cases after excision, possibly because the incomplete removal of pathological tissue at surgery^{2,3}. Percutaneous radiofrequency ablation is an alternative to surgery for treatment of selected chondroblastomas⁴. However, this procedure is effective and safe only for small lesions. In fact, in a series of 17 patients described by Rybak et al⁴, the lesions ranged from 0.8 to 2.5 (mean 1.4). There was one recurrence and a case of delayed collapse of the articular cortex in the largest lesions of their series. Thus, the authors suggest that larger lesions beneath weight-bearing surfaces should be approached with caution due to an increased risk of articular collapse and recurrence.

Because of this concern, an endoscopy was performed in the present case, which allowed a complete resection of tumor tissue with minimal damage to healthy bone.

Previous few reports have reported minimally invasive approaches using an arthroscopic technique for the treatment of chondroblastoma²⁻⁷.

Some reports have described arthroscopically assisted excision of chondroblastoma involving proximal tibia⁵, as well as chondroblastoma of distal femur² and femoral head⁶. However, removal of bone tumors using an arthroscope instruments risks seeding the entire joint, potentially may lead to adverse consequences⁸. Moreover, another disadvantage of this technique is the possible cartilage damage during the tumor excision¹.

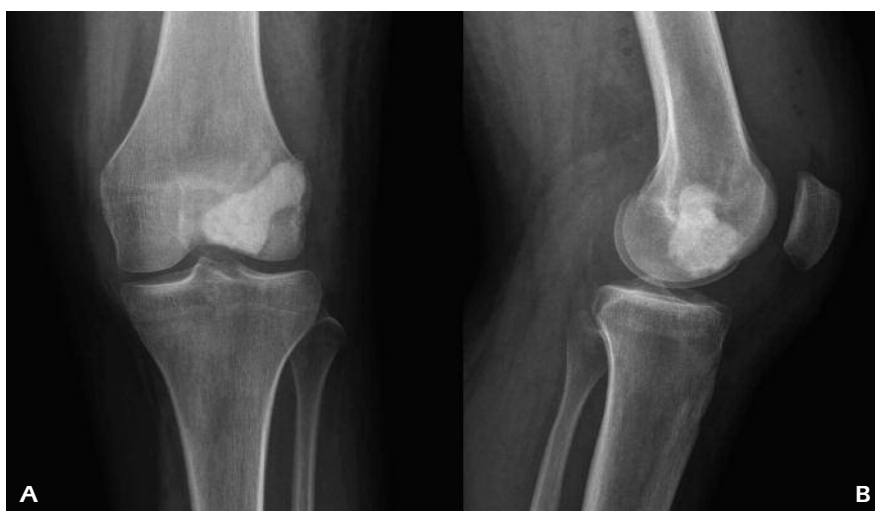

Figure 4. Intraoperative view of minimally invasive endoscopic technique; **(A)** small circular window permits endoscopic approach, **(B)** curettage and **(C)** high speed burring of the lesion under direct endoscopic view.

Otsuka et al³ reported a case of a chondroblastoma in the calcaneus treated with a secondary aneurysmal bone cyst treated by endoscopic curettage. However, this report seems to describe a needle aspiration of an aneurysmal bone cyst more than a curettage of a chondroblastoma.

Stricker SJ¹ reported an endoscopic curettage of femoral head chondroblastoma, describing three cases excised using extrarticular endoscopic approach. This technique allowed to avoid hip arthrotomy plus a cortical window in the femoral head. At an average follow-up of 25 months, all three femoral head tumors have healed without recurrence and with no complications related to the approach. However, the technique described by Stricker does not provide for the simultaneous introduction of the arthroscope and other instruments, such as the curette or a high speed burr.

Conclusions

We present a case of 15 year-old female with a chondroblastoma of the left distal femur treated by endoscopic curettage. Using a small window in the bone, the endoscopy permitted to view the tumor cavity in a complete manner thus removing residual pathological tissue. Furthermore, it was possible to highlight a defect of the articular surface so as to avoid violating the articulation. Therefore, bone cement may be packed into the tumor cavity without fear of subsequent leakage into the joint space.

Our report confirms that minimally invasive technique using an arthroscope is well suited method for access to lesions in difficult juxta-articular locations. In fact, direct arthroscopic visualization allows safer and less destructive excision. The extra-articular technique enters the tumor cavity via a tunnel drilled through the medullary canal, allowing to visualize possible residual tumor tissue or defects of the articular

surface, without violating the joint and without taking away a much bigger cortical window.

To our knowledge, this is the first reported endoscopic curettage of benign bone tumors, using an arthroscope. We feel that this minimally invasive approach can be a promising new technique not only for the treatment of chondroblastoma but also for the treatment of other benign bone tumors.

Conflict of Interest

The Authors declare that there are no conflicts of interest.

References

- 1) STRICKER SJ. Extraarticular endoscopic excision of femoral head chondroblastoma. *J Pediatr Orthop* 1995; 15: 678-681.
- 2) BAL BS, JONES L. Arthroscopic resection of chondroblastoma in the knee. *Arthroscopy* 1995; 11: 216-219.
- 3) OTSUKA T, KOBAYASHI M, YONEZAWA M, KAMIYAMA F, MATSUSHITA Y, MATSUI N. Treatment of chondroblastoma of the calcaneus with a secondary aneurysmal bone cyst using endoscopic curettage without bone grafting. *Arthroscopy* 2002; 18: 430-435.
- 4) RYBAK LD, ROSENTHAL DI, WITTIG JC. Chondroblastoma: radiofrequency ablation--alternative to surgical resection in selected cases. *Radiology* 2009; 251: 599-604.
- 5) COHEN B, KHAN TH, DANDY DJ. Arthroscopic resection of chondroblastoma of the knee. *Arthroscopy* 1992; 8: 370-372.
- 6) THOMPSON MS, WOODWARD BS. The use of the arthroscope as an adjunct in the resection of chondroblastoma of the femoral head. *Arthroscopy* 1995; 11: 106-109.
- 7) AMENDOLA L, CAPPUCCIO M, BORIANI L, GASBARRINI A. Endoscopic excision of C2 Osteoid Osteoma: a technical case report. *Eur Spine J* 2013; 22(Suppl 3): S357-362.
- 8) BAHAMONDE L, CATALAN J. Bone tumors around the knee: risks and benefits of arthroscope procedures. *Arthroscopy* 2006; 22: 558-564.