

# The importance of anatomical region of local anesthesia for prostate biopsy; a randomized clinical trial

H. AKDERE, K.M. BURGAZLI<sup>1</sup>, T. AKTOZ, A. ACIKGOZ<sup>2</sup>,  
M. MERICLILER<sup>1</sup>, A.S. GOZEN<sup>3</sup>

Department of Urology, Faculty of Medicine, Trakya University, Edirne, Turkey

<sup>1</sup>Department of Internal Medicine and Angiology, Wuppertal Research and Medical Center, Wuppertal, Germany

<sup>2</sup>Department of Urology, Medikal Park Private Hospital, Samsun, Turkey

<sup>3</sup>Department of Urology, SLK Kliniken Heilbronn, University of Heidelberg, Germany

**Abstract.** – **INTRODUCTION:** In our study, the efficiency and reliability of lidocaine (1 cc/1%) application during transrectal ultrasound-guided (TRUS) prostate biopsy to levatores prostate was studied. Levatores prostate was visualized on a cadaver dissection previously.

**PATIENTS AND METHODS:** Eighty outpatients with lower urinary tract complaints or were suspected clinically to have prostate cancer were submitted to TRUS-guided prostate biopsy. The ages of outpatients were ranging from 45 to 81. Patients were randomized in 2 groups: Group-I, with 40 patients submitted to local anesthesia by periprostatic injection of 1 cc 1% lidocaine before biopsy; and group-II, with 40 controls the biopsy was performed without local anesthesia. The anatomical region for anesthesia was determined via dissection. The name of this anatomical region is levatores prostatae and it has got high nerve density. The process was explained to the patients and their approvals were obtained. Levatores prostatae was detected with TRUS before biopsy. Pain; related to digital rectal examination (DRE), probe insertion or biopsy, was scored via visual analog scale (VAS). The patients were evaluated about side effects of lidocaine and early and late complications of biopsy as well.

**RESULTS:** Both groups were similar in terms of mean age, PSA levels, prostate volume and VAS scores ( $p > 0.05$ ). As for VAS score, on the group submitted to anesthesia was determined  $2.34 \pm 1.08$ , while for VAS score on the group submitted conventional biopsy was determined  $5.8 \pm 1.6$ . Between two groups, there was a statistical difference in terms of VSA score ( $p < 0.05$ ); but there was no statistical difference about early and late complications of biopsy.

**CONCLUSIONS:** The periprostatic blockage use is clearly associated with more tolerance and patient comfort during TRUS-guided biopsy. Owing to the local anesthesia introduced to the

periprostatic nerve bundle localization in levatores prostate area, the patients could tolerate the pain better.

*Key Words:*

Prostate, Region, Lidocaine, Pain, TRUS, Biopsy

## Introduction

Prostate cancer is the most common tumor in men and second cause of death<sup>1</sup>. Transrectal ultrasound-guided prostate biopsy has become essential in diagnostic investigation of patients with clinical suspicion of prostatic neoplasia on physical examination, or elevation of the prostatic specific antigen (PSA)<sup>2,3</sup>. Although the biopsy could be tolerated by most of men, 65-90% of patients had pain during the exam and 19% of them refused the biopsy<sup>4,5</sup>. The common opinion in recent years is that sextant biopsy is no longer sufficient to diagnose the prostate cancer. Thus, taking 14 to 16 core biopsies is recommended<sup>6,7</sup>. Discomfort during prostate biopsy is proportional to the number of biopsies; therefore, 14 to 16 core biopsies are recommended<sup>8,9</sup>, and the need for anesthesia is increasing for an optimal biopsy<sup>10</sup>. For adequate pain control during the biopsy, various techniques have been described such as rectal lidocaine gel implementation, periprostatic nerve block, intraprostatic local anesthesia, nitrous oxide inhalation, caudal anesthesia, tramadol implementation. However, recent studies recommended the periprostatic nerve block as the gold standard for pain control<sup>11-13</sup>.

In order to ensure adequate pain control, local anesthesia should be applied in correct technical. In the studies the amount and the effectiveness of

**Table I.** Patient characteristics.

	Group I (with anesthesia)	Group II (without anesthesia)
Number of patients	40	40
Age (year) (ort ± SD)	61.97 ± 13.4	59.03 ± 13.4
PSA (ng/ml) (ort ± SD)	6.69 ± 3.6	6.26 ± 2.47
Prostate volume (cc) (ort ± SD)	50.31 ± 21.23	49.02 ± 17.72
Prostat Ca (%)	20	17

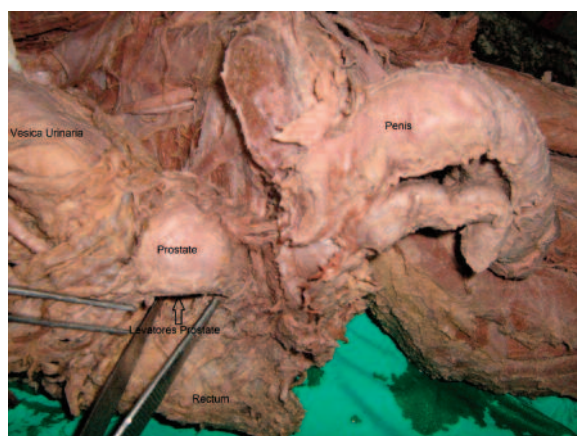local anesthetic agent has been reported to vary according to the anatomical localizations used<sup>14</sup>. In this work, the most appropriate location for local anesthesia was determined to be the neural anatomic area between rectal mucosa and prostate capsule which has the highest nerve density. Lower than standard dose of lidocaine (1 ml of 1%) was applied to this pre-determined anatomical location with transrectal ultrasound (TRUS) and its efficiency and reliability in pain control during the biopsy were examined.

### Patients and Methods

Eighty patients with lower urinary tract symptoms referred to Urology Clinic were included in the study. Patient characteristics are shown in Table I. Indications for TRUS guided (TRUSG) needle biopsy were determined as PSA  $\geq$  2.5 ng/ml and suspected prostate cancer on DRE (digital rectal examination). Informed consents were taken from patients and patients were informed about visual analogue scale (VAS). Patients who had a prostate biopsy previously, a radical prostatectomy operation, who had acute prostatitis, lidocaine allergy, chronic pain syndrome, recto-anal pathology or bleeding diathesis were excluded. In addition, patients who had a prostate weight over 90 g and/or median lobe greater than 30 g were excluded from the study because an accurate anatomic localization could not be determined. Patients were randomized in two groups after biopsy were planned. Anticoagulant or aspirin medications were discontinued 1 week before the procedure. All patients were given prophylactic antibiotic therapy (Ciprofloxacin 500 mg 2 × 1) 1 day prior to and 2 days after the biopsy. In the morning of the biopsy all patients had rectal enema with 10 g Libalaks<sup>®</sup>. Patients had DRE before the biopsy. Biopsy was performed by the same physician on left lateral decubitus position with 7.5 MHz Shimadzu SDU-1200 labeled TV11R-055U rectal probe (Tokyo, Japan).

Prior to study, pelvic dissections were performed in the dissection room belonging to Anatomy on 8 cadavers revealing periprostatic structures. On these structures, the area with condensed periprostatic nerve fibers were assessed visually (Figure 1). In this area; the anterior fibers of the levator ani muscle, which located lateral of prostate, crossed urogenital diaphragm. And also this area is rich with fat and connective tissues. This area at the present day (American Urologic Association, AUA 2011) coincides superficial area referred rectally as trigger Zone. In patients with chronic prostatitis and chronic pelvic pain related to levator spasm, local pressing upon this area (Trigger point wand) is used therapeutically. This area is rich in sensorial and motor nerve fibers originating especially in S4 level. Using TRUS and magnetic resonance (MR) to localize the area, this area is defined clinically on patients.

First longitudinal plane imaging was made by TRUS. Twenty-two gauge needles were introduced guided by TRUS with proper angle on linea dentate caudally. Mucosa was passed with needle 4 centimeters above this line. 0.5 ml of lidocaine was injected left and right sides of the point which is in the middle of the imaginary



**Figure 1.** Levatores prostate area on cadaver.

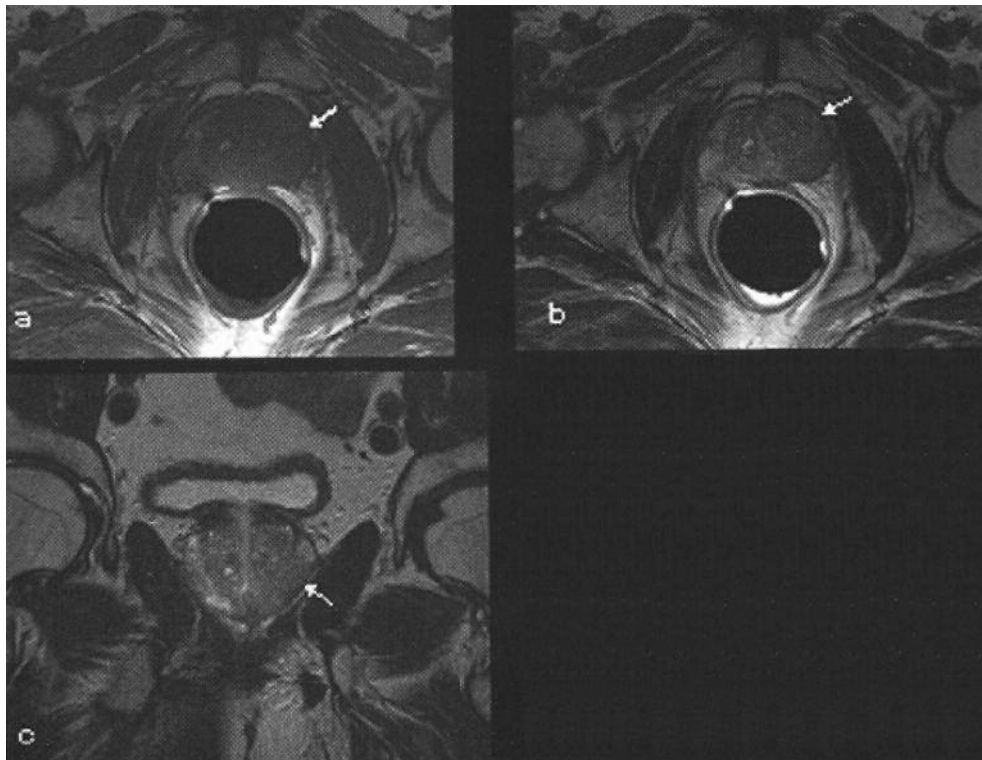


Figure 2. MR images representing lidocaine injection areas.

line drawn between vesiculoprostatic angle and prostate apex. Diffusion of lidocaine in this area was observed on MR image (Figure 2). Patients were observed after the procedure for lidocaine related side effects and possible acute complications. Notes were taken in this regard. In control group, TRUS guided biopsy was performed without anesthesia in conformity with biopsy criteria which are mentioned above. 10th minute following anesthesia, a total of 14 right and left biopsies were taken using 18 gauge needle. In subjective assessment of pain, 11-point VAS was used. Patients were asked to evaluate their pain felt during DRE, probes entry in rectum and biopsy procedure on this scale (Figure 3).

Answers were noted 0 to be no pain to 10 to be severe pain.

Every patient was observed for 4 hours after the biopsy for early complications such as haematuria and rectal bleeding. Rectal bleeding was determined using anal pads.

#### Statistical Analysis

Statistical analysis was made by SPSS®, Chicago, IL, USA. To determine parameters for each patient group, mean and standard deviation values were calculated. VAS scores were analyzed using Kruska-Wallis ANOVA median test and independent *t* test.  $p < 0.05$  was considered statistically significant.

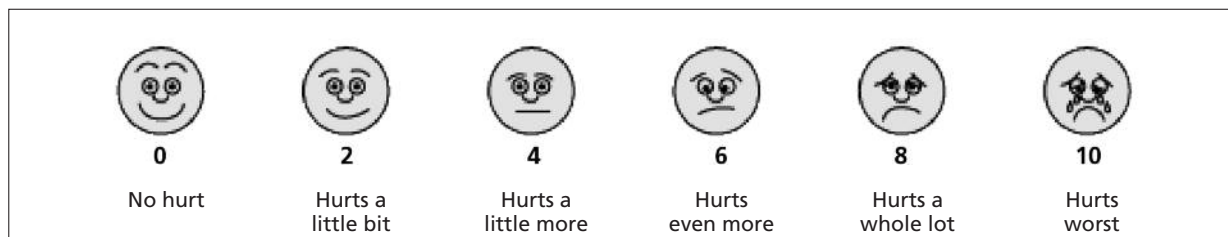


Figure 3. MR images representing lidocaine injection areas.

**Table II.** Comparison of mean pain scores (VAS scores).

	Group I (with anesthesia)	Group II (without anesthesia)	<i>p</i> value
DRE/VAS average	2.47 ± 1.55	2.34 ± 1.53	0.758
TRUS probe placement/VAS average	4.68 ± 1.56	4.25 ± 1.5	0.156
During the biopsy/VAS average	2.3 ± 0.87	5.8 ± 1.6	< 0.001

### Results

Group 1 and Group 2 were compared in age, PSA and prostate volume (Table I). The mean values of two groups as age, PSA and prostate volumes measured by TRUS were statistically similar. VAS cores of both groups were defined during prostatic injection (PRI) and probe implementing and the results were given in Table II. In Table II, mean pain values were given according to VAS in both groups. Mean pain values of the first group who had anesthesia were measured as 2.42 ± 1.55 during PRI, 4.68 ± 1.56 during probe implementing, 2.34 ± 1.08 during biopsy operation. The second group who had no anesthesia had mean pain values: 2.34 ± 1.53 during PRI, 4.25 ± 1.51 during probe implementing, and 5.8 ± 1.60 during biopsy. Between two groups, no statistically significant difference (*p* > 0.05) was observed in terms of pain scores during PRI and probe implementing in the statistical analysis done with One way Anova test. On the other hand, in the first group who had local anesthetics the pain felt was statistically lower (*p* < 0.005).

In both groups, no statistically significant difference was observed in terms of post-operation complications such as macroscopic hematuria, infections, hemotechezia (*p* > 0.05). In the first group who had lidocaine as local anesthetic agent, no systematic side effects of lidocaine as sleepiness, headaches and allergic reactions were encountered.

### Discussion

Sextant prostate biopsy with TRUS in diagnosis of prostate cancer started to be used in 1989 and sextant biopsy technique has become a standard method for prostate biopsy<sup>15</sup>. However, the common perception is that it is better to have more than 6 cores of biopsies in prostate cancer diagnosis<sup>8,9</sup>. In the first biopsies of the patients whose prostate cancer were not diagnosed in earlier biopsies, the rate of diagnosis showed 7-22% and in the second repetitive biopsies it showed 2-

10%<sup>16</sup>. Therefore, because of the increasing core amount and the necessity of biopsy repetition the operation should be rendered with effective anesthetics. In the studies, one-third of the patients stated they were not to accept any further biopsy operations if needed, because of the pain they felt. In repeating biopsies, when we consider the high rate of cancer, it is a serious problem that the patients refuse a second biopsy because of the pain they felt in the first biopsy<sup>17</sup>. It was shown that the pain felt in prostate biopsy operation especially occurred during implementing probe to the rectum, moving the probe in the rectum and extracting biopsy from the prostate with injector<sup>18</sup>. In the literature, a number of anesthetics methods are defined for prostate biopsy<sup>19</sup>. It has been reported in several studies that the pain felt during biopsy and the uneasiness feeling during probe entering the rectum can be reduced by rectal lidocaine and prilocaine gel<sup>20-21</sup>. However, this method was not able to radically decrease the pain felt during biopsy<sup>20</sup>. Since the rectum mucosa has a rich absorbing capacity, the intrarectal gel spreads systematically and it is not preferred as the gel does not have a local effect<sup>22</sup>. In recent studies, blocking periprostatic nerve for pain control during prostate biopsy is recommended as a golden standard method<sup>11-13</sup>. Blocking periprostatic nerve was reported for the first time by Nash et al<sup>23</sup>. In this placebo-controlled study, 90 patients had prostatic injection biopsy and it is ascertained that periprostatic nerve blockage is significantly more effective than placebo<sup>21</sup>.

During prostate biopsy, the main sources of pain are prostate capsule and stroma. These areas are richer than the nerve fibers continuing with baselaterally vascular pedicle<sup>24</sup>. Neurovascular bunch rooting from pelvic plexus goes through posterolateral prostate and front side of the rectum. Some of these nerve fibers pierces through prostate capsule and finishes there while other fibers unite on the surface of the bladder neck<sup>25</sup>. In order to have a successful periprostatic anesthesia, the sensorial fibers of the neurovascular bunch rooting from pelvic plexus should be blocked.

Although there have been many studies on the infiltration of local anesthetics on periprostatic area, there is not a definite consensus over the appropriate localization. The anesthesia injection in which apex is applied, might cause a dense pain each time the injector enters the skin during or after the anesthesia, depending on the dentate line being very close or exactly on the same line because of the entering angle of the probe. For basis, the generally recommended area is just below the vesiculoprostic angle. As this area is very close to prostatic capsule, the risk of piercing the capsule during anesthesia is very high; that is, causing the patient to feel so much pain.

In our study, while the middle area (in TRUS-Mount Everest Sign) between apex and vesiculoprostic angle 4 cm above the rectum linea dentate line- is named as pars levatores prostatae in cadaver pieces; clinically, it corresponds to the Trigger Point in the rectum. This area was defined as 'appropriate anatomic area' for anesthesia and 1% of lidocaine periprostatic applied to the area in an amount lower than it is reported in the literature (1 ml in total). In order to measure the pain felt by patients, VAS method, which is known as the best method in pain measurement because of its comfortable use and high sensitivity was performed<sup>26</sup>. None of the patients felt pain or discomfort during anesthesia application. Since detailed imaging of prostate and volume calculations are handled after anesthesia, the patients did not feel any discomfort or pain when probe was moving in rectum. Akpınar et al<sup>27</sup> defined the area to apply anesthesia with Doppler ultrasonography and applied 2 ml (both) 2% lidocaine to the ultimate point of both seminal vesicles on pelvic plexus laterals.

Lidocaine is a local anesthetic, the effectiveness of which is shown in percutaneous, oral mucosal or ureteral application<sup>28,29</sup>. In a placebo-controlled study, Pareek et al<sup>11</sup> applied 2.5 cc 1% lidocaine (total 5 cc) on each sides of the prostate and later found that periprostatic local anesthesia had a significant benefit. In another study, Soloway et al<sup>30</sup> applied approximately 5 cc 1% lidocaine and reported that a statistically significant remediation took place in terms of patient comfort.

There is no consensus over the lidocaine dose to apply on periprostatic area. Inal et al<sup>31</sup> reported in their study aiming at determining the appropriate dose for periprostatic blockage that 6 ml 1% lidocaine dose is sufficient for pain control. In our study, however, reasonable outcome is obtained despite using 1 ml 1% lidocaine. It

is also reported that lesser dose of local anesthetics result in lesser complications in terms of biopsy and lidocaine. In accompany with TRUSG, some undesired side effects such as infections may be observed within a spectrum from pain, vasovagal reactions, rectal bleeding, hematuria, hemospermia, simple urinary infections to sepsis<sup>32,33</sup>. We did not observe a difference between the complications in our study and the complication data in the literature. In addition, no difference was observed between the group with anesthesia and the one without in terms of complications; and the results were compatible with the literature<sup>31</sup>.

## Conclusions

Similar results compared with the data acquired from other studies were obtained by anesthetic substance injection on two sides (left and right) with the correct angle and lesser dose (1 cc in total) to the area between vesiculoprostic angle and apex, by going through rectum mucosa approximately 4 cm above the anal canal in the periprostatic nerve blockage. In this work, we have demonstrated that the injection of lesser dose of local anesthetic substance (1 cc 1%) to the prostate seminal vesicle and prostate basis area (Mount Everest Sign) is adequate for the local anesthesia practiced during prostate biopsy.

## Conflict of Interest

The Authors declare that they have no conflict of interests.

## References

- 1) BORING CC, SQUIRES TS, TONG T, MONTGOMERY S. Cancer statistics, 1994. *CA Cancer J Clin* 1994; 44: 7-26.
- 2) BERGER AP, FRAUSCHER F, HALPERN EJ, SPRANGER R, STEINER H, BARTSCH G, HORN-INGER W. Periprostatic administration of local anesthesia during transrectal ultrasound-guided biopsy of the prostate: a randomized, double-blind, placebo-controlled study. *Urology* 2003; 61: 585-588.
- 3) LANDIS SH, MURRAY T, BOLDEN S, WINGO PA. Cancer statistics, 1999. *CA Cancer J Clin* 1999; 49: 8-31.
- 4) MATLAGA BR, ESKEW LA, MCCULLOUGH DL. Prostate biopsy: indications and technique. *J Urol* 2003; 169: 12-19.
- 5) COONER WH, MOSLEY BR, RUTHERFORD CL JR, BEARD JH, POND HS, TERRY WJ, IGEL TC, KIDD DD. Prostate cancer detection in a clinical urological

- practice by ultrasonography, digital rectal examination and prostate specific antigen. *J Urol* 1990; 143: 1146-1152.
- 6) CLEMENTS R, AIDEYAN OU, GRIFFITHS GJ, PEELING WB. Side effects and patient acceptability of transrectal biopsy of the prostate. *Clin Radiol* 1993; 47: 125-126.
  - 7) COLLINS GN, LLOYD SN, HEHIR M, MCKELVIE GB. Multiple transrectal ultra-sound-guided prostatic biopsies--true morbidity and patient acceptance. *Br J Urol* 1993; 71: 460-463.
  - 8) OCHIAI A, BABAIAJAN RJ. Update on prostate biopsy technique. *Curr Opin Urol* 2004;14:157-162.
  - 9) DJAVAN B. prostate biopsies and the Vienna nomograms. *Eur Urol suppl* 2006; 5: 500.
  - 10) NAUGHTON CK, MILLER DC, YAN Y. Impact of transrectal ultrasound guided prostate biopsy on quality of life: a prospective randomized trial comparing 6 versus 12 cores. *J Urol* 2001; 165: 100-103.
  - 11) PAREEK G, ARMENAKAS NA, FRACCHIA JA. Periprostatic nerve blockade for transrectal ultra-sound guided biopsy of the prostate: a randomized, double-blind, placebo controlled study. *J Urol* 2001; 166: 894-897.
  - 12) BERGER AP, FRAUSCHER F, HALPERN EJ, SPRANGER R, STEINER H, BARTSCH G, HORN-INGER W. Periprostatic administration of local anesthesia during transrectal ultrasound-guided biopsy of the prostate: a randomized, double-blind, placebo-controlled study. *Urology* 2003; 61: 585-588.
  - 13) WALKER AE, SCHELVAN C, ROCKALL AG, RICKARDS D, KELLETT MJ. Does pericapsular lidocaine reduce pain during transrectal ultrasonography-guided biopsy of the prostate? *BJU Int* 2002; 90: 883-886.
  - 14) OZDEN E, YAMAN O, GÖGÜS C, ÖZGENÇİL E, SOYGÜR T. The optimum doses of and injection locations for periprostatic nerve blockade for transrectal ultra-sound guided biopsy of the prostate: a prospective, randomized, placebo controlled study. *J Urol* 2003; 170: 2319-2322.
  - 15) HODGE KK, McNEAL JE, TERRIS MK, STAMEY TA. Random systematic versus directed ultra-sound guided transrectal core biopsies of the prostate. *J Urol* 1989; 142: 71-74.
  - 16) LEITE KR, CAMARA-LOPES LH, CURY J, DALL'OGGIO MF, SAÑUDO A, SROUGI M. Prostate cancer detection at rebiopsy after an initial benign diagnosis: results using sextant extended prostate biopsy. *Clinics* 2008; 63: 339-342.
  - 17) SLONIM SM, CUTTINO JT JR, JOHNSON CJ, YANKASKAS BC, SMITH JJ 3RD, SILVER-MAN ML, L-BERTINO JA. Diagnosis of prostatic carcinoma: value of random transrectal sonographically guided biopsies. *AJR Am J Roentgenol* 1993; 161: 1003-1006.
  - 18) LEIBOVICI D, ZISMAN A, SIEGEL YI, SELLA A, KLEINMANN J, LINDNER A. Local anesthesia for prostate biopsy by periprostatic lidocaine injection: a double-blind placebo controlled study. *J Urol* 2002;167:563-565.
  - 19) AUS G, DAMBER JE, HUGOSSON J. Prostate biopsy and anaesthesia: an over-view. *Scand J Urol Nephrol* 2005; 39: 124-129.
  - 20) RABER M, SCATTONI V, ROSCIGNO M, DEHÒ F, BRIGANTI A, SALONIA A, GALLINA A, DI GIROLAMO V, MONTORSI F, RIGATTI P. Topical prilocaine-lidocaine cream combined with peripheral nerve block improves pain control in prostatic biopsy: results from a prospective randomized trial. *Eur Urol* 2008; 53: 967-973.
  - 21) ISSA MM, BUX S, CHUN T, PETROS JA, LABADIA AJ, ANASTASIA K, MILLER LE, MARSHALL FF. A randomized prospective trial of intrarectal lidocaine for pain control during transrectal prostate biopsy: the Emory University experience. *J Urol* 2000; 164: 397-399.
  - 22) ALAVI AS, SOLOWAY MS, VAIDYA A, LYNNE CM, GHEILER EL. Local anesthesia for ultrasound guided prostate biopsy: a prospective randomized trial comparing 2 methods. *J Urol* 2001; 166: 1343-1345.
  - 23) NASH PA, BRUCE JE, INDUDHARA R, SHINOHARA K. Transrectal ultrasound guided prostatic nerve blockade eases systematic needle biopsy of the prostate. *J Urol* 1996; 155: 607-609.
  - 24) MUTAGUCHI K, SHINOHARA K, MATSUBARA A, YASUMOTO H, MITA K, USUI T. Local anesthesia during 10 core biopsy of the prostate: comparison of 2 methods. *J Urol* 2005; 173: 742-745.
  - 25) BENOIT G, MERLAUD L, MEDURI G, MOUKARZEL M, QUILLARD J, LEDROUX M, GI-ULIANO F, JARDIN A. Anatomy of the prostatic nerves. *Surg Radiol Anat* 1994; 16: 23-29.
  - 26) SCOTT J, HUSKISSON EC. Graphic representation of pain. *Pain* 1976; 2: 175-184.
  - 27) AKPINAR H, TÜFEK I, ATUG F, ESEN EH, KURAL AR. Doppler ultrasonography-guided pelvic plexus block before systematic needle biopsy of the prostate: A prospective randomized study. *Urology* 2009; 74: 267-271.
  - 28) TADDIO A, STEVENS B, CRAIG K, RASTOGI P, BEN-DAVID S, SHENNAN A, MULLIGAN P, KOREN G. Efficacy and safety of lidocaine-prilocaine cream for pain during circumcision. *N Engl J Med* 1997; 336: 1197-1201.
  - 29) BREKKAN E, EHRNEBO M, MALMSTRÖM PU, NORLÉN BJ, WIRBRANT A. A controlled study of low and high volume anesthetic jelly as a lubricant and pain reliever during cystoscopy. *J Urol* 1991; 146: 24-27.
  - 30) SOLOWAY MS, OBEK C, GILLENWATER JY. Periprostatic local anesthesia before ultrasound guided prostate biopsy. *J Urol* 2000; 163: 172-175.
  - 31) İNAL G, YAZICI S, KOAN M, UGURLU Ö, TA M, ADSAN Ö. Transrektal Ultra-sonografi esli-ginde prostat biyopsisi öncesi 2 ml ve 6 ml periprostatik % 1 lidokain enjeksiyonunun karsılařtirmasi. *Türk Üroloji Dergisi* 2004; 30: 173-177.
  - 32) RAAJMAKERS R, KIRKELS WJ, ROOBOL MJ, WILDHAGEN MF, SCHRDER FH. Complication rates and risk factors of 5802 transrectal ultrasound-guided sextant biopsies of the prostate within a population-based screening program. *Urology* 2002; 60: 826-830.
  - 33) OBEK C, ONAL B, ÖZKAN B, ONDER AU, YALÇIN V, SOLOK V. Is periprostatic local anesthesia for transrectal ultrasound guided prostate biopsy associated with increased infectious or hemorrhagic complications? A prospective randomized trial. *J Urol* 2002; 168: 558-561.