

Dexmedetomidine combined with endotracheal intubation laryngeal mask in anesthesia of patients with a cervical spine injury

Z. LIU¹, X. WANG¹, L.-P. WANG¹, Y. BAI², Y.-X. LI², X.-N. GAO², Y.-B. SUN¹

¹Department of Anesthesiology, Chengde Central Hospital, Chengde, China

²Chengde Medical College, Chengde, China

Zhong Liu and Xin Wang contributed equally to this work

Abstract. – **OBJECTIVE:** Tracheal intubation under general anesthesia is more likely to aggravate the injury of the cervical spine and spinal cord. We aim to explore the effect of dexmedetomidine combined with intubating laryngeal mask airway (ILMA) on anesthesia and stress response in patients with a cervical spine injury.

PATIENTS AND METHODS: One hundred twenty patients were retrospectively allocated into the control group (midazolam + ILMA) and intervention group (dexmedetomidine + ILMA). Their hemodynamics at T1 (before anesthesia induction), T2 (1 minute after anesthesia induction), T3 (immediately after intubation), and T4 (1 min after successful intubation) were also compared.

RESULTS: The heart rate (HR) and mean arterial pressure (MAP) of patients in the observation group were lower than those in the control group from T3 to T4 (both $p = 0.000$). Ramsay's score in the observation group was higher than the control group from T3 to T4 (both $p = 0.000$). No difference was observed in PaO_2 , PaCO_2 , and pH between the 2 groups. The level of serum cortisol (COR), plasma epinephrine (E), and norepinephrine (NE) in the observation group were lower than in the control group ($p < 0.05$) after induction.

CONCLUSIONS: Dexmedetomidine combined with ILMA could improve the first intubation success rate and tolerance in patients with cervical spine injury by maintaining stable hemodynamics and reducing the stress response of patients.

Key Words:

Cervical spine injury, Dexmedetomidine, Intubating laryngeal mask airway (ILMA), Anesthesia, Stress response.

Introduction

Intubation in patients with cervical spine injury is hard to perform because of limited cervical

spine movement, spinal cord compression, and different degrees of mouth opening limitation¹. Tracheal intubation under general anesthesia is more likely to aggravate the injury of the cervical spine and spinal cord². For patients difficult to intubate, the clinicians often keep the patients in breathing and awaken for ventilation. Intubating laryngeal mask airway (ILMA) is a modified laryngeal mask airway designed for tracheal intubation³. ILMA can be performed under the condition of shallow anesthesia. The patient does not need to tilt the back head and neck, which has a certain protective effect on patients with cervical injury². Dexmedetomidine is an α_2 receptor agonist with good sedative and anti-anxiety effects, it has no evident inhibitory effect on patients' spontaneous breathing and could be used in patients with shallow anesthesia^{4,5}. More importantly, moderate sedative and analgesic effects could reduce the body's stress response of patients. In this study, dexmedetomidine or midazolam combined with ILMA were compared in patients with a cervical spine injury, to analyze the anesthetic effect and impact on stress response in patients with a cervical spine injury.

Patients and Methods

Patients

Clinical data of patients with cervical spine injury were retrospectively screened. All patients received surgical treatment for spine cord injury in our hospital from December 2014 to December 2017. All protocols followed the Chinese anesthesiology guidelines and expert consensus. The included criteria were: 1) patients with traumatic and mechanical cervical spine injury and was di-

agnosed by CT or MRI imaging; 2) patients with American Society of Anesthesiologists (ASA) grade I or II; 3) patients with intubation difficulty and had Cormack-Lehane grade III or IV; 4) patients or family members signed informed consent for data collection and data using. The case was excluded if: 1) patients with severe heart, liver, and kidney dysfunction; 2) patients with coagulation dysfunction or circulatory system diseases; 3) spinal cord injury caused by the malignant tumor or other diseases; 4) patients with unconsciousness; 5) pregnant or lactating women. The study was approved by the Ethics Committee of Chengde Central Hospital (approve number: cdzz20200428) and informed consent was obtained from each patient for data use.

Anesthesia Methods

Pharyngeal and laryngeal surface anesthesia were performed with tetracaine. Three milliliters of 2% lidocaine were injected through a cricothyroid membrane puncture. Patients inhaled pure oxygen with a mask for 3 min. Dexmedetomidine (Jiangsu Hengrui Pharmaceutical Co., Ltd.) was infused by an intravenous micropump in patients of the observation group, with a dose of 1 $\mu\text{g}/\text{kg}$ and completed within 10 minutes. After infusion of dexmedetomidine, fentanyl (Yichang Renfu Pharmaceutical Co., Ltd.) was slowly injected with the dose of 2 $\mu\text{g}/\text{kg}$. Midazolam with a dose of 0.03 mg/kg was pumped in the same way within 10 minutes to patients of the control group. Fentanyl was slowly injected with a dose of 2 $\mu\text{g}/\text{kg}$ after the pump injection.

All patients were intubated with ILMA. No.7 or no.7.5 tracheal tube was selected for ILMA. The patient was asked to keep their head in the middle position. A senior anesthesiologist inserted the ILMA from the oral cavity. The anesthesia machine was supplied, and patients' breathing was manually adjusted, the airway resistance and PetCO_2 waveform were observed to judge whether the position of ILMA was ideal. The tracheal tube was inserted after confirming that the position was satisfactory. According to the actual resistance, the intubation was adjusted or re-inserted. Atropine was used in case of bradycardia before intubation, and esmolol was used in case of tachycardia after intubation. After successful intubation, 1.5 mg/kg of propofol, 2 $\mu\text{g}/\text{kg}$ of fentanyl, and 0.6 mg/kg of rocuronium were infused intravenously, and mechanical ventilation was started. More than 3 times of intubation is considered as fail in intubation, and endotracheal intu-

bation is performed. Anesthesia was maintained by intermittent injection of fentanyl (0.1-0.3 $\mu\text{g}/\text{kg}$), propofol (4-5 mg/kg/h), sevoflurane (1%), and rocuronium.

Measured Parameters

Clinical parameters including catheter keeping time, the intubation success rates at first-attempt, second attempt, and the third-attempt intubation were compared in two groups. Compared hemodynamics including changes in mean arterial pressure (MAP), heart rate (HR), and stroke volume variation (SVV) at T1 (before anesthesia induction), T2 (1 minute after anesthesia induction), T3 (immediately after intubation), and T4 (1 min after successful intubation). The changes of PaO_2 , PaCO_2 , PH, and Ramsay sedation score⁶ were also compared in the two groups.

The levels of serum cortisol (COR), plasma epinephrine (E), and norepinephrine (NE) were also detected at T1, T2, T3, and T4 after 2 ml of elbow venous blood was drawn from patients. Recorded complications during intubation were also compared between the 2 groups.

Statistical Analysis

All data were analyzed by SPSS 20.0 statistical software (Armonk, NY, USA). The counting data were expressed by n (%), and the differences between groups were compared with the chi-square(χ^2) test. The measurement data met the homogeneity of variance and distributed normally were expressed as mean \pm standard deviation (mean \pm SD), and the differences between groups were compared with the *t*-test. Repeated measurement analysis of variance was used to analyze the changes of hemodynamic indexes and stress hormones at different time points, and LSD-*t*-test was used for pairwise comparison between groups. $p < 0.05$ was considered as statistically significant.

Results

A total of 120 patients were screened finally with 60 patients in each group. The distributions of gender, injured position, and ASIA (American Spinal Injury Association) classification were balanced between the 2 groups and have no significant difference (Table I). All patients completed the operation successfully. There were 2 cases of intubation failure in the observation group and 5 cases in the control group. At the time of in-

Table I. The demographic data of included patients (n=60).

Index	Control group	Intervention group	p
Age (year)	52.31±6.67	50.25±6.27	0.52
Gender (M/F)	35/25	32/28	0.58
Weight (kg)	62.87±6.72	65.12±7.33	0.57
Height(cm)	170.21±18.93	171.13±20.26	0.45
BMI (kg/cm ²)	23.59±3.52	22.87±3.37	0.63
Injury Type			
Cervical spondylopathy	31	33	0.855
Spine injury	29	27	
ASIA classification			
A	7	5	0.854
B	12	15	
C	25	23	
D	16	17	

tubation, the total success rate of intubation has no significant differences between the 2 groups. However, the first-time intubation success rate was high in the observation group (81.7% vs. 65%, $p=0.039$). Furthermore, the atropine use was higher in the observation group. The rate of esmolol use and the incidence of agitation in the observation group were significantly lower than those in the control group ($p=0.000$ and $p=0.049$, respectively, Table II), and the rate of tolerance to intubation was significantly higher in the observation group ($p=0.008$, Table II).

Hemodynamics and Blood Gas

The HR, MAP, SpO₂, and SVV of patients tended to be stable in both groups with the extension of the operation time and were within the normal range during the operation. There was no significant difference between the 2 groups at T1. The HR and MAP of patients in the observation group were lower than those in the control group at T3, T4 (both $p=0.000$, Figure 1A and B). The SpO₂ and the Ramsay scores in the observation group were higher than those in the control group at T3, T4 (both $p=0.000$, Figure 1C and E). While

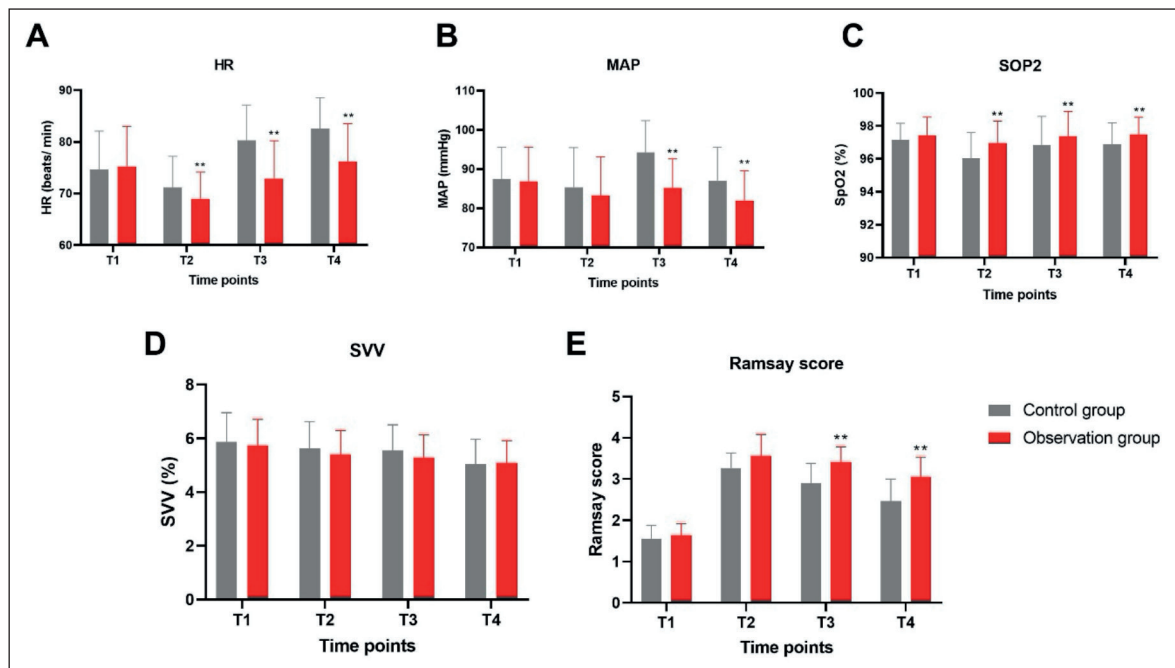


Figure 1. The hemodynamics and blood gas parameters in patients who received dexmedetomidine and midazolam. **A:** HR; **B:** MAP; **C:** SpO₂; **D:** SVV; **E:** Ramsay scores. T1: before anesthesia induction, T2:1 minute after anesthesia induction, T3: immediately after intubation, T4:1 min after successful intubation. **, $p=0.000$ compared with the control group (midazolam) at the same time point.

Table II. The demographic data of included patients (n=60).

Index	Control group	Intervention group	p
Catheters keeping time (s)	61.31 ± 13.87	56.94 ± 11.35	0.061
Total success rate (%)	91.67	96.67	0.243
The success rate of intubation (%)			
The 1 st	39 (65%)	47 (81.7%)	0.039
The 2 nd	12 (20%)	8 (13.3%)	0.327
The 3 rd	4 (6.7%)	1 (1.7%)	0.171
Atropine use (n, %)	5 (8.33%)	11 (18.33%)	0.0107
Esmolol use (n, %)	28 (46.67%)	8 (13.33%)	0.000
Restlessness (n, %)	18 (30.00%)	9 (15.00%)	0.049
Tolerance to intubation (n, %)	44 (73.33)	55 (91.67%)	0.008

the SVV has no difference in the 2 groups (Figure 1D). Blood gas comparisons showed there were no significant differences in PaO₂, PaCO₂, and pH value between two groups at T1 and T2, T3, T4 (Figure 2A-C).

Postoperative Stress Hormone Levels and Complications

The serum stress substances (COR, E, and NE) in 2 groups have no difference at T0, while the level of COR, E, and NE in the observation group was lower than that in the control group at T3 and T4 with statistical significance (Figure 3A-C, p<0.01). The incidence of choking, airway spasm, and sore throat were low in both groups has no difference between the two groups.

Discussions

Cervical spondylotic myelopathy (CSM) is one of the diseases that arise from spinal cord compression. CSM accounts for 10%-15% of all cervical spondylotic diseases^{7,8}. The degeneration of the intervertebral connected structure in the

cervical vertebra, such as disc herniation, bone spurs at the posterior edge of the vertebral body, and hyperplasia of the unchained vertebra, could cause CSM, which further leads to spinal cord compression or spinal cord ischemia⁹⁻¹¹. Injury of the cervical vertebra could cause spinal cord damage. For severe cervical spinal cord injury, the operation is an important clinical treatment to restore the function of the spinal cord¹². Anesthetic intubation should be considered to stabilize the patient’s cervical spine sequence without causing secondary injury in these patients¹³. In patients with general anesthesia, the intubation is performed under laryngoscope guidance and requires the lower jaw to be lifted. In order to reduce the secondary injury to the cervical spine and spinal cord in patients with spine cord injury, endotracheal intubation is often performed in the awake state of the patients in order to protect the spinal cord it is especially important to choose a quick and safe method for intubation.

Dexmedetomidine and midazolam are two kinds commonly used during sedative drugs. Dexmedetomidine is a highly selective alpha2 adrenergic receptor agonist soluble in water¹⁴.

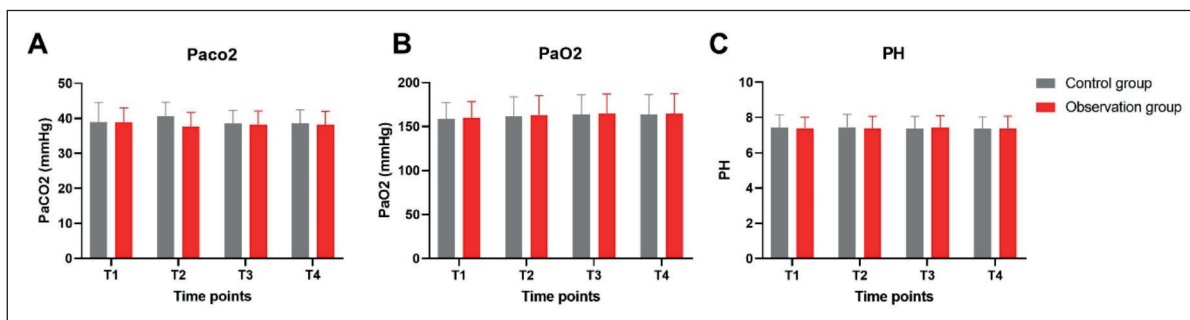


Figure 2. blood gas change in patients who received midazolam (control group) and dexmedetomidine (observation group). A: PaO₂; B: PaCO₂; C: PH. T1: before anesthesia induction, T2:1 minute after anesthesia induction, T3: immediately after intubation, T4:1 min after successful intubation.

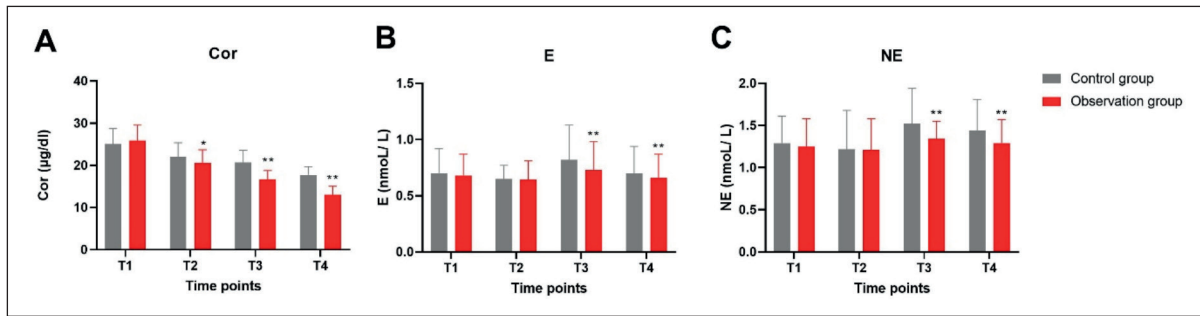


Figure 3. stress hormone levels change in patients who received midazolam (control group) and dexmedetomidine (observation group). **A:** serum cortisol (COR); **B:** plasma epinephrine (E); **C:** norepinephrine (NE). T1: before anesthesia induction, T2:1 minute after anesthesia induction, T3: immediately after intubation, T4:1 min after successful intubation. *, $p < 0.05$; **, $p < 0.01$ compared with the control group at the same time point.

Dexmedetomidine stimulates the α_2 receptor of the locus ceruleus nucleus to produce sedative and hypnotic effects, which makes patients in a natural sleep state and has a neuroprotective effect that does not produce evident respiratory depression^{15,16}. Thus, made it an ideal sedative for patients with dyspnea and intubation in an awake state. Midazolam has typical benzodiazepine pharmacological activity, but it may lead to hypoxemia¹⁷. In this study, the two sedatives were compared as a laryngeal mask before intubation anesthesia induction drug. There was no difference between the time and total success rate of intubation. Therefore, overall, the efficacy of the two drugs for anesthesia induction is similar. This is consistent with previous reports^{18,19}. On the other hand, our study showed the first intubation success rate is higher in patients who received dexmedetomidine, as a result, the incidence of agitation was significantly lower.

Most used intravenous anesthetics slow down the heart rate by inhibiting the sympathetic nerve during anesthesia. Our research also demonstrated that HR, MAP, SVV were relatively lower in patients who received dexmedetomidine, this result is consistent with the study of Riker et al¹⁸, compared with midazolam, dexmedetomidine treated patients were more likely to develop bradycardia. Dexmedetomidine can inhibit the function of the cardiac sinoatrial node and atrioventricular node^{20,21}, which might be one of the causes of bradycardia. In our study, the loading doses of dexmedetomidine were relatively low (1 µg/kg), and the MAP is acceptable in patients who received dexmedetomidine, therefore, no bradycardia was reported in the study. While in clinical application, it is still necessary to take comprehensive medication based on the patient's previous his-

tory of bradycardia, dexmedetomidine loading dose, patient's MAP, and other factors²² and make a disposal plan for possible bradycardia events.

The Ramsay scores in the observation group were higher than those who received midazolam, which indicated a better sedative effect of dexmedetomidine. During intubation, patients should be paid close attention to SpO₂ and given oxygen in time. When SpO₂ decreased significantly to ensure anesthesia safety. There was no difference in PaO₂, PaCO₂, and pH between the two groups, and they were maintained within the normal range, which indicated that there was no difference in the effects of dexmedetomidine and midazolam on the respiration of anesthesia patients.

Surgical anesthesia affects the stress response in patients, which is a nonspecific defense response characterized by sympathetic nerve excitation and hypothalamic-anterior pituitary-adrenal cortex function enhancement when the body is strongly stimulated^{23,24}. Spinal surgery is a strong stressor, and the degree of response is positively correlated with the stimulus intensity of the stressor, the stronger the stimulus, the stronger the response²⁵. The adrenal gland is the main organ of stress reaction, E and NE levels can directly reflect the important index of the body's stress response, and Cor is also involved in the body's stress response^{26,27}. When the body was stimulated, E, NE, and COR are released, which increases blood pressure, HR^{28,29}. Consistent with previous report³⁰, our study showed that the serum levels of Cor, E, and NE in the dexmedetomidine-treated patients were lower than those who received midazolam. With the extension of the operation time, dexmedetomidine could reduce the stress response of the body to surgery, and the effect was better than that of midazolam, which may be related to the better

sedative effect and stable hemodynamic factors of dexmedetomidine. Related studies³¹⁻³³ have shown that after intravenous administration of dexmedetomidine, all components of heart rate variability are reduced, especially low-frequency components, and plasma NE level is significantly reduced. Although ILMA can reduce the difficulty of intubation and the stimulation to the throat of patients to a certain extent, the patient will inevitably be anxious and nervous when intubation is performed in the awake state. At the same time, the inevitable stimulation will lead to the increase of the patient's blood pressure and heart rate, resulting in stress response. Therefore, it is necessary to maintain the patient's blood pressure with the help of sedatives and reduce their stress response, finally improving the success rate of intubation.

Conclusions

In conclusion, compared with midazolam, dexmedetomidine has a better sedative effect during intubation and could improve the first intubation success rate and tolerance in patients undergoing spinal surgery. It is helpful to maintain stable hemodynamics without causing severe stress response and can achieve rapid intubation at the same time, which is worthy of clinical promotion. However, close attention should be paid in response to possible adverse reactions.

Conflicts of Interest

The authors declare no conflicts of interest.

References

- 1) Ahmad I, El-Boghdady K, Bhagrath R, Hodzovic I, McNarry A F, Mir F, O'Sullivan E P, Patel A, Stacey M, Vaughan D. Difficult Airway Society guidelines for awake tracheal intubation (ATI) in adults. *Anaesthesia* 2020; 75: 509-528.
- 2) Joffe AM, Aziz MF, Posner KL, Duggan LV, Mincer SL, Domino KB. Management of Difficult Tracheal Intubation: A Closed Claims Analysis. *Anesthesiology* 2019; 131: 818-829.
- 3) Cattano D, Van Zundert T, Wojtczak J. Laryngeal mask airway and the enigma of anatomical sizing. *J Clin Monit Comput* 2019; 33: 757-758.
- 4) Lee S. Dexmedetomidine: present and future directions. *Korean J Anesthesiol* 2019; 72: 323-330.
- 5) Carr ZJ, Cios TJ, Potter KF, Swick JT. Does Dexmedetomidine Ameliorate Postoperative Cognitive Dysfunction? A Brief Review of the Recent Literature. *Curr Neurol Neurosci Rep* 2018; 18: 64.
- 6) Montague SJ, Morton AR. Ramsay Hunt syndrome. *CMAJ* 2017; 189: E320.
- 7) Zhao CM, Chen Q, Zhang Y, Huang AB, Ding WY, Zhang W. Anterior cervical discectomy and fusion versus hybrid surgery in multilevel cervical spondylotic myelopathy: A meta-analysis. *Medicine (Baltimore)* 2018; 97: e11973.
- 8) Demetriades A K. Early cervical spondylotic myelopathy and longitudinal brain activation changes. *Acta Neurochir (Wien)* 2018; 160: 933-934.
- 9) Alli S, Anderson I, Khan S. Cervical spondylotic myelopathy. *Br J Hosp Med (Lond)* 2017; 78: C34-C37.
- 10) Bakhsheshian J, Mehta VA, Liu JC. Current Diagnosis and Management of Cervical Spondylotic Myelopathy. *Global Spine J* 2017; 7: 572-586.
- 11) Pepke W, Almansour H, Richter M, Akbar M. [Spondylotic cervical myelopathy: Indication of surgical treatment]. *Orthopade* 2018; 47: 474-482.
- 12) Yoshida G, Alzakri A, Pointillart V, Boissiere L, Obeid I, Matsuyama Y, Vital JM, Gille O. Global Spinal Alignment in Patients With Cervical Spondylotic Myelopathy. *Spine (Phila Pa 1976)* 2018; 43: E154-E162.
- 13) Moustafa MA, Arida EA, Zanaty OM, El-Tamboly SF. Endotracheal intubation: ultrasound-guided versus fiberoptic in patients with cervical spine immobilization. *J Anesth* 2017; 31: 846-851.
- 14) Barends CR, Absalom A, van Minnen B, Vissink A, Visser A. Dexmedetomidine versus Midazolam in Procedural Sedation. A Systematic Review of Efficacy and Safety. *PLoS One* 2017; 12: e0169525.
- 15) Greenberg RG, Wu H, Laughon M, Capparelli E, Rowe S, Zimmerman KO, Smith PB, Cohen-Wolkowicz M. Population Pharmacokinetics of Dexmedetomidine in Infants. *J Clin Pharmacol* 2017; 57: 1174-1182.
- 16) Subramaniam B, Shankar P, Shaefi S, Mueller A, O'Gara B, Banner-Goodspeed V, Gallagher J, Gasangwa D, Patxot M, Packiasabapathy S, Mathur P, Eikermann M, Talmor D, Marcantonio E R. Effect of Intravenous Acetaminophen vs Placebo Combined With Propofol or Dexmedetomidine on Postoperative Delirium Among Older Patients Following Cardiac Surgery: The DEXACET Randomized Clinical Trial. *JAMA* 2019; 321: 686-696.
- 17) Munoz HR, Dagnino J. Combined use of spinal anesthesia and midazolam sedation increases the risk of hypoxemia. *Anesth Analg* 1996; 83: 195-196.
- 18) Riker RR, Shehabi Y, Bokesch PM, Ceraso D, Wisemandle W, Koura F, Whitten P, Margolis BD, Byrne DW, Ely EW, Rocha MG, Group SS. Dexmedetomidine vs midazolam for sedation of critically ill patients: a randomized trial. *JAMA* 2009; 301: 489-499.
- 19) Jakob S M, Ruokonen E, Grounds RM, Sarapohja T, Garratt C, Pocock SJ, Bratty JR, Takala J. Dex-

- medetomidine for Long-Term Sedation I. Dexmedetomidine vs midazolam or propofol for sedation during prolonged mechanical ventilation: two randomized controlled trials. *JAMA* 2012; 307: 1151-1160.
- 20) Ergul Y, Unsal S, Ozyilmaz I, Ozturk E, Carus H, Guzeltas A. Electrocardiographic and electrophysiologic effects of dexmedetomidine on children. *Pacing Clin Electrophysiol* 2015; 38: 682-687.
- 21) Sairaku A, Nakano Y, Suenari K, Tokuyama T, Kawazoe H, Matsumura H, Tomomori S, Amioka M, Kihara Y. Dexmedetomidine Depresses Sinoatrial and Atrioventricular Nodal Function Without Any Change in Atrial Fibrillation Inducibility. *J Cardiovasc Pharmacol* 2016; 68: 473-478.
- 22) Djalali Motlagh S, Rokhtabnak F, Ghodraty MR, Maleki Delarestaghi M, Saadat S, Araghi Z. Effect of Different Loading Doses of Dexmedetomidine on Controlled Hypotension and the Incidence of Bradycardia During Rhinoplasty: A Clinical Trial. *Anesth Pain Med* 2021; 11: e118857.
- 23) Wang X, Komatsu S. Proteomic approaches to uncover the flooding and drought stress response mechanisms in soybean. *J Proteomics* 2018; 172: 201-215.
- 24) Oyola MG, Handa RJ. Hypothalamic-pituitary-adrenal and hypothalamic-pituitary-gonadal axes: sex differences in regulation of stress responsiveness. *Stress* 2017; 20: 476-494.
- 25) Glienke K, Piefke M. Stress-related cortisol responsiveness modulates prospective memory. *J Neuroendocrinol* 2017; 29:
- 26) Kanczkowski W, Sue M, Bornstein SR. The adrenal gland microenvironment in health, disease and during regeneration. *Hormones (Athens)* 2017; 16: 251-265.
- 27) Shahin AA, El Desouky SM, Awadallah MY, Megahed DE. Adrenal gland abnormalities detected by magnetic resonance imaging in patients with antiphospholipid syndrome. *Z Rheumatol* 2017; 76: 170-175.
- 28) Chira RI, Chira A, Manzat-Saplacan RM, Nagy G, Valea A, Silaghi AC, Mircea PA, Valean S. Adrenal glands transabdominal ultrasonography - pictorial essay. *Med Ultrason* 2017; 19: 318-323.
- 29) Moya EA, Arias P, Iturriaga R. Nitration of MnSOD in the Carotid Body and Adrenal Gland Induced by Chronic Intermittent Hypoxia. *J Histochem Cytochem* 2018; 66: 753-765.
- 30) Qin Z, Xiang C, Li H, Liu T, Zhan L, Xia Z, Zhang M, Lai J. The impact of dexmedetomidine added to ropivacaine for transversus abdominis plane block on stress response in laparoscopic surgery: a randomized controlled trial. *BMC Anesthesiol* 2019; 19: 181.
- 31) Duan X, Coburn M, Rossaint R, Sanders RD, Waesberghe JV, Kowark A. Efficacy of perioperative dexmedetomidine on postoperative delirium: systematic review and meta-analysis with trial sequential analysis of randomised controlled trials. *Br J Anaesth* 2018; 121: 384-397.
- 32) Shutes BL, Gee SW, Sargel CL, Fink KA, Tobias JD. Dexmedetomidine as Single Continuous Sedative During Noninvasive Ventilation: Typical Usage, Hemodynamic Effects, and Withdrawal. *Pediatr Crit Care Med* 2018; 19: 287-297.
- 33) Sun S, Wang J, Bao N, Chen Y, Wang J. Comparison of dexmedetomidine and fentanyl as local anesthetic adjuvants in spinal anesthesia: a systematic review and meta-analysis of randomized controlled trials. *Drug Des Devel Ther* 2017; 11: 3413-3424.