

# Association of compartment defects in anorectal and pelvic floor dysfunction with female outlet obstruction constipation (OOC) by dynamic MR defecography

M. LI<sup>1</sup>, T. JIANG<sup>1</sup>, P. PENG<sup>1</sup>, X.-Q. YANG<sup>1</sup>, W.-C. WANG<sup>2</sup>

<sup>1</sup>Department of Radiology, Beijing Chaoyang Hospital, Affiliated to Capital Medical University, Beijing, China

<sup>2</sup>Department of Radiology, Beijing Anzhen Hospital, Affiliated to Capital Medical University, Beijing, China

*Min Li, Tao Jiang and Peng Peng contributed equally to this work and shared the first authorship*

**Abstract. – OBJECTIVE:** Chronic constipation affects more than 17% of the global population worldwide, and up to 50% of patients were outlet obstruction constipation (OOC). Women and the elderly are most likely to be affected, due to female-specific risk factors, such as menopause, parity and multiparity. The aim of our study was to investigate the association of compartment defects in anorectal and pelvic floor dysfunction with female outlet obstruction constipation (OOC) by MR defecography.

**PATIENTS AND METHODS:** Fifty-six consecutive women diagnosed with outlet obstruction constipation from October 2009 to July 2011 were included. They were categorized into the following groups: anorectal disorder only group (27 patients) and anorectal disorder plus multi-compartment pelvic disorder group (29 patients). Relevant measurements were taken at rest, during squeezing and straining.

**RESULTS:** Anismus was significantly more common in the anorectal disorder group compared to the multi-compartment pelvic disorder group. Conversely, rectocele, rectal prolapse, and descending perineum were significantly more common in the multi-compartment pelvic disorder group compared to the anorectal disorder group. Of the total 56 OOC patients, 34 (60.7%) exhibited anismus and 38 (67.9%) rectocele. Among the anismus patients, there were 8 patients (23.5%) with combined cystocele, and 6 patients (17.6%) with combined vaginal/cervical prolapse. Among the rectocele patients, there were 23 patients (60.5%) with combined cystocele and 18 patients (47.4%) with combined vaginal/cervical prolapse. With respect to anorectal defects, 13 anismus patients (38.2%) were with signal posterior pelvic defects, 4 rectocele patients (10.5%) presented with signal posterior pelvic defects.

**CONCLUSIONS:** Inadequate defecatory propulsion due to outlet obstruction constipa-

tion is often associated with multi-compartment pelvic floor disorders, whereas not about dyssynergic defecation.

#### Key Words:

Magnetic resonance, Defecography, Obstruction constipation, Pelvic floor, Defecation, Rectocele, Anismus.

## Introduction

Outlet obstruction constipation (OOC), defined as a failure of evacuating contents from the rectum<sup>1</sup>, is usually accompanied by symptoms of dyschezia and a subjective sensation of anal blockage during defecation<sup>2</sup>. The causes for OCC include rectocele, anismus (dyssynergic defecation), rectoanal intussusception, descending perineum syndrome, enterocele and sigmoidocele<sup>3</sup>. It is estimated that more than 17% of the global population will subject chronic constipation, and up to 50% of patients that were referred to tertiary centers for the management of chronic constipation were diagnosed with OOC<sup>4,5</sup>. Women and the elderly are most likely to be affected, due to female-specific risk factors, such as menopause, parity and multiparity, and hysterectomy<sup>5,6</sup>.

Anatomically, each organ system in the pelvic floor urinary, genital, and anorectal-traverses the pelvis and intricately related in function and structural support<sup>7</sup>. Although patients may present with symptoms that involve only one compartment, 95% pelvic floor dysfunction have abnormalities in all of the three pelvic floor compartments<sup>8</sup>. Female outlet obstruction constipa-

tion may be caused by anorectal disorders or (and) pelvic floor dysfunction and thus specific diagnostic methods are needed to systematically evaluate various pelvic floor compartments<sup>8</sup>.

Dynamic MR defecography allows insight into rectal function and structure and can be repeated because of the total lack of ionizing radiation<sup>9</sup>. In addition, defecography permits assessment of the anosphincteric, puborectal, and levator muscles, and analysis of the anorectal angle, the opening of the anal canal, the function of the puborectal muscle, and the descent of the pelvic floor during defecation. Thus, it can be used to accurately evaluate spastic pelvic floor syndrome and descending perineum syndrome. Excellent visualization of the rectal wall provides information about intussusceptions and rectocele. Dynamic MR defecography has replaced evacuation proctography for the diagnosis and treatment of female outlet obstruction constipation<sup>1,10,11</sup>. Especially, dynamic MR images during defecation is of great value since relevant findings may be missed when dynamic pelvic MR imaging were obtained at rest, squeeze and straining only. The aim of our study was to investigate the various anorectal disorders and elucidate the association of the pelvic floor dysfunction with outlet obstruction constipation in female by dynamic magnetic resonance imaging defecography.

## Patients and Methods

### Patients

The study was approved by the Ethics Committee of Chao Yang Hospital, Capital University of Medical Science, and written informed consent was obtained from all subjects. A total of 56 patients diagnosed with functional defecation disorders at the Proctology Department of Chao Yang Hospital, Capital University of Medical Science from October 2009 to July 2011 were included.

The inclusion criteria were: (1) patients with chronic symptoms of straining, incomplete evacuation, hard stools, anorectal obstruction, manual maneuvers, and/or  $\leq 3$  bowel movements per week; (2) underwent comprehensive physical examinations; (3) diagnosed with OOC according to the Rome III criteria<sup>12</sup>; (4) colonoscopy, defecography, or lower gastrointestinal contrast results consistent with an OOC diagnosis; (5) had complete documented medical histories of all hypoestrogenism, prior pelvic surgery, and sponta-

neous vaginal deliveries; and (6) underwent MR defecography examinations. The exclusion criteria were: (1) patients who exhibited signs or symptoms of other colorectal organic diseases such as malignancy; (2) patients who refused MR examination; or (3) patients who did not give consent to diagnostic examinations. Patients were categorized into the following groups: anorectal disorder only group (e.g., rectocele) and anorectal disorder plus multi-compartment pelvic disorder group (e.g., cystocele, vaginal/cervical prolapse).

### MR Defecography

Two to three hours before examination, glycerol enema was performed. Because the patient's cooperation is of major importance to achieve a satisfactory examination, explanation is crucial during the preparatory phase, since defecating in the supine position could be difficult for some patients. Covering the gantry with a plastic sheet helps overcome the patient's embarrassment and allows easier cleaning after the examination. MR was performed by using the 3.0T magnet (Magnetom Trio Tim, Siemens, Germany) or 1.5T magnet (1.5T Signa HDx Twinspeed, USA) with 16-/8-channel phased array body coils. The multi-coil array was wrapped around the inferior portion of the pelvis. A multicoil array, either pelvic or torso, is wrapped around the inferior portion of the pelvis, and the patient is placed in the supine position with knee and hip flexion (similar to the lithotomy position). A custom fabricated, highly conformable sacculus was then inserted into the rectum to simulate stool. The first balloon was inserted into the rectum and thereafter the sonographic gel was injected into the balloon simulation feces. Warm gel might be used as well to reduce patient discomfort. In our institution, patients are asked not to void the bladder in the hour before the examination, and the vagina is filled with 10 mL of sonographic gel to increase the conspicuity of any abnormal finding involving these structures. No oral or intravenous contrast agents were administered in each patient.

### Dynamic MR Defecography Imaging

Static images of the pelvis were first obtained in three dimensions using TSE-T2WI/FSE-T2WI (repetition time (ms)/echo time (ms), 5000/86; field of view (FOV), 200-280 mm; slice thickness, 3 mm; gap, 0.5 mm; number of signals acquired, 3; matrix, 320 × 320). In this sequence,

section orientation was parallel and perpendicular to the plane of the anal canal. Dynamic imaging was performed by using fast imaging with steady-state precession/fast imaging employing steady-state acquisition (FISP/FIESTA) in the mid-sagittal and oblique coronal planes at rest and during strain, squeezing, and defecation. Relative measurements were obtained at rest, squeeze, and strain (repetition time 766 ms; echo time 1.65 ms; FOV, 240-300 mm; slice thickness, 8 mm; gap, 0.5 mm).

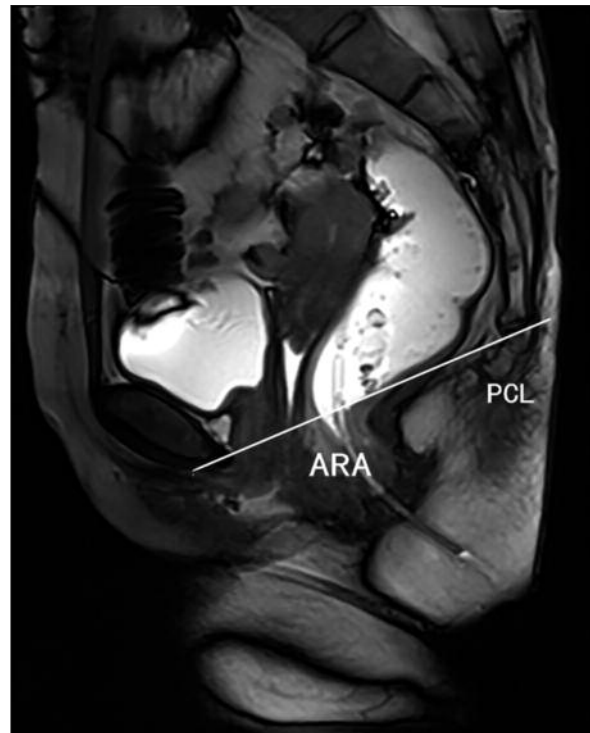
### Image Analysis

All the images were evaluated respectively by two experienced radiologist, who was blinded to the any knowledge of patient information. Decision was obtained by consensus.

**Static imaging.** These sequences were used to evaluate the pelvic floor muscles and endopelvic ligament. Differences with respect to the thickness and position of the levator ani muscles affecting defecation were evaluated<sup>13</sup>. The puborectal muscle was best visualized in the oblique axial plane which showed some asymmetry as a normal variation<sup>14</sup>. The iliococcygeus muscle was best visualized in the oblique coronal plane which usually showed a convex shape towards caudal. The endopelvic ligaments can be variably observed when a pelvic phased-array coil was applied. Endopelvic fascia was not directly visualized when using a pelvic phased-array coil. Attempts were made to visualize secondary signs of fascial defects such as funneling of the bladder neck<sup>15</sup>.

### Dynamic Imaging

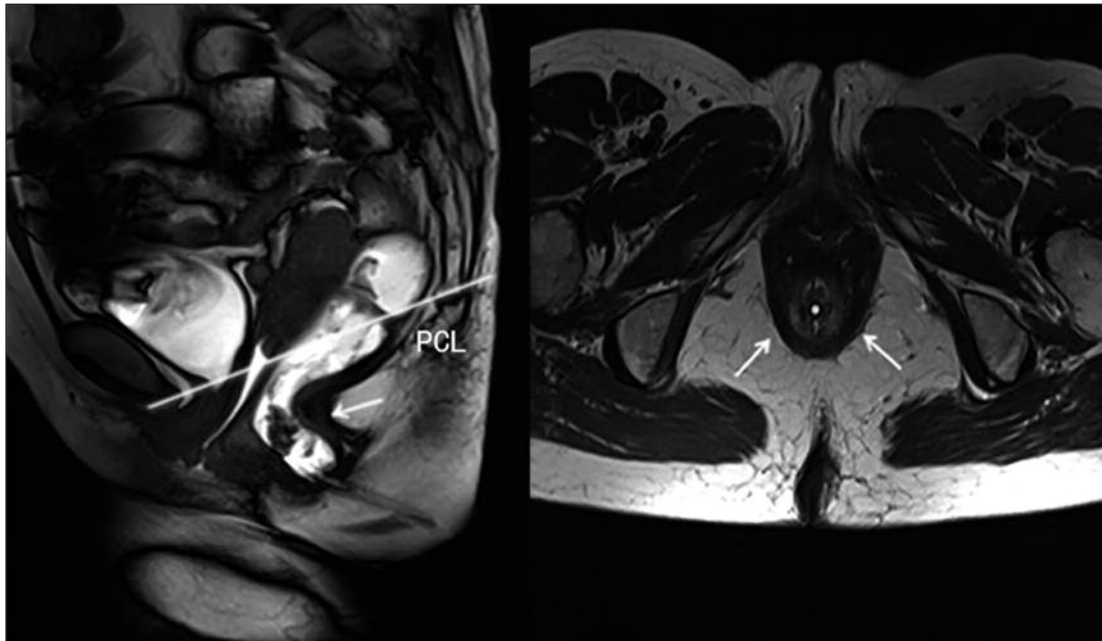
The pubococcygeal line (PCL) extending from the inferior border of the pubic symphysis to the tip of the coccyx posteriorly was used as a reference line<sup>10</sup>. The anorectal junction was defined as the intersection point of the central axis of the anal canal and a line along the posterior rectal wall. The anorectal angle (ARA) was measured between these two lines (Figure 1). The anorectal angle normally measures between  $108^{\circ}$  and  $127^{\circ}$  at rest and changes as the puborectalis muscle contracts or relaxes. Normally, the anorectal angle closes between rest and squeezing and opens between rest and defecation by about  $15^{\circ}$ - $20^{\circ}$ <sup>16</sup>. In addition, the descent of the bladder neck, bladder base, uterus (or vaginal vault), and anorectal junction below the PCL were measured on sagittal MR defecography images obtained at rest as well as during squeezing and straining.



**Figure 1.** Chronic constipation and straining during defecation in a 32-year-old woman. Sagittal True-FISP MR image of the female pelvis shows the normal position of pelvic viscera at rest, pubococcygeal line (PCL) reference, and anorectal angle (ARA).

### Diagnostic Criteria

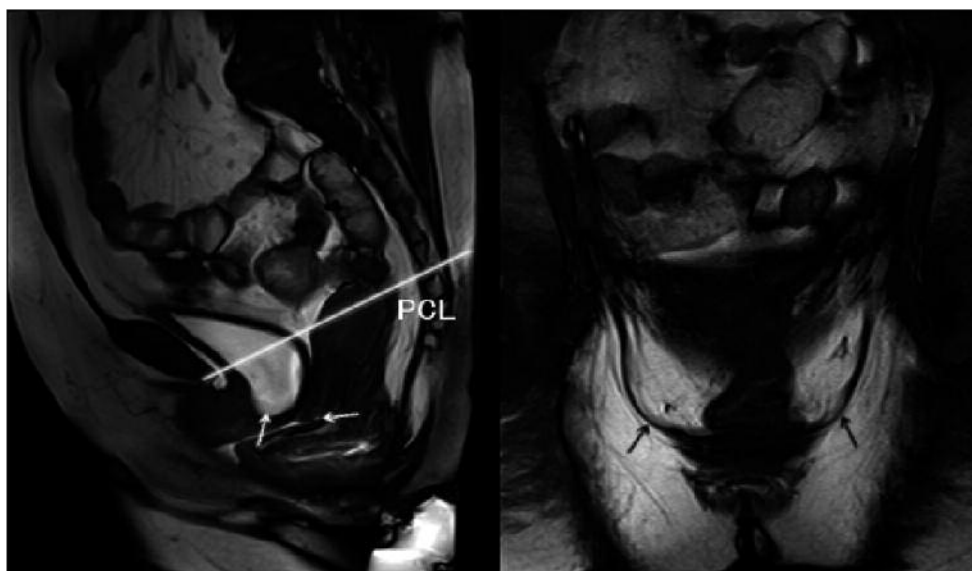
Diagnostic criteria for MR defecography were applied as previously described<sup>16</sup>. Anismus was defined as lack of normal puborectal muscle relaxation during defecation, potentially complicated by lack of normal pelvic floor descent, puborectal muscle hypertrophy (Figure 2). Rectocele was defined as a bulge of the anterior rectal wall of  $> 2$  cm from a line drawn parallel to the center of the anal canal during straining (mild = 2-4 cm, moderate  $> 4$ -6 cm, and severe  $> 6$  cm) (Figure 3). Cystocele was bladder base descent below the border of the pubic symphysis. At MR imaging, a cystocele was diagnosed when the bladder base descends more than 1 cm below the PCL during straining. Vaginal or cervical prolapse were defined as descent of the vaginal vault or cervix below the PCL during straining. The degree of prolapse is graded as mild if the vaginal vault or cervix extends less than 3 cm below the PCL, moderate if it extends between 3 and 6 cm, and severe if it extends 6 cm or more below the PCL. Enterocele was defined as a herniation of the pelvic peritoneal sac into the rectogenital space



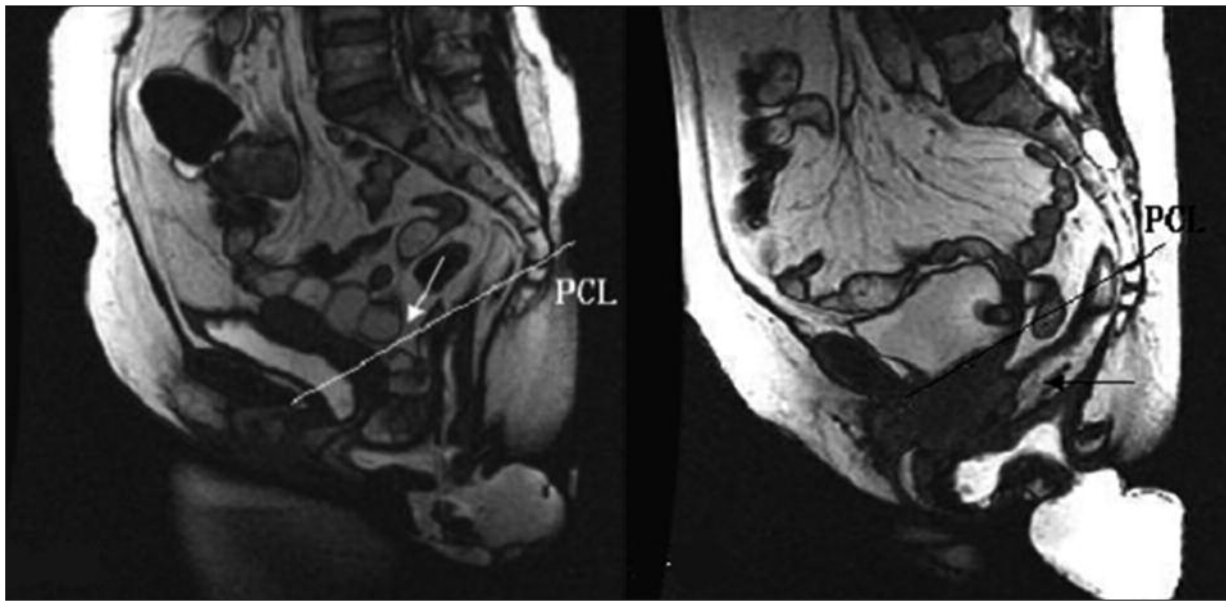
**Figure 2.** Chronic constipation and straining during defecation in a 32-year-old woman. Sagittal True-FISP MR image of the patient during straining shows lack of pelvic floor descent during defecation and a paradoxical contraction of the puborectal muscle with a failure of the anorectal angle to open, resulting in prolonged or incomplete evacuation. **A**, The anorectal angle was 90°, and **B** the axial T2-weighted turbo spin-echo MR image reveals a hypertrophic puborectal region.

below the PCL or rectovaginal septum passing below proximal third of the vagina during straining. It may contain fat, called peritoneocele, small bowel, or sigmoid colon (Figure 4). Ente-

rocele are graded small, moderate, or large if they extend 3 cm, 3-6 cm, or more than 6 cm, respectively, below the PCL. Intussusception is defined as circular invagination of the proximal rec-



**Figure 3.** Incomplete bowel evacuation and posterior pressure in a 51-year-old woman. **A**, Sagittal True-FISP MR image of the patient during straining shows the descent of pelvic floor and middle rectocele (grade 2) combined with abnormal descent of the middle and anterior pelvic floor compartments. **B**, Coronal True-FISP MR image of the patient during straining demonstrates a diffuse and symmetrical bulging of the levators (*white arrows*).



**Figure 4.** Two patients with chronic pelvic floor dysfunction with straining pelvises. Sagittal FIESTA MR images show **(A)** internal small bowel herniation and **(B)** sigmoid colon into the rectovaginal space below the pubococcygeal line (PCL). Both patients exhibit rectocele combined with incomplete evacuation.

tal wall involving both the mucosa and muscular layer during defecation. Low-grade intussusception was defined as rectal mucosa infolding but not entering the anal canal, while high-grade intussusception was a full-thickness prolapse that penetrates the anal canal or impedes evacuation. Descending perineum or descending perineal syndrome is an excessive caudad movement of the pelvic floor during evacuation. The syndrome is often associated with a feeling of incomplete evacuation, which leads to increased straining during evacuation and consequent additional neuropathic injury that may result in incontinence.

#### **Statistical Analysis**

All data were analyzed were performed with the SPSS software, version 11.5 (SPSS Inc., Chicago, IL, USA). Qualitative data were expressed as percentage and compared by Chi-square test or Fisher exact test between groups. Normally distributed continuous data are presented as means  $\pm$  standard deviation (SD) and were compared using t tests. Non-normally distributed continuous data are presented as the median and range, and were compared using the Wilcoxon rank sum tests. Crude odds ratios (OR) with 95% CIs were calculated to quantify the potential risk indicators. Differences were considered statistically significant when  $p < 0.05$ .

## **Results**

### ***Clinical and Demographic Data for Anorectal Disorders Subjects***

Of the 56 OOC patients, 27 (48.2%) patients were assigned into the anorectal disorder only group and 29 (51.8%) into the anorectal disorder plus multi-compartment pelvic disorder group. The detailed clinical and demographic data for the OOC patient were summarized in Table I. There was no significant difference in terms of the mean age, pelvic surgery, and estrogen status between the two groups (all  $p > 0.05$ ). Patients with multi-compartment pelvic organ prolapse were more susceptible to parities than patients without ( $p < 0.05$ ).

### ***Anorectal Disorders***

There was significant difference with respect to the incidence of rectocele, anismus, descending perineum and rectal intussusception between the two groups ( $p < 0.05$ ). In the anorectal disorder group, 25 (92.6%) patients exhibited anismus and 13 (48.1%) patients exhibited rectocele. Whereas in the multi-compartment pelvic disorder group 9 (31.0%) and 25 (86.2%) patients exhibited anismus and rectocele, respectively (Table II). Anismus was significantly more common in the anorectal disorder group compared to the multi-compartment pelvic disorder group ( $p < 0.05$ ). Conversely, rectocele, rectal prolapse,

**Table I.** Demographic data for female patients with outlet obstruction constipation (OOC).

Parameter	Anorectal disorder only group (n = 27)	Anorectal disorder plus multi-compartment pelvic disorder group (n = 29)	p value
Parity (no. pregnancies)	1.4 ± 1.0	2.0 ± 1.0	0.2*
Age (years)	55.2 ± 14.5	56.2 ± 12.8	0.70
Hypoestrogenism (no. patients)	18 (67%)	18 (62%)	0.70*
Prior pelvic surgery (no. patients)	9 (33%)	9 (31%)	0.85*
Spontaneous vaginal delivery (no. patients)	19 (70%)	29 (100%)	0.07
Duration of constipation (months)	32.54	24.74	0.07 <sup>A</sup>

\*Two-sample t-test; \* $\chi^2$  test; <sup>A</sup>Wilcoxon rank sum test.

**Table II.** Posterior compartment abnormalities in outlet obstruction constipation (OOC) patients.

Parameter	Anorectal disorder (n = 27)	Multi-compartment pelvic disorder group (n = 29)	p value*
Anismus	25 (92.6%)	9 (31.0%)	< 0.001*
Rectocele	13 (48.1%)	25 (86.2%)	0.002
Rectal intussusception	5 (18.5%)	18 (62.1%)	0.001
Descending perineum	2 (7.4%)	17 (58.6%)	< 0.001*
Enterocele	2 (7.4%)	4 (13.7%)	0.266

\* $\chi^2$  test.

and descending perineum were significantly more common in the multi-compartment pelvic disorder group compared to the anorectal disorder group ( $p < 0.05$ ). We failed to test the difference with respect to the incidence of enterocele due to insufficient samples (Table II).

**Anorectal and Pelvic Floor Dysfunction**

Of the total 56 OOC patients, 34 (60.7%) exhibited anismus and 38 (67.9%) rectocele.

Among the anismus patients, 23.5% (8 patients) were with combined cystocele, and 17.6% (6 patients) with combined vaginal/cervical prolapse (Table III). Among the rectocele patients, 60.5% (23 patients) were with combined cystocele and 47.4% (18 patients) with combined vaginal/cervical prolapse (Table IV). With respect to anorectal defects, 13 anismus patients (38.2%) were with signal defects, 4 rectocele patients (10.5%) presented with signal defects (Table III, IV).

**Table III.** The coexistence of multiple compartment defects in 34 anismus patients.

Anorectal disorders	Associated conditions n (%)			
	Cystocele	Vaginal/cervical prolapse	Enterocele	PD
SPFS (n = 13)	1 (7.7%)	0	0	0
SPFS combined with Rectal intussusception (n = 2)	1 (50.0%)	1 (50.0%)	0	0
SPFS combined with RC (n = 15)	4 (26.7%)	5 (33.3%)	0	4 (26.7%)
SPFS combined with RC, and Rectal intussusception (n = 4)	2 (50.0%)	0	1 (25.0%)	1 (25.0%)
Total (n = 34)	27 (48.2%)	21 (37.5%)	7 (12.5%)	19 (33.9%)

OOC: outlet obstruction constipation; PD: perineum descending; SPFS: spastic pelvic floor syndrome.

**Table IV.** The coexistence of multiple compartment defects in 38 rectocele patients.

Anorectal disorders	Associated conditions n (%)			
	Cystocele	Vaginal/cervical prolapse	Enterocele	PD
RC (n = 4)	4 (100%)	2 (50%)	1 (25.0%)	4 (100%)
RC combined SPFS (n = 15)	4 (26.7)	5 (33.3)	0	4 (26.7)
RC combined with rectal intussusception (n = 15)	13 (86.7%)	11 (73.3%)	4 (26.7%)	9 (60.0%)
RC combined SPFS, rectal intussusception (n = 4)	2 (50.0)	0	1 (25.0)	1 (25.0)
Total (n=38)	27 (48.2%)	21(37.5%)	7 (12.5%)	19 (33.9%)

RC: rectocele; PD: perineum descending; SPFS: spastic pelvic floor syndrome.

### Discussion

As multi-compartment disorders were significantly associated with parities, women who have had children may be at greater risk for anorectal and pelvic floor dysfunction. Thus, attention should be paid to the diagnosis and treatment of the global pelvic floor, particularly in multiparous women with OOC. Consistent with the current findings, a prospective study over 20 years conducted by the Oxford Family Planning Association showed that parity was associated with pelvic organ prolapse<sup>17</sup>. Some other studies<sup>18,19</sup> also demonstrated an association between pelvic organ prolapse and obstetric factors. This findings suggests that vaginal delivery plays a crucial role in the damage of the pelvic fascia or vaginal wall, and directly or indirectly injury the pelvic floor muscles and nerves<sup>20</sup>. Therefore, we concluded that in multiparous women with OCC MR defecography is suggested.

Of the 56 female OCC patients, 34 (60.7%) exhibited anismus and 38 (67.9%) rectocele. Women with anismus were also likely to develop cystocele (23.5%) and vaginal or cervical prolapse (17.6%). Women with rectocele were at even higher risk in terms of combined cystocele (60.5%) and vaginal or cervical prolapse (47.4%) than anismus patients. Anismus is not usually complicated by anterior or middle pelvic organ prolapse in OOC. This hypothesis is supported by several previous studies which reported that inappropriate contraction of the pelvic floor muscles (anismus) during defecation caused by increased anal pressure during attempted defecation and puborectal muscle hypertrophy, was often visible as a prominent compression on the posterior rectal wall during

voiding<sup>20,21</sup>. The current axial T2WI high-resolution images and dynamic sagittal images provide further evidence of this mechanism. Dynamic MR defecography is an effective method that provides both morphologic and functional information on the pelvic floor. Therefore, similar to western populations<sup>22</sup>, dynamic MR defecography can be also be used for Chinese populations once appropriate standards are established. Further study with a larger number of samples is still needed for this purpose.

Pelvic floor weakness is usually generalized, so the various pelvic floor compartments should be evaluated simultaneously. Clinical examination either underestimates or results in misdiagnosis of the site of prolapse. Underestimation of pelvic organ prolapse may lead to incomplete or incorrect surgery, which may be one of the reasons for the high rate of recurrences after prolapse surgery<sup>23</sup>. If prolapse is shown, it is tempting to attribute symptoms to the prolapse, but in fact the prolapse may merely be secondary to an underlying functional disorder. For example, constipated patients with excessive straining may develop cystocele, enterocele, rectocele, rectal prolapse, and pelvic floor descent<sup>24</sup>. Surgical correction of these diseases will not treat the underlying disorder<sup>25</sup>. In the current study, rectocele occurred in most of female OOC patients with anorectal and pelvic floor dysfunction. It has been proposed that increased rectocele is due to chronic excessive straining due to constipation, pathology, or pregnancy and delivery, thus weakening pelvic floor muscles and damaging the pudendal nerve<sup>26</sup>. This can lead to pelvic prolapse or other pelvic floor disorders, resulting in organ competition for space in the vagina<sup>26</sup>. The current findings are consistent with a previous report by Bump et al<sup>27</sup> which suggested that rectocele as a

solitary finding is rare. The frequency of associated pelvic abnormalities in patients with anorectal disorders is high. In a study of patients with symptoms suggestive of a defecatory disorder<sup>8</sup>, dynamic cystocolpoproctography showed that 71 % had cystoceles, 65 % had a hypermobile bladder neck, and 35 % had vaginal vault prolapse of > 50%. In another report<sup>28</sup>, 50 % of patients with urinary stress incontinence and 80 % of patients with uterovaginal prolapse had symptoms of obstructed defecation. Therefore, global functional pelvic floor evaluation is necessary in defecatory disorders. Conventionally, this can be obtained using evacuation proctography modified by opacification of the bladder in addition to opacification of the small bowel, termed by dynamic cystoproctography<sup>28-30</sup>. However, dynamic cystoproctography does not show the excellent anatomical details of the soft tissues such as muscles and pelvic viscera due to the complexity anatomy of pelvic floor. The traditional method of defecography is performed under fluoroscopic control. Magnetic resonance defecography is developing as an alternative to the traditional method<sup>31</sup>.

We would like to underline that. Firstly, the relationship between prolapse and mean age or estrogen status was not established statistically due to the due to the sample size of patients in our study. Secondly, most of the patients in our series were postmenopausal, further study with larger cohorts of younger patients is still needed. This is especially necessary for indicating the range of OOC symptoms for dynamic MR defecography application in Chinese patients.

## Conclusions

The findings of our study demonstrate that the dynamic MR defecography can be well applied in Chinese women with OCC. Our findings provide a better understanding of the relationship between pelvic floor dysfunction and chronic constipation-related OOC, and contribute to the diagnostic and treatment strategies for women with high risk factors such as multiparity and postmenopause.

## Conflict of Interest

The Authors declare that there are no conflicts of interest.

## References

- 1) FELT-BERSMA RJ, CUESTA MA. Rectal prolapse, rectal intussusception, rectocele, and solitary rectal ulcer syndrome. *Gastroenterol Clin North Am* 2001; 30: 199-222.
- 2) ROIG J, BUCH E, ALOS R, SOLANA A, FERNÁNDEZ C, VILLOSLADA C, GARCIA-ARMENGOL J, HINOJOSA J. Anorectal function in patients with complete rectal prolapse. Differences between continent and incontinent individuals. *Rev Esp Enferm Dig* 1998; 90: 794-805.
- 3) BRODEN B, SNELLMAN B. Procidentia of the rectum studied with cineradiography. *Dis Colon Rectum* 1968; 11: 330-347.
- 4) ANDROMANAKOS N, SKANDALAKIS P, TROUPIS T, FILIPPOU D. Constipation of anorectal outlet obstruction: pathophysiology, evaluation and management. *J Gastroenterol Hepatol* 2006; 21: 638-646.
- 5) CHOUNG R, LOCKE III G, SCHLECK C, ZINSMEISTER A, TALLEY N. Cumulative incidence of chronic constipation: a population-based study 1988-2003. *Aliment Pharmacol Ther* 2007; 26: 1521-1528.
- 6) WHITEHEAD W, WALD A, DIAMANT N, ENCK P, PEMBERTON J, RAO S. Functional disorders of the anus and rectum. *Gut* 1999; 45: II55-II59.
- 7) WALL L. Incontinence, prolapse and disorders of the pelvic floor. Berek JS, Adashi EY, Hillard PA Novak's gynecology. Baltimore-Philadelphia-London: Williams & Wilkins, A Waverly Company, 1996; pp. 619-677.
- 8) MAGLINTE D, KELVIN F, FITZGERALD K, HALE DS, BENSON JT. Association of compartment defects in pelvic floor dysfunction. *AJR Am J Roentgenol* 1999; 172: 439-444.
- 9) SCHREYER AG, PAETZEL C, FURST A, DENDL LM, HUTZEL E, MULLER-WILLE R, WIGGERMANN P, SCHLEDER S, STROSZCZYNSKI C, HOFFSTETTER P. Dynamic magnetic resonance defecography in 10 asymptomatic volunteers. *World J Gastroenterol* 2012; 18: 6836-6842.
- 10) RENTSCH M, PAETZEL C, LENHART M, FEUERBACH S, JAUCH K, FÜRST A. Dynamic magnetic resonance imaging defecography. *Dis Colon Rectum* 2001; 44: 999-1007.
- 11) JELOVSEK JE, MAHER C, BARBER MD. Pelvic organ prolapse. *Lancet* 2007; 369: 1027-1038.
- 12) DROSSMAN DA. The functional gastrointestinal disorders and the Rome III process. *Gastroenterology* 2006; 130: 1377-1390.
- 13) REINER CS, WEISHAUP T. Dynamic pelvic floor imaging: MRI techniques and imaging parameters. *Abdom Imaging* 2013; 38: 903-911.
- 14) FIELDING JR, DUMANLI H, SCHREYER AG, OKUDA S, GERING DT, ZOU KH, KIKINIS R, JOLESZ FA. MR-based three-dimensional modeling of the normal pelvic floor in women: quantification of muscle mass. *AJR Am J Roentgenol* 2000; 174: 657-660.



- 15) EL SAYED RF, EL MASHED S, FARAG A, MORSY MM, ABDEL AZIM MS. Pelvic floor dysfunction: assessment with combined analysis of static and dynamic MR imaging findings. *Radiology* 2008; 248: 518-530.
- 16) COLAIACOMO MC, MASSELLI G, POLETTINI E, LANCIOTTI S, CASCIANI E, BERTINI L, GUALDI G. Dynamic MR imaging of the pelvic floor: a pictorial review. *Radiographics* 2009; 29: e35.
- 17) MANT J, PAINTER R, VESSEY M. Epidemiology of genital prolapse: observations from the Oxford Family Planning Association Study. *BJOG* 1997; 104: 579-585.
- 18) SWIFT S, WOODMAN P, O'BOYLE A, KAHN M, VALLEY M, BLAND D, WANG W, SCHAFFER J. Pelvic Organ Support Study (POSST): the distribution, clinical definition, and epidemiologic condition of pelvic organ support defects. *Am J Obstet Gynecol* 2005; 192: 795-806.
- 19) GROUP PMIS. Risk factors for genital prolapse in non-hysterectomized women around menopause—results from a large cross-sectional study in menopausal clinics in Italy. *Eur J Obstet Gynecol* 2000; 93: 135-140.
- 20) HALLIGAN S, BARTRAM CI, PARK HJ, KAMM MA. Proctographic features of anismus. *Radiology* 1995; 197: 679-682.
- 21) ARYA LA, NOVI JM, SHAUNIK A, MORGAN MA, BRADLEY CS. Pelvic organ prolapse, constipation, and dietary fiber intake in women: a case-control study. *Am J Obstet Gynecol* 2005; 192: 1687-1691.
- 22) SONG W, WANG Z, ZHENG Y, YI B, YANG X, JIANG T. Application of pelvic floor dynamic MRI combining defecography with homemade high conformable sacculus in the management of obstructed defecation syndrome. *Zhonghua Wai Ke Za Zhi* 2009; 47: 1843-1845.
- 23) BROEKHUIS SR, FÜTTERER JJ, BARENTSZ JO, VIERHOUT ME, KLUIVERS KB. A systematic review of clinical studies on dynamic magnetic resonance imaging of pelvic organ prolapse: the use of reference lines and anatomical landmarks. *Int Urogynecol J* 2009; 20: 721-729.
- 24) SPENCE JONES C, KAMM MA, HENRY MM, HUDSON C. Bowel dysfunction: a pathogenic factor in uterovaginal prolapse and urinary stress incontinence. *BJOG* 1994; 101: 147-152.
- 25) HALLIGAN S. Imaging of anorectal function. *Br J Radiol* 1996; 69: 985-988.
- 26) SIPROUDHIS L, ROBERT A, VILOTTE J, BRETAGNE J-F, HERESBACH D, RAOUL J-L, GOSSELIN M. How accurate is clinical examination in diagnosing and quantifying pelvic disorders? A prospective study in a group of 50 patients complaining of defecatory difficulties. *Dis Colon Rectum* 1993; 36: 430-438.
- 27) BUMP RC, MATTIASSON A, BØ K, BRUBAKER LP, DELANCEY JO, KLARSKOV P, SHULL BL, SMITH AR. The standardization of terminology of female pelvic organ prolapse and pelvic floor dysfunction. *Am J Obstet Gynecol* 1996; 175: 10-17.
- 28) HALLIGAN S, SPENCE-JONES C, KAMM M, BARTRAM C. Dynamic cystoproctography and physiological testing in women with urinary stress incontinence and urogenital prolapse. *Clin Radiol* 1996; 51: 785-790.
- 29) HOCK D, LOMBARD R, JEHAES C, MARKIEWICZ S, PENDER L, FONTAINE F, CUSUMANO G, NELISSEN G. Colpocystodefecography. *Dis Colon Rectum* 1993; 36: 1015-1021.
- 30) KELVIN FM, MAGLINTE D, BENSON JT, BRUBAKER LP, SMITH C. Dynamic cystoproctography: a technique for assessing disorders of the pelvic floor in women. *AJR Am J Roentgenol* 1994; 163: 368-370.
- 31) SOMERS S, BARTRAM CI. Defecography. *Abdom Imaging* 2013: 769-784.