

The efficacy of hyaluronidase on flap survival: an animal model

M. SUNGUR¹, C. YILDIRIM², C. CINGI³

¹Department of Orthopedics and Traumatology, Acibadem University, Atakent Hospital, Istanbul, Turkey

²Department of Pharmacology, Medical Faculty, Eskisehir Osmangazi University, Eskisehir, Turkey

³Department of Otorhinolaryngology, Medical Faculty, Eskisehir Osmangazi University, Eskisehir, Turkey

Abstract. – OBJECTIVE: It has been hypothesized that hyaluronidase may allow fluid to enter and exit the basal area of the flap more readily and thus allow waste metabolites from the distal portion of the flap to drain towards areas where the blood supply may be healthier. We aimed to test this hypothesis by seeing whether hyaluronidase enhances the survival of a flap created in an animal model.

MATERIALS AND METHODS: The experiment utilized 14 male Wistar rats to test the effect of administering hyaluronidase on flap survival. The study utilized the same “flap survival method” technique reported in numerous previous studies.

RESULTS: The area of necrosis in the animals of the intervention group was lower than in the control animals, and this result reached statistical significance.

CONCLUSIONS: Hyaluronidase may preserve tissue flap vitality, starting at the bottom end of the dosage range. Future research should establish the minimal concentration needed to obtain benefits. The optimal mode of administration, whether by injection or topical application, is also a topic for future studies.

Key Words:

Hyaluronidase, Flap vitality, Flap survival.

Introduction

Restoration of defective skin areas in all body regions presents surgical challenges in orthopedics and other surgical disciplines^{1,2}. Defective areas that are no more than medium in size may often be reconstructed adequately by using local flaps, which have the advantage of being matched to the surrounding skin in terms of color and texture and ensuring the skin remains healthy. Fur-

thermore, the period leading to recovery will be brief. However, despite these benefits, employing a flap technique may only be possible when the flap base is narrow, and the flap length is considerable. In such a flap, necrosis may well occur. Several researchers have investigated methods by which the risk of necrosis may be reduced, and thus the survival of the reconstruction ensured. Experiments have already been carried out using pentoxifylline and curcumin to lengthen flap survival^{3,4}. Orthopedic procedures also call for flaps, especially following extensive resections when a surgical site needs to be reconstructed. The survival of a flap may be a matter of life and death for the patient, while in some areas, the aesthetic element of the procedure tends to predominate⁵⁻⁷.

Flaps are even more critical in pediatric surgeries to reduce the hospital stay period of the child and avoid secondary surgeries due to unsuccessful results.

Hyaluronidase has a molecular mass of 60 kDa. It catalyzes hyaluronic acid's conversion, resulting in a molecule of lower polarity. Thus, it causes the extracellular matrix to be less viscous, allowing other molecules to enter and diffuse freely into the matrix. This effect may be used clinically to increase the ability of the matrix to soak up excess fluid, to allow edema to be dissipated, and to permit injected substances to be more easily infiltrated. It has been hypothesized that hyaluronidase may allow fluid to enter and exit the basal area of the flap more readily and thus allow waste metabolites from the distal portion of the flap to drain towards areas where the blood supply may be healthier^{8,9}. We aimed to test this hypothesis by seeing whether hyaluronidase enhances the survival of a flap created in an animal model.

Materials and Methods

Ethics approval for this study was obtained from the “Animal Experiments Local Ethics Committee” of Eskisehir Osmangazi University. The experiment utilized 14 male Wistar rats. The rats were housed in standardized conditions for at least 24 hours before the experimental procedure to ensure they were in an identical environment. The study utilized the same “flap survival method” technique reported in numerous previous studies to test the effect of administering hyaluronidase on flap survival.

McFarlane^{10,11} has described the method used. The rat was administered a general anesthetic, following which a flap measuring 3 cm by 10 cm was harvested from the skin of the back. The same flap was then sutured back into the site from which it had been taken^{10,11} (Figures 1, 2). All 14 rats underwent an identical operation. The rats were then randomized to an intervention or control group. The animals in the control group were designated

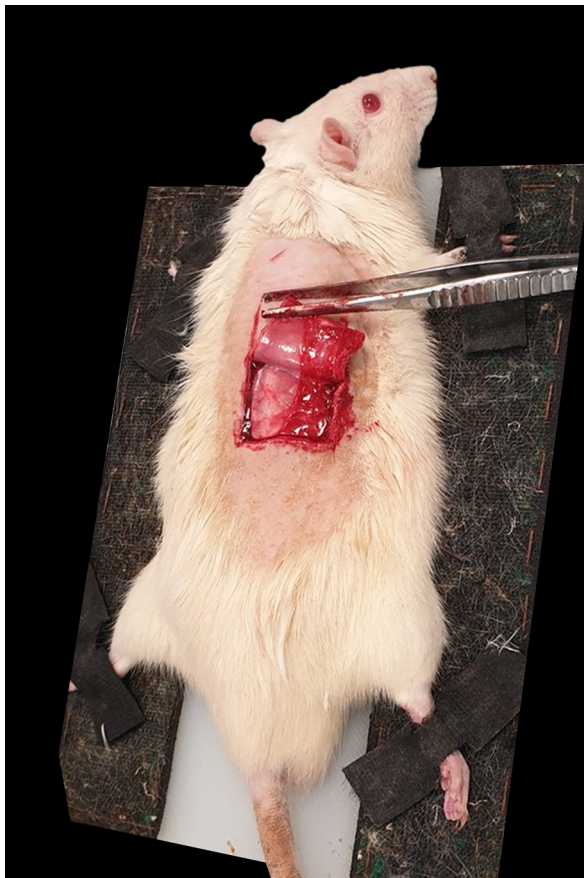

Figure 1. The flap measuring 3 cm by 10 cm was harvested from the skin of the back.

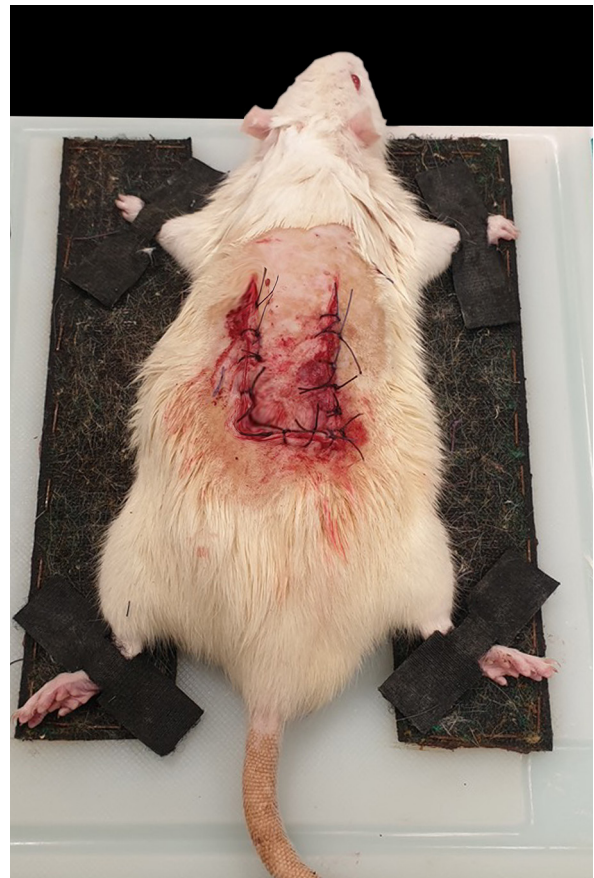

Figure 2. The flap was sutured back into the site from which it had been taken.

as 1.1, 1.2 up, to 1.7. The control group treatment consisted of applying petroleum jelly only to the margins of the flap, performed two times daily. In the intervention group, the animals numbered 2.1, 2.2, to 2.7. These rats underwent twice daily application of vaseline, containing, in addition, hyaluronidase (Hyaluronidase PB3000, PBSerum Medical, Madrid, Spain) at a concentration of 1,500 units per gram, to the margins of the flap.

In order to compare the viability of flaps, the surgical sites of the animals were photographed by the same photographer using the same camera.

The necrosis area of the flap (i.e., the flap viability ratio) was calculated by transferring the images obtained to the Photoshop software application. The regions showing necrosis were demarcated within the digital images, and their area in mm² could then be obtained (Figure 3).

Statistical Analysis

The data obtained in the study were analyzed using SPSS for Windows 21.0 software (IBM

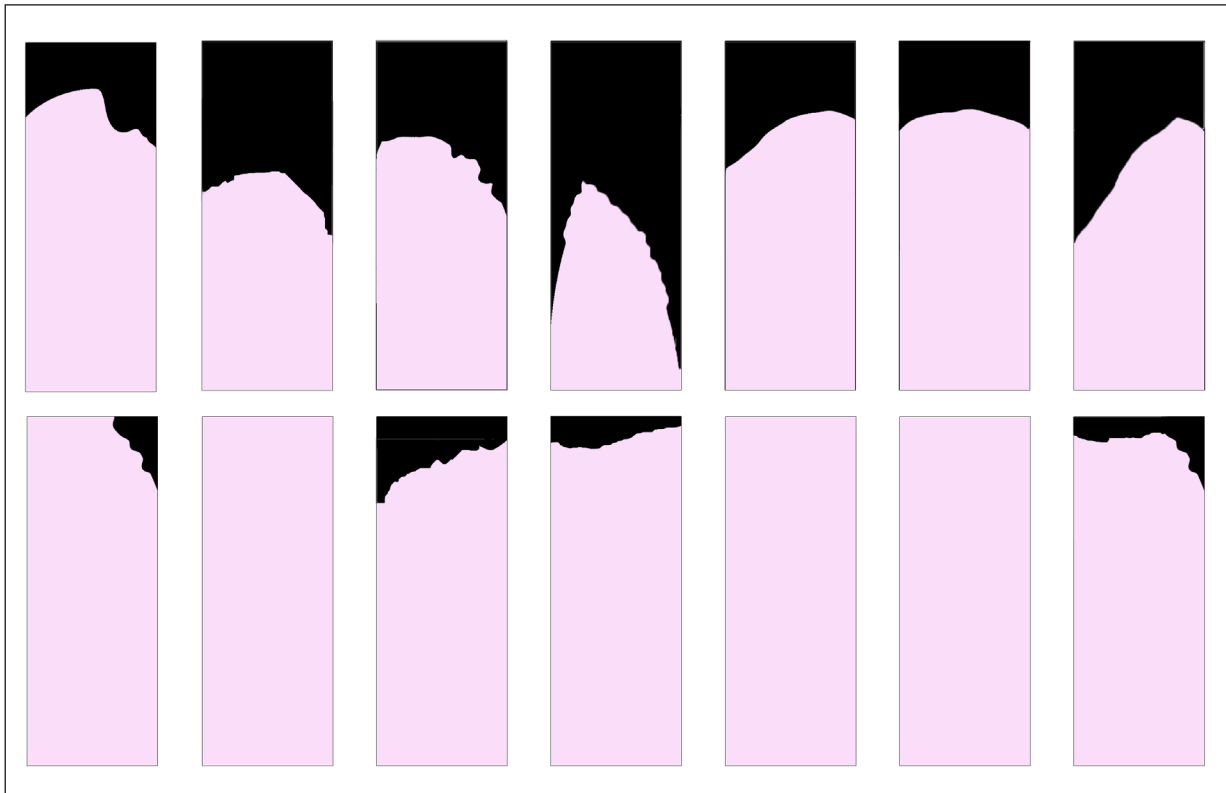


Figure 3. Necrosis areas of flaps. Upper row is the control group, and the lower row is the hyaluronidase group.

Corp., Armonk, NY, USA). The Mann-Whitney U test was used for analysis between the groups. A p -value <0.05 was considered statistically significant.

Results

No animal perished before the experiment had been completed. The area of necrosis in the animals of the intervention group was significantly lower than in the control animals, and this result reached a statistical significance of $p<0.001$. Table I details the necrosis area identified in each animal within the control and intervention groups. The areas are in mm^2 .

Median necrotic areas on skin flaps were 48.5 mm^2 in group 1 and 12.1 mm^2 in group 2. The difference between the flap necrosis values of the groups was statistically significant ($p<0.001$).

Discussion

The development of necrosis in a random skin flap, whether affecting the whole or part of the tissue, remains a vital issue in the performance of orthopedic surgery. Accordingly, multiple studies^{7,8} have been undertaken to ascertain how necrosis can be prevented or rendered less severe. Providing an adequate vascular supply

Table I. Necrosis areas of flaps.

	1	2	3	4	5	6	7	p -value
Control group	20%	42%	34%	56%	25.5%	21.5%	34%	$p<0.001$
Hyaluronidase group	4%	0	12.5%	5%	0	0	8.5%	

is essential to prevent this problem. Our study showed that hyaluronidase increased the survival of random skin flaps.

Hyaluronidase is frequently used to treat complications arising from aesthetic surgical interventions, e.g., when using a skin filler of hyaluronic acid. This agent supplies many clinical needs but has the disadvantage that it may result in anaphylaxis in an allergic individual. Consequently, provided that it is not being used in an emergency, such as vascular occlusion, it should only be used following allergy testing of the individual. The inner side of the patient's arm is used for subcutaneous injection of between 4 and 8 units of hyaluronidase. The patient is kept under observation for half an hour. If erythema, swelling, and pruritus are observed in the region where the injection occurred, this indicates the positivity of the test. The source from which the hyaluronidase was taken also plays a role. If the enzyme is of avian or bovine origin, the patient should be asked whether they are allergic to birds or cattle⁹⁻¹¹.

Furthermore, hyaluronidase is incompatible with other pharmacological agents, particularly furosemide, benzodiazepines, phenytoin, dopamine, and alpha-adrenergic agonists. Therefore, obtaining a comprehensive drug history from the patient before use is crucial. Several medications also interfere with the efficacy of hyaluronidase, e.g., the NSAIDs (ibuprofen, aspirin, and diclofenac), histamine blockers, agents which stabilize mast cells, ascorbic acid, flavonoids, and antioxidant vitamins⁹⁻¹¹.

Hyaluronidase is an enzyme that promotes mucolytic and renders hyaluronic acid less polarized. This latter molecule is essential in the ground substance within the dermis. The depolarizing effect of hyaluronidase helps permit substances to be more easily infiltrated into the cutaneous tissues. Moreover, hyaluronidase makes injection hurt less by making the tissues less taut. During surgery, hyaluronidase assists the surgeon since it renders the skin more elastic and aids in dispersing local anesthetics, which may be injected simultaneously. The literature contains accounts of how hyaluronidase has been utilized to assist in harvesting skin grafts. In the present study, however, the aim of using the enzyme was to boost the survival of the flap tissue⁹⁻¹¹.

The standard explanation for how hyaluronidase achieves this is by allowing fluid to flow more readily between the extracellular space of

the intact tissue and the flap, permitting waste metabolites to be transported away toward regions where the blood vessels are fully intact¹¹⁻¹³.

In addition, given the propensity of hyaluronidase to decrease the viscosity of certain fluids and assist with the recovery from trauma through various actions, it may be reasoned that hyaluronidase will also help preserve the vitality of random skin flaps. Our study confirms this, which indicates that hyaluronidase is associated with a lesser degree of necrotic tissue when applied to skin flaps in rats¹⁴.

Conclusions

The authors suggest that hyaluronidase may preserve tissue flap vitality, starting at the bottom end of the dosage range. Future research should establish the minimal concentration needed to obtain benefits. The optimal mode of administration, whether by injection or topical application, is also a topic for future studies.

Conflict of Interest

The Authors declare that they have no conflict of interests.

Ethics Approval

Ethical approval for the research, including surgical procedures, was granted by the Animal Ethics Committee at Eskisehir Osmangazi University (No. 188).

Informed Consent

Not applicable.

Funding

This study did not receive any fund.

Authors' Contributions

Mustafa Sungur: planning, designing, literature survey, interpretation of the results, active intellectual support. Cafer Yıldırım: planning, performing the study, active intellectual support. Cemal Cingi: planning, designing, writing, submission, literature survey, interpretation of the results, active intellectual support.

ORCID ID

Mustafa Sungur: 0000-0001-6504-7924
Cafer Yıldırım: 0000-0002-1565-9217
Cemal Cingi: 0000-0003-3934-5092

References

- 1) Ray AC, Philandrianos C, Bertrand B, Mélot A, Roche PH, Jaloux C, Casanova D. Two-stage free flap reconstruction of the scalp and calvaria for large neurosurgical resections. *Microsurgery* 2020; 40: 331-336.
- 2) Baker SR. Local cutaneous flaps. *Otolaryngol Clin North Am* 1994; 27: 139-159.
- 3) Weber SM, Baker SR. Management of cutaneous nasal defects. *Facial Plast Surg Clin North Am* 2009; 17: 395-417.
- 4) Chang KP, Lai C, Chang CH, Lin CL, Lai CS, Lin SD. Free flap options for reconstruction of complicated scalp and calvarial defects: report of a series of cases and literature review. *Microsurgery* 2010; 30: 13-18.
- 5) Shonka, DC Jr, Potash AE, Jameson MJ, Funk GF. Successful reconstruction of scalp and skull defects: lessons learned from a large series. *Laryngoscope* 2011; 121: 2305-2312.
- 6) António NN, Monte Alto Costa A, Marques RG. Viability of randomized skin flaps-an experimental study in rats. *J Surg Res* 2017; 207: 92-101.
- 7) Weber GC, Buhren BA, Schrupf H, Wohlrab J, Gerber PA. Clinical Applications of Hyaluronidase. *Adv Exp Med Biol* 2019; 1148: 255-277.
- 8) Grossman JA, McGonagle BA, Dowden RV, Diner MI. The effect of hyaluronidase and dimethyl sulfoxide (DMSO) on experimental skin flap survival. *Ann Plast Surg* 1983; 11: 223-226.
- 9) Bailey SH, Fagien, S, Rohrich RJ. Changing role of hyaluronidase in plastic surgery. *Plast Reconstr Surg* 2014; 133: 127-132.
- 10) Fronza M, Caetano GF, Leite MN, Bitencourt CS, Paula-Silva FW, Andrade TA, Frade MA, Merfort I, Faccioli LH. Hyaluronidase modulates inflammatory response and accelerates the cutaneous wound healing. *PloS One* 2014; 9: 1-12.
- 11) Syed SA, Tasaki Y, Fuji T, Hiano A, Kosbayashi K. A new experimental model: the vascular pedicle flap over the dorsal aspect (flank and hip) of the rat. *Br J Plast Surg* 1992; 45: 23-25.
- 12) Syed SA, Tasaki Y, Fujii T, Hirano A, Kobayashi K. A new experimental model: the vascular pedicle cutaneous flap over the dorsal aspect (flank and hip) of the rat. *Br J Plast Surg* 1992; 45: 23-25.
- 13) Ahmed S, Ahmed OA. Hyaluronidase revisited-a single injection technique for harvesting split thickness skin grafts under local anaesthesia. *Br J Plast Surg* 2004; 57: 589-591.
- 14) King M, Convery C, Davies E. This month's guideline: The Use of Hyaluronidase in Aesthetic Practice (v2.4). *J Clin Aesthet Dermatol* 2018; 11: 61-68.