

# Comparison of tympanometric volume measurement with temporal bone CT findings in the assessment of mastoid bone pneumatization in chronic otitis media patients

G. GÜLAY ASLAN<sup>1</sup>, O. YAGIZ AGHAYAROV<sup>1</sup>, Y. PEKÇEVİK<sup>2</sup>, I.B. ARSLAN<sup>1</sup>, İ. ÇUKUROVA<sup>1</sup>, A. ASLAN<sup>3</sup>

<sup>1</sup>Department of Otorhinolaryngology, Izmir Medical Faculty, Health Sciences University, Izmir, Turkey

<sup>2</sup>Department of Radiology, Izmir Medical Faculty, Health Sciences University, Izmir, Turkey

<sup>3</sup>Department of Otorhinolaryngology, Manisa Celal Bayar University, Manisa, Turkey

**Abstract. – OBJECTIVE:** Since mastoid bone aeration is a pressure buffer for the middle ear, it can be accepted as a prognostic factor for tympanoplasty. Temporal bone computed tomography (TBCT) is a primary method for estimating mastoid aeration. However, due to the risk of radiation and its high cost, there is a need for a more straightforward, faster, and more reliable method in non-complicated chronic otitis media cases (COM). Tympanometric volume measurement might be used for this purpose. This study investigated tympanometric volume measurement's reliability in showing mastoid bone aeration by comparing tympanometric volume measurement with TBCT aeration grading.

**PATIENTS AND METHODS:** Preoperative tympanometric volume measurements were performed in patients who underwent audiological examination and temporal computerized tomography (CT) with the diagnosis of COM and sequela of COM without discharge for the last three months and were indicated for surgery. CT was classified into six grades: grade 0: there is no aeration, sclerotic mastoid; grade 1: pneumatization only in the mastoid antrum; grade 2: <25% pneumatization; grade 3: 25-50% pneumatization; grade 4: >50% pneumatization, grade 5: full pneumatization. Averages of tympanometric volume values were determined according to CT degrees.

**RESULTS:** 48 left and 52 right ears (n: 100) of 81 patients, 24 females and 57 males, were included in the study. The mean age was 37.69±13.38. Mastoid pneumatization grades of patients were 32 grade 0, 23 grade 1, 16 grade 2, 14 grade 3, 11 grade 4, and 4 grade 5, respectively. Each grade's mean tympanometric volume (mL) was grade 0: 1.1594, grade 1: 1.6991, grade 2: 2.2250, grade 3: 3.0471, grade 4: 4.0327, and grade 5: 2.9775.

**CONCLUSIONS:** There is a statistically significant relationship between tympanometrically measured ear volume and mastoid degrees of pneumatization on temporal bone tomography.

As the degree of mastoid aeration increases, the tympanometric volume also increases. According to the results of this study, tympanometric air volume can be used reliably in the preoperative evaluation of mastoid bone aeration in cases of simple COM without ear drainage.

*Key Words:*

Chronic otitis media, Mastoid bone volume, Tympanometry, Temporal bone CT.

## Introduction

Under normal conditions, there is 0.5-0.6 mL of air in the middle ear, allowing the tympanic membrane (TM) and ossicular chain system to vibrate sufficiently during the transmission of sound. In addition, there may be 1 to 20 ml of air in the mastoid bone. The air in the mastoid bone acts as an air cushion for the middle ear when exposed to sudden pressure changes in the external environment<sup>1</sup>.

Chronic otitis media (COM) is an inflammatory process in the middle ear and mastoid, lasting longer than three months, characterized by perforation and hearing loss in the TM. There may be intermittent or continuous ear discharge and cases with no sequelae. The primary treatment method for COM is surgery. Good mastoid cells and middle ear aeration are prognostically essential indicators for tympanoplasty's postoperative anatomical and functional success, including cleaning pathological tissues in the middle ear and repairing TM perforation and/or ossicular chain reconstruction. Because the middle ear is more sensitive to pressure changes in patients with small mastoids, compensatory

buffering mechanisms such as TM retraction and fluid accumulation in the middle ear may develop, reducing the success of surgery<sup>2</sup>. For this reason, preoperative evaluation of mastoid aeration is essential, especially in cases of simple COM without discharge.

The standard radiological examination technique for temporal bone examination is temporal bone computed tomography (CT)<sup>3</sup>. CT provides detailed information about temporal bone aeration, the extent of the disease, anatomical variations, and possible complications. Exposure to radiation and high cost are the negative aspects of the method.

Tympanometry can measure the volume of the middle ear and the external auditory canal in ears with TM perforation. At the same time, the tuba eustachian is closed, and information about mastoid aditus patency and, thus, mastoid bone aeration can be obtained<sup>4-6</sup>. Tympanometry has the advantages of being less time-consuming, simple, and inexpensive compared to CT.

Our study investigated whether tympanometric volume measurement can be used reliably to measure mastoid bone aeration by comparing thin-section temporal bone CT, which is the gold standard in demonstrating ear aeration, with tympanometric volume measurement.

## Patients and Methods

The study was conducted prospectively following the Helsinki Declaration in a tertiary hospital after obtaining approval from the Celal Bayar University Faculty of Medicine Local Ethics Committee (Ref: 20478486-02). Patients who were scheduled for surgery with the diagnosis of COM and COM sequelae, did not report any discharge for the last three months and had at least 2 mm tympanic membrane perforation were included in the study with their consent. The external ear canal, middle ear, and mastoid air cell volumes were measured with preoperative tympanometry (Interacoustic AZ 26, Frequency 226 Hz probe tone, Mittelfart, Denmark). The term tympanometric volume is used to describe the mastoid air cells and the tympanic cavity (Epitympanium, hypotympanium mesotympanium, and protympanium). Thin section (0.6 mm) axial and coronal CT scans were performed on the same day with tympanometry.

In temporal bone tomography, mastoid bone aeration was evaluated according to six grades (Figure 1):

- Grade 0: Mastoid sclerotic, no aeration
- Grade 1: Aeration only in the mastoid antrum
- Grade 2: <25% lift
- Grade 3: 25-50% lift
- Grade 4: >50% lift
- Grade 5: Full lift

## Statistical Analysis

The mean tympanometric volume values for each grade were compared with each other. SPSS 20 program (IBM Corp., Armonk, NY, USA) was used for statistical analysis.

In this study, Shapiro-Wilk's test was used because of the number of units while investigating the normal distribution of the variables. While interpreting the results, 0.05 was used as the significance level. In the case of  $p < 0.05$ , it was stated that the variables did not come from the normal distribution, and in the case of  $p > 0.05$ , the variables came from the normal distribution.

Pearson's Chi-Square analysis was carried out while examining the relationships between groups of nominal variables.

The relationship between the groups was made using Pearson's Correlation analysis. For multiple comparisons of the differences between the groups, the Kurskall-Wallis test was used because the variables did not come from a normal distribution. Post Hoc Tamhane was applied for a detailed comparison of the groups. It was stated that there was a significant relationship in the case of  $p < 0.05$ , and there was no significant relationship in the case of  $p > 0.05$ .

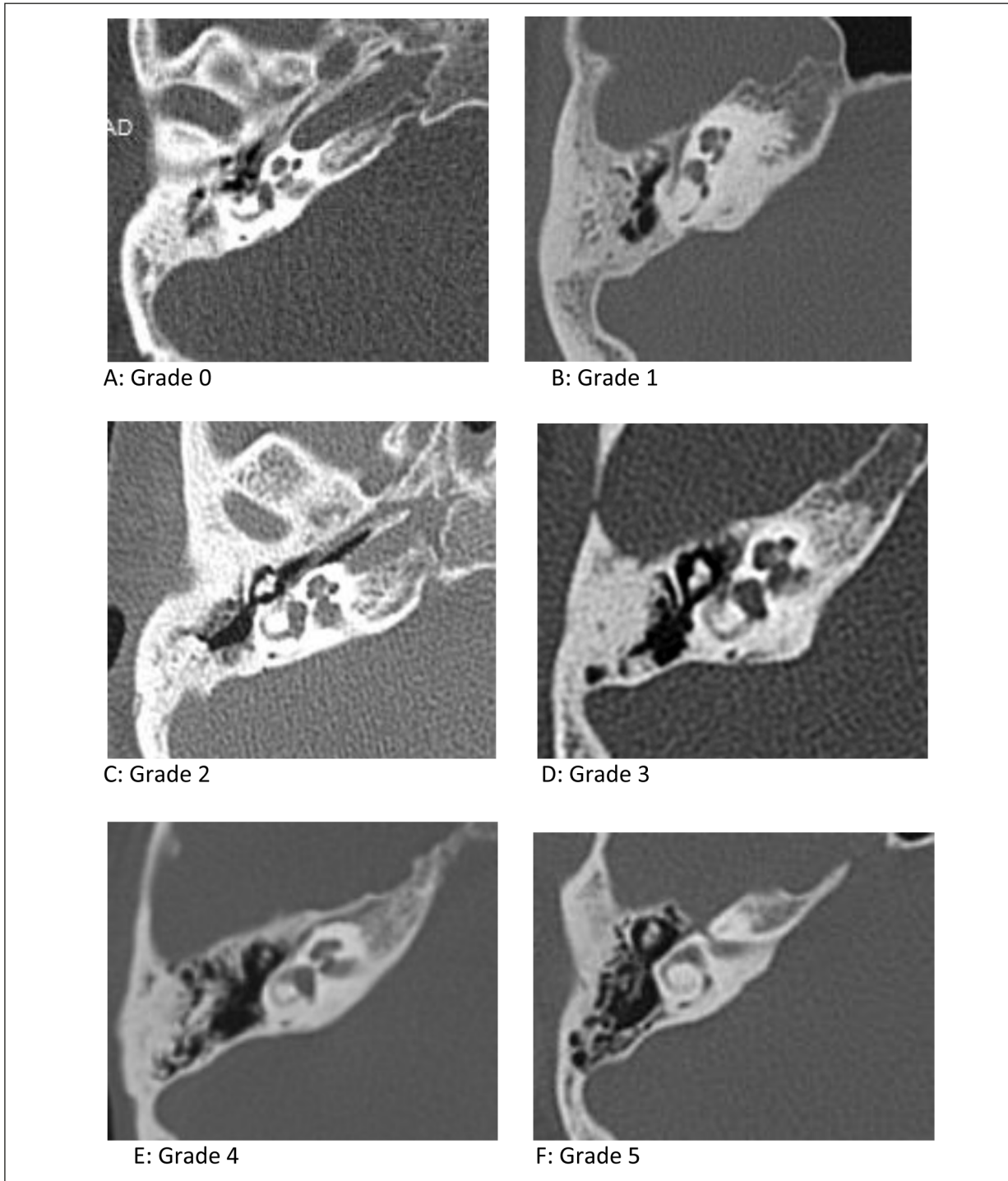
## Results

A total of 100 ears (52 right and 48 left ears) of 81 patients, 24 women and 57 men, diagnosed with COM and COM sequelae were included in the study. The mean age was calculated as  $37.69 \pm 13.38$  (12-68).

According to the grading of mastoid aeration by CT, 32 of the cases were grade 0, 23 were grade 1, 16 were grade 2, 14 were grade 3, 11 were grade 4, and 4 were grade 5.

Tympanometric volume values were 1.1594 mL for grade 0; 1.6991 mL for grade 1; 2.2250 mL for grade 2; 3.0471 mL for grade 3; 4.0327 mL for grade 4; while it was found to be 2.9775 mL for grade 5 (Table I).

A direct correlation was found between the degree of mastoid aeration and tympanometric volume measurement (Pearson's Correlation value



**Figure 1.** Mastoid aeration grade according to temporal CT. **A**, Grade 0: Mastoid sclerotic, no aeration. **B**, Grade 1: Aeration in mastoid antrum only. **C**, Grade 2: <25% aeration. **D**, Grade 3: 25-50% aeration. **E**, Grade 4: >50% aeration. **F**, Grade 5: Total aeration.

0.786,  $p=0.000$ ). When the tympanometric volume measurement and Cone-Beam Computed Tomography (CBCT) mastoid aeration degrees were examined, a statistically significant relationship was found, except for grade 5 ( $p<0.05$ ).

## Discussion

The primary treatment method for COM is surgery. Preoperative determination of the degree of mastoid aeration is prognostically essential in

**Table I.** Number of patients according to mastoid aeration degrees, tympanometric volume averages for each degree, and statistical analysis of each degree with tympanometric volume.

Mastoid Aeration Grade	Prevalence	Tympanometric Volume
Grade 0	32	1.1594 mL (0.56-2.07)
Grade 1	23	1.6991 mL (0.76-2.35)
Grade 2	16	2.2250 mL (0.95-3.23)
Grade 3	14	3.0471 mL (1.42-4.63)
Grade 4	11	4.0327 mL (2.93-6.00)
Grade 5	4	2.9775 mL (0.97-4.22)

estimating the surgery's postoperative anatomical and functional success<sup>7-9</sup>. The mastoid antrum's airiness is vital in providing adequate air support behind the graft placed in tympanoplasty and maintaining its position. In addition, it can be considered as an indicator of the low level of mucosal pathology that may limit the movement of the ossicular chain. The success of the graft and the possibility of gain in the hearing will be higher after tympanoplasty is applied in such patients. In addition, the preoperative determination of the airiness of the mastoid through the open mastoid antrum enables the prediction of possible postoperative retraction and effusion development<sup>2</sup>.

Suetake et al<sup>7</sup> measured the volume by postoperative tympanometry in 90 ears of 52 patients with otitis media with effusion (OME) to whom they applied ventilation tubes at the 1<sup>st</sup>, 3<sup>rd</sup>, and 6<sup>th</sup> months. Compliance values lower than 1.5 mL were found in 25% of the ears. In these patients, opacified, badly pneumatized temporal CT was encountered<sup>7</sup>. Görür et al<sup>8</sup> had preoperative temporal CT performed on 24 ears of 15 patients with a ventilation tube due to OME, and the volume was measured by tympanometry on the 1<sup>st</sup>, 7<sup>th</sup>, and 30<sup>th</sup> days. It was found that the postoperative tympanometric volume increased over time. It was observed that preoperative temporal bone CTs were sclerotic and occluded in 54% of the ears examined. There was no significant improvement in postoperative tympanometric volume measurements in these patients<sup>8</sup>. Merenda et al<sup>9</sup> measured preoperative tympanometric volume on 58 patients who had undergone pediatric tympanoplasty. When the success of tympanoplasty was evaluated, the rate was 80% if >3 mL and 34% if <3 mL<sup>9</sup>.

Today, axial and coronal temporal bone CT examination is the gold standard imaging method that provides detailed information and is the most commonly used preoperative middle ear and mastoid evaluation in patients with

COM<sup>3</sup>. On the other hand, tympanometry is a practical method that measures the volume in milliliters from the tip where the probe is placed<sup>4,5</sup>. Although it is commonly considered insufficient for measurement over 7 mL, it is a safe method since mastoid bone and cavity are underdeveloped in patients with COM.

Tympanometric volume measurement is a simple, fast, inexpensive, and non-invasive method and can be used as an alternative to preoperative radiological examination for this purpose. In this study, the degree of aeration of the mastoid bone was compared with both tympanometric volume measurement and temporal bone tomography grading, and it was investigated whether tympanometric volume measurement could be used reliably in demonstrating mastoid bone aeration.

Liu et al<sup>6</sup> found a correlation between the tympanometric volume and the aeration rates performed on temporal CT<sup>6</sup>. In their CT grading over 4 grades, they found tympanometric volume values to be >2 mL in high-grade cases (grades 3-4) and <2 mL in low-grade cases (grades 1-2).

When we evaluated the results of our study, it was determined that as the degree of mastoid aeration increased, the tympanometric volume measurement values increased except for grade 5. The volume values were low because there were only four patients with grade 5. The Pearson's Correlation value was 0.786, and the *p*-value was 0.00 in the correlation analysis between CB-CT mastoid aeration degree and tympanometric volume. This shows a proportional relationship between mastoid aeration degree and measurement of tympanometric volume.

In our study, the mean volume of patients with <25% mastoid aeration was 2.23 mL and complies with the criteria of "2 mL and above" reported by Liu et al<sup>6</sup>. Also, the value of <1.5 mL found<sup>6</sup> in 17 of 23 patients without mastoid and antrum aeration is consistent with the mean volume value of 1.16 mL, which we found as grade 0 (sclerosed mastoid) in our study.

## Conclusions

A statistically significant relationship exists between tympanometric volume measurement and mastoid aeration degrees. As the degree of mastoid aeration increases, the tympanometric volume value also increases. Tympanometric air measurement can be used reliably for the preoperative evaluation of mastoid bone aeration in simple COM without discharge. Tympanometric volume measurement is a simple, fast, inexpensive, and non-invasive method and can be used as an alternative or supportive to preoperative radiological examination for this purpose.

---

### Conflict of Interest

The authors declared no potential conflicts of interest concerning this article's research, authorship, and/or publication.

---

### Informed Consent

An informed consent form was obtained from all patients before being included in the study.

---

### Funding

This research did not receive any specific grant from any funding agency.

---

### Authors' Contributions

All authors equally contributed to the conceptualization, methodology, data collection, interpretation, writing the manuscript, and final review of the manuscript.

---

### Ethics Approval

Our study was approved by the Celal Bayar University Faculty of Medicine Local Ethics Committee (Ref: 20478486-02) and conducted according to the principles expressed in the Helsinki Declaration.

---

### ORCID ID

Gülay Güçlü Aslan: 0000-0002-0830-7440  
Ozlem Yagiz Aghayarov: 0000-0002-8455-4400  
Yeliz Pekçevik: 0000-0003-1421-3376  
İlker Burak Arslan: 0000-0001-6987-3887  
İbrahim Çukurova: 0000-0002-2398-3391  
Asım Aslan: 0000-0003-4081-233X

## References

- 1) Sadé J, Ar A. Middle ear and auditory tube: middle ear clearance, gas exchange, and pressure regulation. *Otolaryngol Head Neck Surg* 1997; 116: 499-524.
- 2) Cinamon U, Sadé J. Mastoid and tympanic membrane as pressure buffers: a quantitative study in a middle ear cleft model. *Otol Neurotol* 2003; 24: 839-842.
- 3) Shim HJ, Choi AY, Yoon SW, Kwon KH, Yeo SG. The Value of Measuring Eustachian Tube Aeration on Temporal Bone CT in Patients with Chronic Otitis Media. *Clin Exp Otorhinolaryngol* 2010; 3: 59-64.
- 4) Shanks JE, Lilly DJ. An evaluation of tympanometric estimates of ear canal volume. *J Speech Hear Res* 1981; 24: 557-566.
- 5) Lindeman P, Holmquist J. Measurement of middle ear volume using the impedance audiometer. *Am J Otol* 1981; 2: 301-303.
- 6) Liu CB, Shi YH, Li XY, Fan ZT. Prevalence and risk factors of otitis media with effusion in children with obstructive sleep apnea. *Eur Rev Med Pharmacol Sci* 2023; 27: 5445-5452.
- 7) Suetake M, Kobayashi T, Takasaka T, Shinkawa H. Is change in middle ear air volume following ventilation tube insertion a reliable prognostic indicator? *Acta Otolaryngol Suppl* 1990; 471: 73-80.
- 8) Görür K, Ozcan C, Talas DU. The computed tomographical and tympanometrical evaluation of mastoid pneumatization and attic blockage in patients with chronic otitis media with effusion. *Int J Pediatr Otorhinolaryngol* 2006; 70: 481-485.
- 9) Merenda D, Koike K, Shafiei M, Ramadan H. Tympanometric volume: a predictor of success of tympanoplasty in children. *Otolaryngol Head Neck Surg* 2007; 136: 189-192.