

Minimally invasive thyroidectomy and the differentiated lesions: the way to follow

A. ZULLINO, A. MAIUOLO, A. FUMAROLA*, P. GARGIULO*, V. MERCURI*, F.M. PACINI, M. RUGGIERI

Department of Surgery "Francesco Durante", Sapienza University, Rome (Italy)

*Department of Experimental Medicine, Sapienza University, Rome (Italy)

Abstract. – Background and Objectives: Nowadays, the conventional thyroidectomy may appear an overly aggressive treatment in patients undergoing intervention for small suspicious lesions harboring in low volume glands. In these cases a minimally invasive approach may be a safe and appropriate option. This work aims to evaluate the effectiveness of minimally invasive thyroidectomy in patients indicated to surgery for small lesions with preoperative suspicion of malignancy.

Patients and Methods: 71 patients, undergoing minimally invasive total thyroidectomy as a single procedure between May 2005 and April 2009, were enrolled in this study. They were indicated to surgery for small suspicious or malignant lesions (up to 20 mm length by US; cT1 according to UICC 2002) and satisfied the inclusion criteria of minimally invasive thyroidectomy, with gland volume up to 25 ml, no evidence of locally advanced disease and no previous neck surgery. The outcomes were considered in terms of complication rate, postoperative pain, hospitalisation stay, cosmetic results and completeness of surgical resection in malignancies.

Results: A low complication rate was registered. The surgical completeness, with mean serum thyroglobulin of 4.41 ± 4.03 ng/ml and radioiodine uptake of $2.91 \pm 2.46\%$, was considered acceptable if compared with other experiences reported in literature. Excellent results with respect to patient comfort, postoperative pain and cosmetic outcome were obtained.

Conclusion: This study confirms, where a correct selection of patients is made, the safety and the effectiveness of minimally invasive approach in the treatment of small suspicious and malignant nodules, which seem to represent its best indication.

Key Words:

MIVAT, Video-assisted thyroidectomy, Papillary thyroid carcinoma, Low-risk differentiated thyroid carcinoma, Minimally invasive thyroidectomy.

Introduction

Excluding the possibility of malignancy in thyroid nodules is often a complex medical act, and is the starting point for the correct management of these patients. Malignancy is suspected on the basis of echo-Doppler characteristics and fine needle aspiration cytology (FNAC) of the thyroid nodule. FNAC is considered the most sensitive and specific tool available to differentiate between benign and malignant thyroid diseases and its current place as the first step in diagnostic management certainly seems justified. Surgical treatment is undoubtedly indicated for patients with a malignant (Thy 5) and suspicious cytology (Thy 4) but also, according to current guidelines¹, for those with "indeterminate" cytology (Thy 3), including follicular neoplasms, Hurthle cell tumours and specimens showing atypical but not classic features of differentiated thyroid carcinoma (DTC). Only histological evaluation after surgery can differentiate these neoplasms. A high clinical risk score, resulting from the combination of ultrasound (US) thyroid parameters, clinical history and follow-up, could indicate the need for thyroid exeresis, even in the absence of specific cytological information²⁻⁶.

A conventional thyroidectomy may appear an overly aggressive treatment in patients presenting small lesions in low volume glands. In these cases a minimally invasive approach now seems a more suitable solution⁷⁻⁹.

All studies of the effectiveness of minimally invasive thyroidectomy in malignancies have demonstrated that its completeness is comparable to that obtained after conventional surgery¹⁰⁻¹⁵.

The aim of this work was to prospectively evaluate if minimally invasive thyroidectomy can be considered an appropriate option in patients

undergoing surgery for small suspicious or malignant lesions (up to 20 mm by US; cT1 according to UICC 2002). To this purpose we considered the following issues: surgical completeness (only for malignancies histologically confirmed), complication rate, postoperative pain, length of hospitalisation and cosmetic results.

Patients and Methods

Between May 2005 and April 2009, 71 patients with a thyroid nodule found suspicious or malignant on preoperative evaluation and with the largest diameter not exceeding 20 mm underwent minimally invasive total thyroidectomy in the “Francesco Durante” Department of Surgery, “Sapienza” University, Rome. The group consisted of 59 women and 12 men (mean age 46, range 19 to 75).

As common practice, patients have been requested to sign an informed consent to the collection of clinical and pathological data. The present study has been approved by the institutional Ethics Committee of Policlinico Umberto I Hospital, “Sapienza” University, Rome, Italy.

Patients underwent preoperative biochemical and hormonal assessment, laryngoscopy and neck ultrasound (US) with colour flow-Doppler (CFD) analysis. Thyroid volume, estimated using a mathematical formula^{16,17}, and nodule size, echo structure, margins, internal microcalcifications (MCs) and CFD (pattern 0, absence of flow signals; pattern I, vascular images in peripheral position; pattern II, intranodular flow with multiple vascular images; pattern III, peripheral and intra-nodular chaotic flow) were evaluated by an expert endocrinologist. All patients but five un-

derwent FNAC: of these five, one did not consent to the procedure, one was excluded due to anticoagulant oral treatment and three due to nodules considered too small to be aspirated. In the presence of multiple nodules, all those with a suspicious US appearance were aspirated.

All patients enrolled in this study satisfied the inclusion criteria of minimally invasive thyroid surgery, with gland volume up to 25 ml, no evidence of locally advanced disease and no previous neck surgery.

The indication for surgery was: cytological diagnosis of papillary carcinoma (PTC; Thy 5) in 8 patients, suspicion of PTC (Thy 4) in 15 patients, follicular proliferation (Thy 3) in 37 patients and a high clinical risk score in 11 patients (of whom 2 with benign cytology (Thy 2), 4 with “non-diagnostic” cytology (Thy 1) (repeated twice) and 5 who had not undergone FNAC (Table I). The clinical score took account of US thyroid characteristics on first referral, nodule growth and/or changes in echo structure, and family history of thyroid cancer or head/neck irradiation. The patient’s request to undergo surgery can also influence the decision making where some diagnostic doubt exists. Table II shows the US pattern of these 11 patients.

Our minimally invasive procedure can be briefly described as follows: a 25 mm high cervical skin incision is executed between the thyroid and the cricoid cartilages, the scar resulting mostly hidden by the curve of the neck and the shadow of the chin. This surgical access has the advantage of an easier and quicker dissection of the upper peduncles with optional use of 30-degree 5-mm endoscope and harmonic scalpels. After the identification of the recurrent laryngeal nerves and parathyroid glands, we perform a conventional total thyroidectomy. Fibrin glue

Table I. Admission diagnosis and final histology.

Admission diagnosis to intervention (71 pts)	Final histology (71 pts)
8 pts – FNAC resulting for PTC (Thy5)	All PTC
15 pts – FNAC resulting for suspicion of PTC (Thy4)	All PTC
37 pts – FNAC resulting for follicular proliferation (Thy3)	12 pts: PTC, 1 pt: follicular carcinoma, 3 pts: follicular adenoma, 21 pts: benign nodular disease
11 pts - High echo-doppler risk score	
• 6 pts – FNAC resulting for benign or “non diagnostic” (Thy1/Thy2)	7 pts: PTC,
• 5 pts – FNAC not performed	4 pts: benign nodular disease

pts: patients; FNAC: fine needle aspiration cytology; PTC: papillary thyroid carcinoma.

Table II. Patients selected for high clinical risk score.

Patients n.	Suspicious lesion echographic parameters					FNAC	Final histology
	Size (mm)	Structure	Margins	MCs	CFD (pattern)		
1	10	Hypo-echoic	Regular	Present	II	n. p.	PTC
2	12	Hypo-echoic	Regular	Present	III	Thy 1	PTC
3	12	Iso-echoic	Irregular	Present	III	Thy 2	Benign disease
4 ^a	12	Hypo-echoic	Irregular	No	III	Thy 1	PTC
5	14	Iso-echoic	Irregular	Present	III	Thy 1	PTC
6	15	Hypo-echoic	irregular	No	III	n. p.	Benign disease
7 ^b	16	Hypo-echoic	Irregular	Present	III	Thy 1	PTC
8	18	Hypo-echoic	Regular	Present	III	N. p.	Benign disease
9	12	Hypo-echoic	Regular	Present	III	n. p.	PTC
10	20	Hypo-echoic	Irregular	Present	II	Thy 2	PTC
11	14	Hypo-echoic	Irregular	No	III	n. p.	Benign disease

MCs: microcalcifications; CFD: colour flow-Doppler; PTC: papillary thyroid carcinoma; ^aPatient with geographic risk factor (he was from Ucraina); ^bPatient with history of familiar cancer; n.p.: not performed.

spray sealants are applied. The use of a small drainage tube is not obligatory; we often use it to check for early bleeding and remove it the following day, before patient discharge.

In postoperative care all patients took a progressively decreasing calcium and vitamin D supplement for two weeks to avoid any minor transient hypoparathyroidism caused by postoperative local oedema. Blood tests were performed on the first day and at the end of the first, second and third week after surgery.

We routinely administered NSAIDs by vein at patient's request until three times within the first postoperative 24 hours. All patients were asked to evaluate their postoperative pain 24 hours after surgery, on a Visual Analogue Scale (VAS) of 0 to 10, where 10 is the maximum conceivable pain.

The final diagnosis of thyroid carcinoma always necessitates an accurate evaluation of the surgical radicality achieved, in order to plan the subsequent radioiodine ablative treatment. For this purpose serum thyroglobulin (Tg) with thyroid-stimulating hormone (TSH) and anti-Tg antibodies (TgAb) dosage, radioiodine uptake diagnostic test and neck ultrasound (US) scan were evaluated after LT4 withdrawal six weeks post-surgery. Tg levels were measured by an immunoradiometric solid-phase assay with a functional sensitivity of 0.25 ng/mL and TgAb by an immunoenzymatic assay with a 5.0 UI/mL sensitivity; titres less than 20 UI/mL were considered nega-

tive. The uptake diagnostic test was conducted after 6 hours by the oral administration of up to 3.7 MBq I¹³¹. The neck US was performed by a skilled operator with a probe containing a linear transducer of 7.5 MHz.

Six months after surgery, all patients were asked to evaluate their own cosmetic result using a VAS of 0 to 10, where 10 is the best cosmetic result. In parallel, we have submitted the digital photographic record (taken 1 to 6 months after surgery) of all patients to a plastic surgeon's attention for the analysis of the surgical incision site. He expressed his judgement for each patient with a scar score (0-9, where 9 is the worst outcome) on the basis of three wound parameters: vascularity, pigmentation and height.

Results

Table I shows the final histology against diagnosis at admission in our series.

Of 71 patients, 43 (60.6%) had thyroid carcinoma, 42 PTC (30 classic variant, 11 follicular variant and 1 "tall cell" variant) and 1 follicular carcinoma. Postoperative T-definition (UICC 2002) was: 30 pT1, 6 pT1m, 1 pT2, 2 pT3 and 4 pT3m. The final histological diagnosis also demonstrated 25 cases (35.2%) of nodular hyperplasia and 3 (4.2%) of follicular adenoma.

Conversion to the traditional approach was not required in any case. In one patient we were forced to leave a small remnant due to tight adhesion of the gland capsule to the laryngeal nerve caused by thyroiditis.

Vocal cord mobility was checked in all patients by laryngoscopy after the procedure. We observed two cases of transient hoarseness, with normal vocal cord mobility, and one case of transient vocal cord palsy (resolving within 6 months). There was one case of cutaneous paraesthesia. No patient had postoperative haemorrhage or permanent hypoparathyroidism.

The mean operation time was 98 ± 9 minutes.

The mean follow-up period was 22 months (range 9-57).

In the 43 patients with a final histological diagnosis of carcinoma, surgical completeness was estimated as follows: mean postoperative serum thyroglobulin was 4.41 ± 4.03 ng/ml; radioiodine uptake diagnostic test revealed a mean uptake of $2.91 \pm 2.46\%$; postoperative ultrasound scan found a small thyroid remnant in two patients. These patients showed significantly higher values of Tg (24.10 and 16.40 ng/ml) and radioiodine uptake (14.20 and 8.60 %), indicating a quantity of residual tissue. In the first, at the beginning of our series, we had an unexpected remnant in the contralateral side of the tumour; in the second we consciously left a small remnant near the laryngeal nerve due to thyroiditis (Figure 1). A suitable radioiodine ablative treatment was successful in both cases. To date, no recurrence of disease has been recorded. At the time of evaluation, all patients were in hypothyroid condition with mean TSH 81.80 ± 23.95 μ UI/ml and posi-

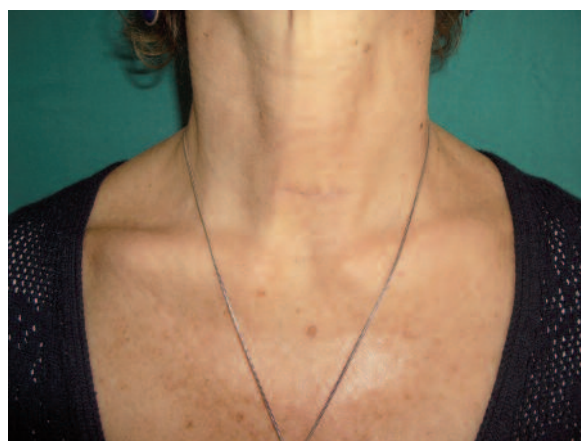


Figure 2.

tive TgAb titres, with low serum Tg (<2 ng/ml) in two cases.

Thyroid surgery is not yet authorized in our country as an outpatient procedure⁷. Our patients were discharged one or two days (at least 30 hours) after surgery.

We obtained excellent results with respect to patient cure rate and comfort, postoperative pain and cosmetic outcome. 51 patients did not need of postoperative analgesic treatment until their discharge, 17 patients requested a single administration and 3 asked us analgesic drugs twice. The mean pain score 24 hours after surgery was often negligible (< 1). The cosmetic result was considered excellent by most patients, with a mean score of 9.1 after 6 months, and acceptable by our plastic surgeon with a mean scar score of 1,7 (Figures 2 and 3).

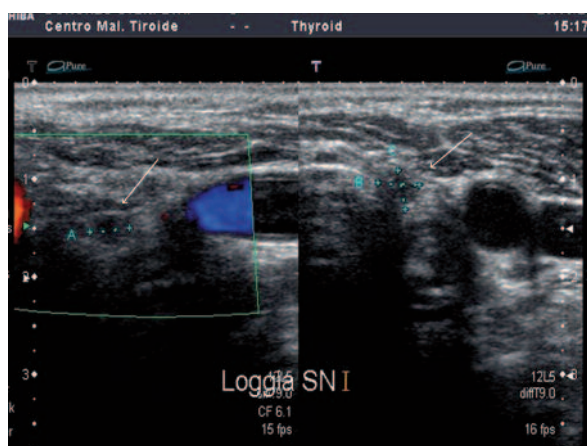


Figure 1.

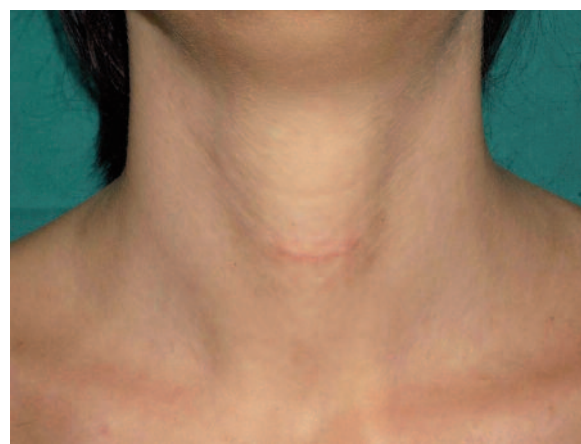

Figure 3.

Discussion

Differentiated thyroid carcinomas (DTCs) are the most common type of thyroid malignancy and, if discovered early and properly treated, have an excellent long-term prognosis with respect to both overall and recurrence-free survival. This is especially true for low-risk DTCs which, being small and confined to the gland, can also be treated with a minimally invasive procedure, which is less aggressive than a conventional operation and consequently more appreciated by the patient.

In the clinical practice it is not always possible to make diagnosis of thyroid cancer; malignancy is generally suspected preoperatively, on the basis of the US characteristics and the cytological class of the lesion.

Thy 5 is diagnostic and Thy 4 is strongly predictive of malignancy. They both necessarily require surgical intervention: in our series they always identified a thyroid carcinoma. Thy 3 is an uncertain class, labelled as “indeterminate” because its cytological characteristics are poorly defined for distinguishing benign from malignant lesions. Less than half of Thy 3 lesions (13 of 37 patients, approximately the 35%) were found to be malignant at the final histological examination, which alone can identify the real nature of these neoplasms.

In patients with benign (Thy 2) and repeatedly non-diagnostic FNAC (Thy 1), the combination of echo-Doppler data and clinical risk factors can lead to the suspicion of thyroid cancer, indicating surgery. Our series included 11 patients with a high clinical risk score; of these, five did not undergo FNAC and six had benign and non-diagnostic preoperative cytology (two and four respectively). The final histological results revealed PTC in 7 of these cases.

All patients enrolled in this study were preoperatively considered at risk of malignancy and were selected for minimally invasive thyroidectomy observing the following inclusion criteria: primary lesion size up to 20 mm by US, no apparent invasion of the thyroid capsule and no evidence of cervical lymph node involvement. These three conditions together define the lowest clinical stage. Our cut-off is justified by the close correlation between tumour size and extrathyroidal growth with lymph node spread^{18,19}. If lymph node involvement is suspected we still prefer the effectiveness of conventional surgery, though central compartment lymph node dissection is technically feasible with minimally invasive video-assisted thyroidectomy (MIVAT)²⁰.

The surgical extension of thyroidectomy (lobectomy and isthmectomy or total exeresis) depends on several factors, as the admission diagnosis (malignancy demonstrated or suspected, benign disease), clinical characteristics (hypothyroidism, history of irradiation, multiple thyroid nodules) and each patient’s specific request¹. Total thyroidectomy as a single procedure was our treatment of choice, as all cases were considered as potentially malignant. This is the safest surgical treatment to prevent local recurrences, avoiding the risk of additional surgery, which is both psychologically stressful and dangerous for the patient. Conservative surgery is inadequate in patients with a final histology of DTC, due to the frequent occurrence of multifocality and the need for a precise follow-up with thyroglobulin and radioactive iodine scanning.

Interesting many young women, minimally invasive thyroid surgery was born to research a better cosmetic. A small skin incision performed high up between the thyroid and cricoid cartilages and concealed in a neck wrinkle always gave good results which are more acceptable than a traditional incision, especially for young women. Moreover, patients reported less postoperative pain and little need for analgesics in the first 24 hours after surgery. As a consequence of the generally reduced dissection of the cervical tissues, we observed a reduction in the rate of cutaneous paraesthesia (one case) and better haemostasis. The shorter hospitalisation and the patient’s ability to return to work earlier are an important factor when considering the social costs.

Finally, quantification of the postoperative thyroid remnant by ¹³¹I diagnostic uptake and serum TG measurements demonstrated an acceptable surgical completeness, demonstrating that minimally invasive procedures can be safely applied to patients with low-risk DTC.

This study confirms that in carefully selected patients, small nodules with suspicious or malignant cytology now represent an appropriate indication for a minimally invasive approach. Larger patient series and longer follow-up are still necessary to affirm the oncological validity of these surgical procedures.

Acknowledgements

We are very grateful to Massimo Vergine M.D. (Department of “Surgical Sciences”, General and Reconstructive Surgery, Sapienza University, Rome) for his opinion in evaluating our patient’s cosmesis.

References

- 1) COOPER DS, DOHERTY GM, HAUGEN BR, KLOOS RT, LEE SL, MANDEL SJ, MAZZAFERRI EL, MCIVER B, SHERMAN SI, TUTTLE RM. Management guidelines for patients with thyroid nodules and differentiated thyroid cancer. The American Thyroid Association Guidelines Taskforce. *Thyroid* 2006; 16: 109-142.
- 2) CAPPELLI C, CASTELLANO M, PIROLA I, CUMETTI D, AGOSTI B, GANDOSSI E, AGABITI ROSEI E. The predictive value of ultrasound findings in the management of thyroid nodules. *Q J Med* 2007; 100: 29-35.
- 3) APPETECCHIA M, SOLIVETTI FM. The association of colour flow Doppler sonography and conventional ultrasonography improves the diagnosis of thyroid carcinoma. *Horm Res* 2006; 66: 249-256.
- 4) RAGO T, DI COSCIO G, BASOLO F, SCUTARI M, ELISEI R, BERTI P, MICCOLI P, ROMANI R, FAVIANA P, PINCHERA A, VITTI P. Combined clinical, thyroid ultrasound and cytological features help to predict thyroid malignancy in follicular and Hürthle cell thyroid lesions: results from a series of 505 consecutive patients. *Clin Endocrinol (Oxf)* 2007; 66: 13-20.
- 5) KURU B, GULCELIK NE, GULCELIK MA, DINCER H. Predictive index for carcinoma of thyroid nodules and its integration with fine-needle aspiration cytology. *Head Neck* 2009; 31: 856-866.
- 6) KOIKE E, NOGUCHI S, YAMASHITA H, MURAKAMI T, OHSHIMA A, KAWAMOTO H, YAMASHITA H. Ultrasonographic characteristics of thyroid nodules: prediction of malignancy. *Arch Surg* 2001; 136: 334-337.
- 7) MICCOLI P, BERTI P, AMBROSINI CE. Perspectives and lessons learned after a decade of minimally invasive video-assisted thyroidectomy. *ORL* 2008; 70: 282-286.
- 8) MICCOLI P, PINCHERA A, MATERAZZI G, BIAGINI A, BERTI P, FAVIANA P, MOLINARO E, VIOLA D, ELISEI R. Surgical treatment of low- and intermediate-risk papillary thyroid cancer with minimally invasive video-assisted thyroidectomy. *J Clin Endocrinol Metab* 2009; 94: 1618-1622.
- 9) MICCOLI P, MATERAZZI G, BERTI P. Minimally invasive thyroidectomy in the treatment of well differentiated thyroid cancers: indications and limits. *Curr Opin Otolaryngol Head Neck Surg* 2010; 18: 114-118.
- 10) MICCOLI P, ELISEI R, MATERAZZI G, CAPEZZONE M, GALLERI D, PACINI F, BERTI P, PINCHERA A. Minimally invasive video-assisted thyroidectomy for papillary carcinoma: A prospective study of its completeness. *Surgery* 2002; 132: 1070-1074.
- 11) LOMBARDI CP, RAFFAELLI M, DE CREA C, PRINCI P, CASTALDI P, SPAVENTA A, SALVATORI M, BELLANTONE R. Report on 8 years of experience with video-assisted thyroidectomy for papillary thyroid carcinoma. *Surgery* 2007; 142: 944-951.
- 12) CHUNG YS, CHOE JH, KANG KH, KIM SW, CHUNG KW, PARK KS, HAN W, NOH DY, OH SK, YOUNG YK. Endoscopic thyroidectomy for thyroid malignancies: comparison with conventional open thyroidectomy. *World J Surg* 2007; 31: 2302-2306.
- 13) BAE JS, PARK WC, SONG BJ, JUNG SS, KIM JS. Endoscopic thyroidectomy and sentinel lymph node biopsy via an anterior chest approach for papillary thyroid cancer. *Surg Today* 2009; 39: 178-181.
- 14) RUGGIERI M, ZULLINO A, STRANIERO A, MAIUOLO A, FUMAROLA A, VIETRI F, D'ARMIENTO M. Is minimally invasive surgery appropriate for small differentiated thyroid carcinomas? *Surg Today* 2010; 40: 418-422.
- 15) SALVATORI M, RAFFAELLI M, CASTALDI P, TREGLIA G, RUFFINI V, PEROTTI G, LOMBARDI CP, RUBELLO D, ARDITO G, BELLANTONE R. Evaluation of the surgical completeness after total thyroidectomy for differentiated thyroid carcinoma. *Eur J Surg Oncol* 2007; 33: 648-654.
- 16) RUGGIERI M, FUMAROLA A, STRANIERO A, MAIUOLO A, COLETTA I, VELTRI A, DI FIORE A, TRIMBOLI P, GARGIULO P, GENDERINI M, D'ARMIENTO M. The estimation of the thyroid volume before surgery-an important prerequisite for minimally invasive thyroidectomy. *Langenbecks Arch Surg* 2008; 393: 721-724.
- 17) TRIMBOLI P, RUGGIERI M, FUMAROLA A, D'ALÒ M, STRANIERO A, MAIUOLO A, ULISSE S, D'ARMIENTO M. A mathematical formula to estimate in vivo thyroid volume from two-dimensional ultrasonography. *Thyroid* 2008; 18: 879-882.
- 18) MACHENS A, HOLZHAUSEN HJ, DRALLE H. The prognostic value of primary tumor size in papillary and follicular thyroid carcinoma. *Cancer* 2005; 103: 2269-2273.
- 19) VERBURG FA, MÄDER U, LUSTER M, REINERS C. Primary tumor diameter as a risk factor for advanced disease features of differentiated thyroid carcinoma. *Clin Endocrinol (Oxf)* 2009; 71: 291-297.
- 20) MICCOLI P, ELISEI R, DONATINI G, MATERAZZI G, BERTI P. Video-assisted central compartment lymphadenectomy in a patient with a positive RET oncogene: initial experience. *Surg Endosc* 2007; 21: 120-123.